

Speech and Swallow Kinematics of a Person with Congenital Aglossia

Betty L McMicken¹, Shelley Von Berg^{2*}, Long Wang³, Andrew Kunihiro³, Margaret Vento-Wilson⁴ and Kelly Rogers⁵

¹Department of Communication Disorders, California State University, Long Beach, USA

²Department of Communication Sciences and Disorders, California State University, Chico, USA

³Department of Family and Consumer Sciences, California State University, Long Beach, USA

⁴Department of Communication Disorders, Cypress School District, USA

⁵Department of Communication Disorders, Saddleback College, USA

*Corresponding author: Shelley Von Berg, Department of Communication Sciences and Disorders, California State University, Chico, USA, Tel: +5308984517; E-mail: svonberg@csuchico.edu

Rec date: Feb 23, 2015, Acc date: Apr 01, 2015, Pub date: Apr 03, 2015

Copyright: © 2015 McMicken BL, et al. This is an open-access article distributed under the terms of the Creative Commons Attribution License, which permits unrestricted use, distribution, and reproduction in any medium, provided the original author and source are credited.

Abstract

Objective: This research study explored movement of key processes during speech and swallow of a person with congenital aglossia. It expands upon earlier studies that found a high degree of intelligibility among listeners for expressive speech by the person with congenital aglossia and seeks to identify the dynamics through which the articulators accomplish this phenomenon.

Methods: Positional movements of the mandible and hyoid bone and mylohyoid and tongue base for speech and swallow were compared with those movements obtained for people without aglossia.

Results: In this subject, the hyoid bone and mandible were strongly associated with movement of the pseudo tongue for both speech and swallow. This is markedly different from results of normal subjects, who show strong correlations between the hyoid bone and mandible and the tongue for swallow only. Kinematics differed significantly for speech and swallow tasks in the person with PwCA, with the exception of the hyoid bone, which behaved in a similar manner for both tasks. Movements of pseudo-tongue structures demonstrated a variety of horizontal and vertical movements, with some independent relationships between mandibular and hyoid bone motions for both oral swallow and speech. Overall, the dependent variables of mylohyoid and the base of tongue were closely related to the movement of the hyoid bone, which was the strongest determinant of vertical dependent variable movement. Results revealed that in this person with congenital aglossia, the hyoid bone and mandible were strongly associated with movement of the pseudo tongue for both speech and swallow. This is markedly different from results of normal subjects, who show strong correlations between the hyoid bone and mandible and the tongue for swallow only.

Conclusion: These results suggest that speakers who present with congenital or acquired structural and/or physiological reductions to the speech mechanism may present with the capacity to capitalize on a variety of actions during eating or swallowing to optimize the more finessed actions of speech. The highly predictable correlations of muscles for deglutition and speech suggest that this speaker essentially 'bootstrapped' muscular actions (and limitations therein) developed for deglutition and used them to buttress speech and resonance. These actions are quite different from those of individuals with a tongue, who recruit a variety of muscles for the diverse acts of speaking and swallowing.

Keywords: Congenital aglossia; Speech; Swallow; Mylohyoid; Base of tongue; Hyoid bone; Mandible

Introduction

Congenital aglossia (CA) is a rare syndrome in which an individual is born without a tongue. CA was first comprehensively reported by de Jussieu [1]. Since then, 11 reports of isolated CA, without the presence of other syndromes or symptoms, have appeared in the literature.

This descriptive case study is based on cineradiographic films (CRFs) and audio-video recordings (AVs) collected in 1986 of a 16 year old female with congenital aglossia. Previous reports described perceptual examination of vowel and consonant production [2,3] followed by a two dimensional CRF investigation of articulatory movement of bony variables mandible and hyoid bone and the visible

muscular variables of pseudo-tongue structures (base of tongue and mylohyoid) during production of four phrases [4]. These finding suggested that the hyoid bone appeared to act independently in vertical motion and was strongly active with vertical pseudo-tongue movement during phrase production. The extent of hyoid activity was a unique finding both in the person with congenital aglossia (PwCA) and normal articulatory literature.

In subjects without congenital aglossia (PwoCA) with normal oral mechanisms, the relationship between the structural movements involving the articulators of the tongue, mandible, and hyoid bone have been investigated for both eating and speech tasks [5,6]. Recent studies using 2-dimensional video imagery, radio-opaque markers and Cartesian coordinates for measurement were the focus for review Hiiemae et al. [5] reported that during reading of the Grandfather Passage, the movement of the hyoid bone was observed to be irregular

and not linked to mandible movement. An additional finding was that the range of articulatory movement of the hyoid bone in normal subjects was narrow; and the hyoid bone moved continuously during both speech and eating. In speech, hyoid motions were irregular and not linked to jaw movement, as they were for eating.

Hiiemae et al. [5] further investigated tongue movements in normal subjects for eating and speech and suggested that the position of the tongue in relation to the mandible and maxilla was regulated partly by the position of the hyoid bone, with additional contribution from the suprahyoid muscles, ... "controlling the angulation and length of the floor of the mouth on which the tongue body 'rides'..." The authors went on to suggest that the configurations of the tongue were similar for speaking and eating tasks. It was suggested that the various configurations of the tongue in eating may be the medium for both speech and eating.

Matsuo and Palmer [6] reported on the kinematic linkage of anterior and posterior (A and P) aspects of the tongue in relation to the mandible and hyoid bone during speech and eating. The authors tracked both anterior and posterior aspects of the tongue and found that each aspect was influenced differently by movements of the mandible and hyoid in both the vertical and horizontal planes. Regression analysis demonstrated a nearly zero value for the hyoid contribution to both A and P tongue movements for speech tasks, suggesting a high degree of independence from the hyoid movement. For eating tasks, the same authors reported that tongue movement was strongly influenced by hyoid movement for the horizontal dimension, but was more independent from jaw movement. Finally, the tongue and hyoid bone were observed to move horizontally with large amplitude. Vertical movement of the anterior part of the tongue was determined by vertical jaw movement for eating, while the posterior part of the tongue was more influenced by vertical hyoid movement. The authors suggested that future research models should consider the potential significant impact of both mandibular and hyoid bone excursion on anterior and posterior tongue surface motion.

Investigations of the kinematics of speech and swallow for PwCA using CRF and video fluoroscopy studies are rare [7,8]. A thorough investigation of the literature revealed that the data gathered by the primary investigator (PI) from the 1986 CRFs were the third to be reported of a PwCA. The former reports were descriptive reports of the CRF studies of a PwCA first at 3 months, then 10 months, and finally 8-years-of-age. According to the authors, overlapping and erupting teeth obscured any outline of soft tissue of the tongue base and floor of the mouth. This issue with lack of clarity is readily apparent in the x-ray frames displayed in the earlier papers. The CRFs from these studies with a single patient describe specific anatomical compensations, such as ... "raising of the floor of the mouth toward the hard palate and raising of the posterior tongue to the soft palate" during barium swallow [7]. There was also mention of hypertrophy of the floor of the mouth. There is a consensus among the authors in congenital aglossia literature that the mylohyoid and tongue base act as pseudo tongue in most PWCAs; however, a thorough review of the above referenced literature revealed no attempt to scientifically document the anatomic structural relationships and physiologic kinematic associations that occur during speech and swallow for PwCA.

The purpose of the current investigation was to examine the positional movement of the bony variables mandible and hyoid and muscular variables of mylohyoid and tongue base during speech and oral stage saliva swallow and to determine if these patterns were

similar to those described in normal literature. The relationship of the muscular and bony variables was explored using descriptive statistics, correlation, and linear regressive analysis during both contextual speech and saliva swallow. The authors hypothesized that muscular variables would influence bony variables; therefore the independent variables (IVs) were noted as tongue base and mylohyoid; and the dependent variables (DVs) as hyoid bone and mandible.

Case Study Questions

The following questions were addressed through implementation of correlation analysis and stepwise linear regressive analysis.

Question 1: Is the movement of the pseudo-tongue tongue surface (tongue base and mylohyoid) correlated with the movements of the mandible and hyoid bone during saliva swallow and contextual speech?

Question 2: What are the relative influences of the mylohyoid and tongue base positions in determining the positions of the mandible and hyoid bone during speech and swallow?

Case Presentation

Subject

In 1986, a 16-year-old-female PWCA presenting with severe retrognathia was referred to a head and neck center for a speech and craniofacial assessment for evaluation of possible mandibular advancement.

The client's mother, in the presence of the PI, signed release of information forms, including acknowledgment that the AV and CRF samples might be used for future research and educational purposes. The PWCA's intraoral cavity was inspected by numerous team members of the hospital-based head and neck center. Their examination revealed a wart-like tongue rudiment in the region of the floor of the mouth [9]. The interpreting radiologist reported that there was no geniohyoid muscle visible on X-ray or present on palpation. He also suggested that the absence of the tongue was compensated for by elevation of the hypertrophied mylohyoid (floor of the mouth) and hypertrophied tongue base, in what appeared to be separate but similar manners, as a means of constriction with the mid-anterior palate, posterior palate, velum and pharynx. The PwCA was reported to have a remarkably strong mylohyoid-to-palate constriction as tested by sucking on the examiner's gloved finger. She was also able to suck on the finger and swallow several times consecutively. This muscle-mass-to-mid-palate contact, which allowed the speaker to develop swallowing functions, has also been reported in other case studies [7,8,10,11] Speech was intelligible and swallow function were observed to be functional at the time of initial assessment, given food of soft and chopped consistency [9]. No additional observations of the bone and muscle structures involved in the anatomy and physiology of speech, swallowing and chewing were made at the time of initial data collection.

Materials, Methodology and Data Collection

The original 1986 CRFs were obtained using Kodak XX 35 mm cine film with General Electric TVX cineradiographic equipment. The cine film was processed by scanning the original 35 mm black and white X-ray film to a 2K log DPX files, which was then converted into a tiff sequence. Contextual speech contained 154 frames, consisting of four

phrase repetitions (Take time to talk; Did Doug drive down; Cut the cake; Go get Gary). Saliva swallows comprised 30 frames. The PI and a computer animation engineer generated frame-by-frame individual mapping of the movement of (a) a medial point of the mylohyoid, (b) the highest point of the medial tongue base, (c) the anterior-inferior point of the mandible, and (d) the anterior-superior point of the hyoid bone.

Cartesian coordinates (XY) were established by passing a line through the upper canine tooth and first molar markers (horizontal), and a line perpendicular to the upper occlusal plane at the upper canine [6]. The XY relative coordinate dimensions were developed using pixel conversion to centimeters with the mean selected from 100 random frame samples, of medial height and width of C4 (fused vertebra, 1.25 × 1.40 cm) as a conversion measurement. The individual frames of contextual speech and saliva swallow were analyzed to gather vertical and horizontal data points for the mylohyoid, tongue base, mandible, and hyoid.

Reliability of the data point locations was judged by the PI, an expert in the anatomy and physiology of the speech mechanism, and a computer animation engineer with five years' supervised experience in the anatomy tracing of sagittal X-ray frames. Twenty-five frames of contextual speech were analyzed, for a total of 100 frames. The data coordinates were subjected to reliability analysis. The Pearson correlation between judges was .974, which indicates an excellent variable point selection consistency.

The movement tracking of the dependent and independent variables was accomplished using the Adobe After Effects program. The positions of displacement of the mylohyoid, tongue base, mandible, and hyoid were expressed as X (horizontal) and Y (vertical) coordinates.

Data collection and Analyses

Independent muscular variables (IVs) were defined as the positions of the mylohyoid and tongue base, and the dependent bony variables (DVs) were defined as the positions of the mandible and the hyoid bone. Points of maximum excursion for each of the articulatory variables during contextual speech and saliva swallow were documented. These data points were calculated for range of movement, correlation, and regression analysis. Correlation coefficients (r) and standardized partial regression coefficients (β) were calculated.

Results

Table 1 suggests no clear patterns for hierarchy of range of movement with respect to the bony variables of the mandible and the hyoid bone or with the muscular variables of the tongue base and the mylohyoid for the saliva swallow and connected speech.

Range of motion

Range of movement for all variables for saliva swallow in the vertical axis were tongue base (1.2867) > mylohyoid (0.8390) > hyoid bone (0.8175) > mandible (0.2211). Range of movement for all variables in the contextual speech vertical axis were mandible (-0.2758) > hyoid bone (0.1121) > tongue base (0.0636) > mylohyoid (-0.0023). Range of movement for all variables in contextual speech in the horizontal axis were tongue base (0.1453) > hyoid bone (0.0696) > mandible (0.0431) > mylohyoid (0.0083). Range of movement for all variables for the saliva swallow in the horizontal axis were tongue base (-0.2179) > mandible (-0.1406) > hyoid bone (-0.1240) > mylohyoid (0.1113).

	Saliva Swallow (n=30)		Connected Speech (n=135)	
	Mean Range	Standard Deviation	Mean Range	Standard Deviation
X-Axis Horizontal				
Mandible	-0.1406	0.0518	0.0431	0.2903
Hyoid	-0.1240	0.1008	0.0696	0.2115
Mylohyoid	0.1113	0.0936	0.0083	0.1740
Tongue base	-0.2179	0.3266	0.1453	0.3458
Y-Axis vertical				
Mandible	0.2211	0.0843	-0.2758	0.3186
Hyoid	0.8175	0.7985	0.1121	0.8191
Mylohyoid	0.8390	0.7179	-0.0023	0.9472
Tongue base	1.2867	1.1212	0.0636	0.8930

Table 1: ROM for variables of interest. Mean range of movement and standard deviation of bony variables and muscular variables during saliva swallow and contextual speech in a person with congenital aglossia.

Correlations

Table 2 reveals that on the horizontal plane there was a moderately strong correlation for positions of the tongue base and the mandible for saliva swallows and for positions of the tongue base and the hyoid bone for contextual speech. Vertically, there were extremely strong

correlations for both speech and saliva swallow involving the tongue base and hyoid bone and mylohyoid and hyoid bone. Moderately strong correlations were noted for both speech and saliva swallow involving the tongue base and the mandible and the mylohyoid and the mandible (Figure 1).

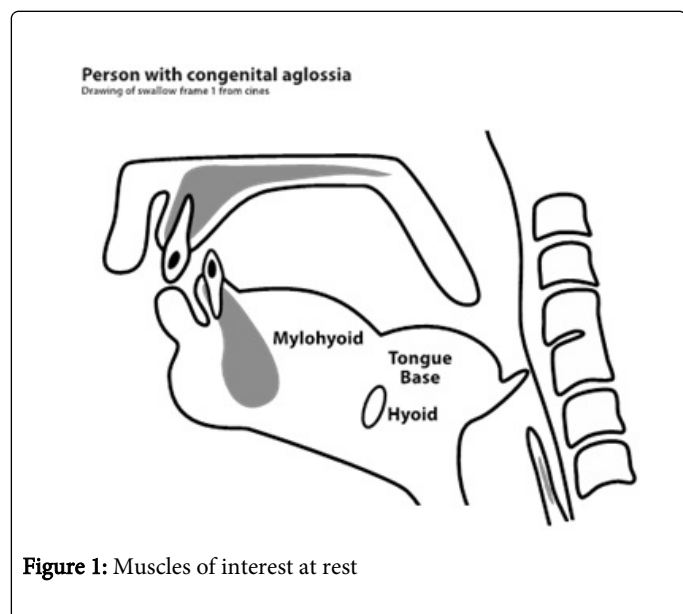
X	Mandible		Hyoid	
	Contextual Speech	Saliva Swallow	Contextual Speech	Saliva Swallow
Mylohyoid	.400*	-.124	.214	-.007
Tongue base	.397*	.518**	.629**	-.163
Y				
Mylohyoid	.542**	.674**	.926**	.987**
Tongue base	.459**	.676**	.906**	.984**

** . Correlation is significant at the 0.01 level (2-tailed).

*. Correlation is significant at the 0.05 level (2-tailed).

Table 2: Horizontal (X axis) and Vertical (Y axis) Movement.Pearson Correlations of muscular (IV) and bony (DV) variables during contextual speech (CS) and saliva swallow (SS) in a person with congenital aglossia.

Table 2 reveals that on the horizontal plane there was a moderately strong correlation for positions of the tongue base and the mandible for saliva swallows and for positions of the tongue base and the hyoid bone for contextual speech. Vertically, there were extremely strong correlations for both speech and saliva swallow involving the tongue base and hyoid bone and mylohyoid and hyoid bone. Moderately strong correlations were noted for both speech and saliva swallow involving the tongue base and the mandible and the mylohyoid and the mandible (Figure 1).



Regression Analysis

Tables 3 and 4 reveal results of a general linear stepwise regression model that designated the base of tongue and the mylohyoid as muscular independent variables and the hyoid bone and the mandible as bony dependent variables. For saliva swallow on the horizontal plane there were no significant contributions from the mylohyoid or base of tongue to the hyoid bone's horizontal movement. However, there was strong co-linearity for these muscles and the horizontal movement of the mandible.

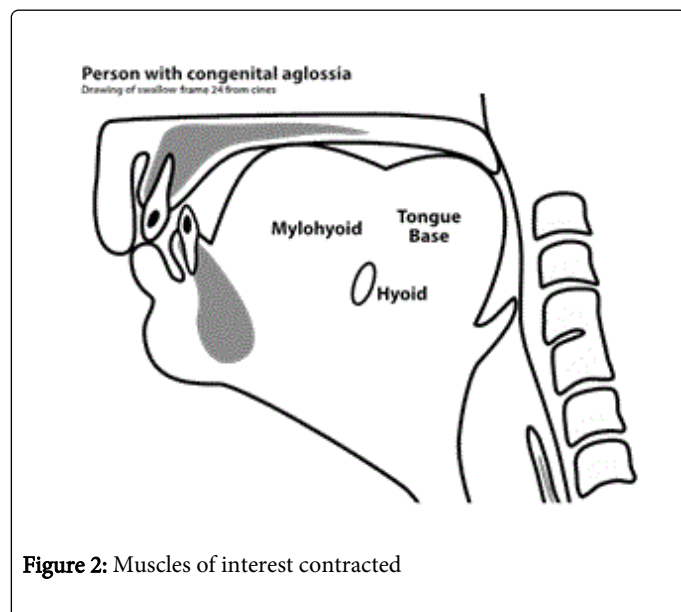
Vertical and Horizontal Movement for Saliva Swallow			
Variables	Standardized Beta Coefficients		Adjusted R Square
	Mylohyoid	Tongue Base	
Horizontal X Swallow			
X Hyoid	-----	-----	-----
X Mandible	-.893	1.128	.671
Vertical Y Swallow			
Y Hyoid	.987	-----	.972
Y Mandible	-----	.676	.437

Table 3: General Linear Model of Stepwise Regression for Measurements of Saliva Swallow Using Positions of Tongue Base and Mylohyoid as predictor measures for movement of Mandible and Hyoid.

Vertical and Horizontal Movement for Connected Speech			
Variables	Standardized Beta Coefficients		Adjusted R Square
	Mylohyoid	Tongue Base	
Horizontal X Speech			
X Hyoid	-----	.629	.391
X Mandible	.288	.283	..216
Vertical Y Speech			
Y Hyoid	.585	.381	.885
Y Mandible	.542	-----	.288

Table 4: General Linear Model of Stepwise Regression for Measurements of Contextual Speech Using Positions of Tongue Base and Mylohyoid as predictor measures for movement of Mandible and Hyoid.

For speech, there was a strong, statistically significant influence of the tongue base on the positions of the hyoid bone and strong collinearity of both the tongue base and mylohyoid in influencing the positions of the mandible. On the vertical plane for contextual speech, both the mylohyoid and base of tongue were influential for movement of the hyoid bone (Figure 2).



Discussion

This study investigated the movement of key processes for speech and swallow of a person with congenital aglossia (PwCA). Processes were measured according to earlier models that investigated the relationship between the structural movements involving the tongue, mandible, and hyoid bone in normal subjects for both eating and speech tasks [6]. Question 1 for this case study asked whether the movement of the pseudo-tongue would be significantly correlated with the movements of the mandible and hyoid bone for saliva swallow and contextual speech. Question 2 asked whether the muscles of the mylohyoid and pseudo-tongue determined the positions of the mandible and hyoid bone for those same tasks.

In normal subjects, the hyoid bone and mandible are correlated strongly with the tongue for swallow only; however, in this PwCA, the hyoid bone and mandible were strongly associated with movement of the pseudo tongue for both speech and swallow. Why this difference? Differences between this PwCA and PwoCA may be due in part to the mylohyoid and hyoid bone connections. In the vertical plane, the movements of the mylohyoid and tongue base were strongly correlated with hyoid bone movement for both speech and swallow in the PwCA. Why would this be? First, the PwCA presents with a pseudo tongue, comprised of a tongue base and the hypertrophied mylohyoid muscles. The mylohyoid serves as more than simply the floor of the mouth [12]. The fibers of the mylohyoid arise along the extent of the mylohyoid line, a well-defined bony ridge running along the inner surface of the body of the mandible from the mental symphysis to the last molar. The fibers run medially and inferiorly and join at a tendinous raphe, which extends from the mental symphysis to the hyoid bone. Contractions of the mylohyoid elevate the floor of the mouth and this contraction is very important to the initial stage of deglutition. During contractions, it tends to lift the hyoid. We suggest that the mylohyoid not only lifts

the hyoid during deglutition, but it also serves as an elevator for speaking purposes. These functions would explain the strong hyoid bone-mylohyoid connection during both speech and saliva swallows

It is interesting to note that Matsuo and Palmer [6] write that the hyoid served different functions for both speaking and eating in their normal subjects. They suggested that the tongue in normal subjects is associated with positions of the jaw and hyoid bone, but it also has intrinsic muscles and those muscles can act independently. In the case of the PwCA, there is no tongue, so the mylohyoid and tongue base will be more dependent on the mandible and hyoid for range of motion. This dependence would partially explain the reduced range of motion for both speech and swallow on the part of the PWCA.

In the vertical dimension, the mylohyoid and the tongue base were correlated strongly with the mandible for the saliva swallow. In the horizontal plane, the tongue base and mandible were moderately to strongly correlate. This finding is not surprising as the prime function of the mandible is for mastication. For speech, however, both the mylohyoid and the tongue base were again correlated with the mandible on the vertical plane. Why might this be? It has been found that the mandible contributes to vocal resonance differences by moving vertically and horizontally. Vertical openings for resonance adjustments range from 7-18 mm, whereas horizontal adjustments are more limited at 2-3 mm [12]. In previous articles published on this PwCA [2-4], the authors hypothesized that the PWCA was making hyoid adjustments to alter F2 to render speech more intelligible. The new findings suggest that the PWCA may also be adopting the compensatory technique of mandibular vertical adjustments to alter articulatory positions and thus formants, therefore rendering speech more intelligible.

What might account for some of the reduced correlations of the hyoid and mandible with the mylohyoid and tongue base on the horizontal plane? The reduced horizontal plane correlations might be accounted for by the fact that the PwCA presents with micrognathia and retrognathia. A smaller mandible may lead to reduced range of motion for anterior-posterior adjustments. In an interesting twist, this retrognathic mandible may also assist in part with the positioning of the lower incisors to assist with mid-palatal constrictions for the lingua-alveolar and mid-palatal sounds. This superior range of motion of the lower incisors is consistent with the vertical correlations of the mandible and mylohyoid.

Limitations

As discussed above, limitations of this study include that fact that the data collection was not designed for formal swallow analysis, which led to only a small (total 30 CRF frames) data set. Further, the two-dimensional views provided by the CRFs precluded the opportunity to visualize more specific movements of the structures involved in the study.

Conclusions

This present study revealed that for the PwCA, movements of the pseudo tongue surface had various and often independent relationships with mandibular and hyoid bone movements during both speech and oral saliva swallow. The positions of the hyoid bone and mandible demonstrated different responses to mylohyoid and tongue base movements.

Speakers who present with congenital or acquired structural and/or physiological reductions to the speech mechanism may present with the capacity to capitalize on a variety of actions during eating or swallowing to optimize the more finessed actions of speech. The highly predictable correlations of muscles for deglutition and speech suggest that this PwCA essentially 'bootstrapped' muscular actions (and limitations therein) developed for deglutition and used them to buttress speech and resonance as she matured. These actions are quite different from those of individuals with a tongue, who recruit a variety of muscles for the diverse acts of speaking and swallowing.

The compensatory strategy of "bootstrapping" for speech should be adopted by medical educators and clinicians when working with individuals with congenital or surgical oral-facial anomalies that involve the loss of or damage to the tongue structure. Focusing on that act of sucking, as in the case of this PWCA, could potentially activate compensatory muscles such as the mylohyoid, and cause them to develop in a hypertrophic manner, which would then serve as articulatory structures for the development of intelligible speech.

References

1. De Jussieu A (1718) Observations of the manner in which a woman with no tongue accomplishes the functions that depend on that organ. *Memoires of l'Academie Royale des Sciences de Paris* 6-16.
2. McMicken B, Von Berg S, Iskarous K (2012) Acoustic and perceptual description of vowels in a speaker with congenital aglossia. *Communications Disorders Quarterly* 34: 38-46.
3. McMicken B, Vento-Wilson M, Von Berg S, Iskarous K, Kim N, et al. (2013) Semantic and phonemic listener confusions in a case of isolated congenital aglossia. *Communication Disorders Quarterly* 35: 74-83.
4. McMicken B, Vento-Wilson M, Von Berg S, Rogers K (2014) Cineradiographic examination of articulatory movement of pseudo-tongue, hyoid, and mandible in congenital aglossia. *Communications Disorders Quarterly* 36:3-11.
5. Hiiemae KM, Palmer JB, Medicis SW, Hegener J, Jackson BS, et al. (2002) Hyoid and tongue surface movements in speaking and eating. *Oral Biol* 47: 11-27.
6. Matsuo K, Palmer JB (2010) Kinematic linkage of the tongue, jaw, and hyoid during eating and speech. *Oral Biol* 55: 325-331.
7. Ardran GM, Fulford GE, Kemp FH (1956) Aglossia congenita; cineradiographic findings. *Dis Child* 31: 400-407.
8. Ardran GM, Beckett JM, Kemp FH (1956) Aglossia congenital. *Archives of Disease in Childhood* 400-407.
9. Allison GR, Rappaport I, Salibian AH, McMicken B, Shoup JE, et al. (1987) Adaptive mechanisms of speech and swallowing after combined jaw and tongue reconstruction in long-term survivors. *Am J Surg* 154: 419-422.
10. Salles F, Anchieta M, Costa Bezerra P, Torres ML, Queiroz E (2008) Faber Complete and isolated congenital aglossia: Case report and treatment of sequelae using rapid prototyping models. *Oral Surgery, Oral Medicine, Oral Pathology, Oral Radiology, and Endodontics* 105: e41-e47.
11. Simpson API, Meinhold G (2007) Compensatory articulations in a case of congenital aglossia. *Clin Linguist Phon* 21: 543-556.
12. Zemlin WR (1998) *Anatomy and physiology*: Needham Heights, MA Allyn and Bacon.