

Spinal Cord MRSA Infectious Infarction after Anterior Cervical Decompression

Ahmad Shawky* and Khaldoun El-Abed

Department of Spine Surgery, AlMana General Hospital, Al-Khobar, Saudi Arabia

Abstract

Infection post anterior cervical decompression and fusion (ACDF) is not a frequent complication, the infection rate is around 0.6%. Occlusive vascular lesions secondary to infection, affecting the spinal cord, are diagnostic challenges. Spinal cord infarction due to deep infectious cause, particularly MRSA (Methicillin Resistant *Staphylococcus aureus*) is rare. We present here a rare case of post C6–C7 ACDF infection with MRSA that leading to cord ischemia with radiological changes and rapidly evolving neurological deterioration. Rapid evaluation with MRI scanning and initiation of antibiotic produced dramatic response with our patient and satisfactory recovery at one year follow up. We assume that is the first reported case of MRSA cord infection with ischemic myelopathic changes.

Keywords: Spinal cord infectious infarction; Anterior cervical fusion wound infection; MRSA wound infection; Cervical surgery wound complication

Introduction

Occlusive vascular lesions secondary to infection, affecting the spinal cord are diagnostic challenges. Surgical site infection is the most common hospital acquired infection that occurs in the early postoperative period in surgical patients [1]. The CDC/NNIS (National Nosocomial Infections Surveillance System) definitions of surgical site infection include deep surgical site and organ-space infections, including onset within thirty days after the operation (or within one year of the operation in case of placement of an implant).

Deep surgical site infection involves deep soft tissues (fascia and muscle), whereas organ-space infections include osteomyelitis, meningitis, and empyema [2]. Infection post anterior cervical decompression and fusion is not a frequent complication. The most common organisms implicated in the pathogenesis are *Staphylococcus aureus* and *Staphylococcus epidermidis* [3]. Spinal fusion surgeries have a higher infection rate when compared to other spinal surgeries. These rates varies based on the fusion type and approach; for example, the infection rate for anterior and posterior fusions combined was 3%, five times higher than the infection rate for anterior-only fusions (0.6%) [4].

Case Report

A 59-year-old male patient was admitted to our hospital complaining of difficulty walking, paresthesia in both upper and lower limbs, and urinary symptoms for the previous 2 months. He is a known case of hypertension and benign prostate hypertrophy on regular medications.

On examination he had imbalanced gait, positive Romberg's sign [5], generalized upper and lower limbs power of 3/5, hyper-reflexia and hyper-tonia, with positive Hoffman's sign.

His cervical MR scan (Figure 1) revealed C6-C7 disc prolapse with cord compression.

After routine pre-anesthesia work up, the patient underwent C6–C7 anterior decompression and cage fusion (Zimmer, trabecular metal cage) (Figure 2). The procedure was uneventful through a conventional left-side approach, under complete aseptic technique. The patient had a satisfactory recovery post operatively, with improvement of his sensations, and motor power of his upper and lower limbs, regaining his gait balance. The drain was removed in the first postoperative day;

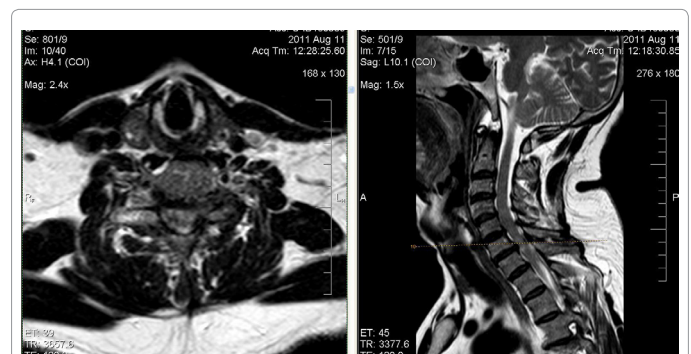

Figure 1: Preoperative MR images.

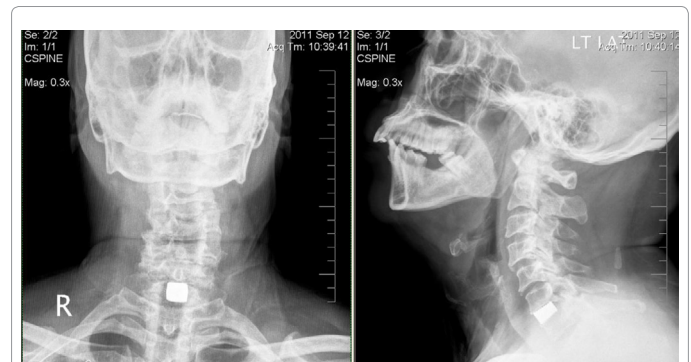

Figure 2: Post operative X-ray.

he received 3 doses of antibiotic (Cefuroxime) one at induction of anesthesia, and two post operatively.

***Corresponding author:** Dr. Ahmad Shawky, Spine Unit, Department of Orthopedic, Almana General Hospital, P.O. Box 311, Khobar, Saudi Arabia, Tel: 00966 55 30 72 912; Fax: 00966 3 898 0694; E-mail: ashawky2000@yahoo.com

Received January 08, 2013; **Accepted** January 23, 2013; **Published** January 25, 2013

Citation: Shawky A, El-Abed K (2013) Spinal Cord MRSA Infectious Infarction after Anterior Cervical Decompression. J Spine S2: 001. doi:10.4172/2165-7939.S2-001

Copyright: © 2013 Shawky A, et al. This is an open-access article distributed under the terms of the Creative Commons Attribution License, which permits unrestricted use, distribution, and reproduction in any medium, provided the original author and source are credited.

The patient was discharged on the second postoperative day with dry clean wound.

On the 8th post operational day the patient attended the OPD for follow up in a wheel chair, complaining of fever, chills, rigors and wound discharge of 12 hours duration. He developed sudden quadriplegia, and was found to have generalized hyper-reflexia, hyper-tonia, with weak anal tone and overflow urine incontinence.

He was admitted urgently for empiric IV antibiotic and MRI scans.

- The lab result showed high WBC=37000 CRP=177
- CSF analysis: high WBC count, protein, LDH and low glucose level
- Wound C/S: MRSA infection

MRI scan: spindle shape fluid collection anterior to vertebral bodies of C6- T2 level, high signal at C7 body indicating infection with spinal cord hyper intensity keeping with cord edema and inflammation (Figure 3).

Antibiotics were changed according to the culture and sensitivity result (Meropenem), and commenced on IV steroid regime for the next 48 hours.

After 10 days of treatment the patient began to show improvement in both sensory and motor functions. We repeated the MRI scan (Figure 4) which revealed reduction in the bone and cord edema with near complete reduction of the fluid collection.

The patient was discharged after 6 weeks; upon discharge he regained full sensory function all over the body. Power G4+/5 at the upper limbs muscle groups, lower limb power G3/5, with satisfactory urine and bowel control was observed.

Discussion

Surgical site infections are not uncommon following spinal operations. They can be associated with serious morbidity, mortality, and increased resource utilization [6].

Post-operative discitis in cervical spine is not a frequent

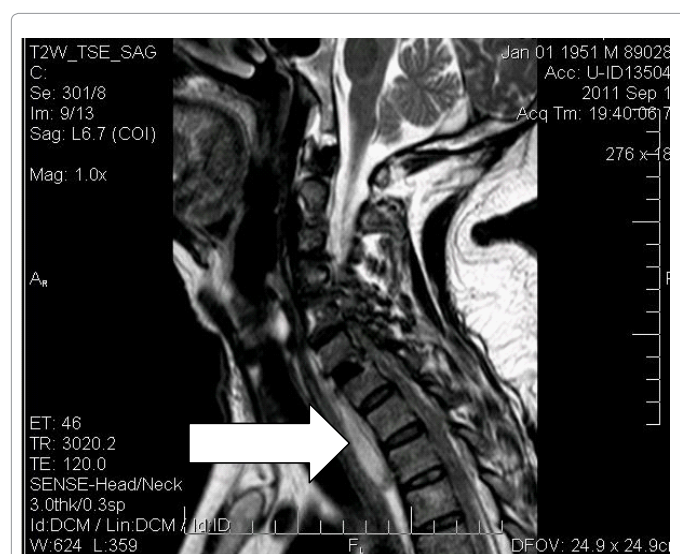


Figure 3: 8th day post-operative MR images showing anterior collection.

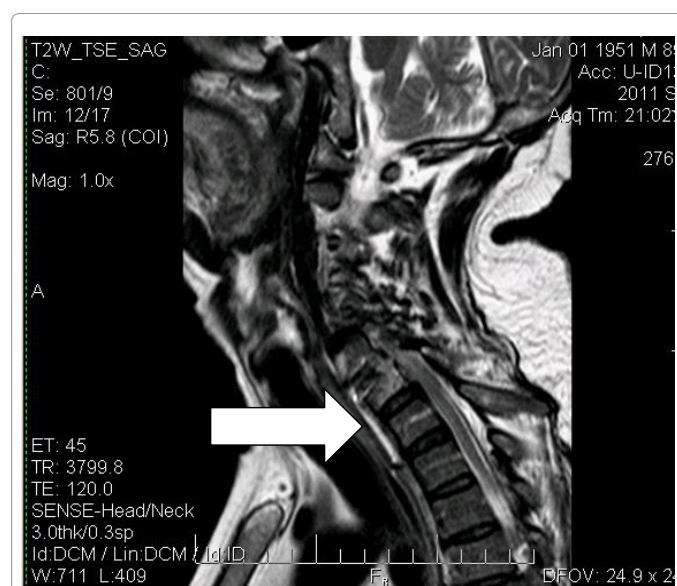


Figure 4: MRI after antibiotic showing disappearance of the collection comparing to previous MR in figure 3.

occurrence due to the rich vascularity and the routine use of antibiotic prophylaxis. The most recent NNIS summary by the CDC reported a 1.25% rate of surgical site infection after laminectomy and a 2.1% rate following spinal arthrodesis [7]. The current recommendation for antibiotic prophylaxis for neurosurgical and orthopedic procedures is 1 to 2 g of Cefazolin to be given in the hour before the incision in non allergic patients [8]. Thus, administration of an antibiotic outside this period would be considered suboptimal. The finding of an increased risk of surgical site infection associated with prophylactic antibiotic administration outside of the one hour window before the incision supports the recommendations of the Surgical Care Improvement Project (SCIP) to establish quality-improvement measures to ensure timely administration of prophylactic antibiotics [9]. Our patient had his prophylactic antibiotics upon induction of anesthesia, followed by two doses postoperatively. An operation at the cervical level was independently associated with a decreased risk of surgical site infection. Zeidman et al. previously reported a low rate of surgical site infection following cervical spinal operations [10].

A rapidly evolving neurological deterioration with this presentation could have had a myelopathic origin. The differential diagnoses include cervical myelopathy of transverse lesion syndrome, or spinal cord infarction secondary to occlusion of the tributaries of the vertebral artery due to deep infection.

Published series of reports of spinal cord infarction are relatively small, favorable ambulatory outcome correlated with improving neurologic examinations and relatively preserved strength in his abductors and knee extensors [11], as observed with our patient.

Spinal cord infarction due to deep infection, secondary to MRSA is rare. Rapid evaluation with MRI scanning and initiation of antibiotics are mandatory in view of acute neurological deterioration of these patients. It has been found that MRI is a useful means to detect and follow spinal cord injuries [12].

Regarding the recovery outcome of our reported patient, and despite his age being a negative factor for functional recovery [13], he made satisfactory neurological improvement, and was ambulatory

using technical aids after 6 weeks from the initial incidence. Upon 1 year follow up, he was walking unaided, with no major neurological deficit.

Conclusion

As observed with our patient, spinal cord infarction due to deep infectious cause, particularly MRSA is rare. We assumed that this is the first reported case of such post operative cord infection. Rapid evaluation with MR scanning, and initiation of antibiotics are mandatory in view of acute neurological deterioration of these patients, it has been found that MR is a useful means to detect and follow spinal cord injuries. Regarding the recovery outcome of our reported patient, and despite his age being a negative factor for functional recovery, he made satisfactory neurological improvement, and was ambulatory using technical aids after 6 weeks since the initial incidence and can walk independently after one year follow up.

References

1. Horan TC, Culver DH, Gaynes RP, Jarvis WR, Edwards JR, et al. (1993) Nosocomial infections in surgical patients in the United States, January 1986-June 1992. National Nosocomial Infections Surveillance (NNIS) System. Infect Control Hosp Epidemiol 14: 73-80.
2. Mangram AJ, Horan TC, Pearson ML, Silver LC, Jarvis WR (1999) Guideline for Prevention of Surgical Site Infection, 1999. Centers for Disease Control and Prevention (CDC) Hospital Infection Control Practices Advisory Committee. Am J Infect Control 27: 97-132.
3. Kulkarni AG, Hee HT (2006) Adjacent level discitis after anterior cervical discectomy and fusion (ACDF): a case report. Eur Spine J 15: 559-563.
4. Smith J, Shaffrey C, Sansur C, et al. (2009) Rates of infection following spine surgery based on 108, 419 procedures: A report from the Scoliosis Research Society Morbidity and Mortality Committee. Paper #138. Presented at the 24th Annual Meeting of the North American Spine Society. San Francisco.
5. Findlay GF, Balain B, Trivedi JM, Jaffray DC (2009) Does walking change the Romberg sign? Eur Spine J 18: 1528-1531.
6. Olsen MA, Nepple JJ, Riew KD, Lenke LG, Bridwell KH, et al. (2008) Risk factors for surgical site infection following orthopaedic spinal operations. J Bone Joint Surg Am 90: 62-69.
7. National Nosocomial Infections Surveillance System (2004) National Nosocomial Infections Surveillance (NNIS) System Report, data summary from January 1992 through June 2004, issued October 2004. Am J Infect Control 32: 470-485.
8. (2006) Antimicrobial prophylaxis for surgery. Treat Guidel Med Lett 4: 83-88.
9. Bratzler DW, Hunt DR (2006) The surgical infection prevention and surgical care improvement projects: national initiatives to improve outcomes for patients having surgery. Clin Infect Dis 43: 322-330.
10. Zeidman SM, Ducker TB, Raycroft J (1997) Trends and complications in cervical spine surgery: 1989-1993. J Spinal Disord 10: 523-526.
11. Cheshire WP, Santos CC, Massey EW, Howard JF Jr (1996) Spinal cord infarction: etiology and outcome. Neurology 47: 321-330.
12. Luo CB, Chang FC, Teng MM, Chen SS, Lirng JF, et al. (2003) Magnetic resonance imaging as a guide in the diagnosis and follow-up of spinal cord infarction. J Chin Med Assoc 66: 89-95.
13. Salvador de la Barrera S, Barca-Buyo A, Montoto-Marqués A, Ferreira-Velasco ME, Cidoncha-Dans M, et al. (2001) Spinal cord infarction: prognosis and recovery in a series of 36 patients. Spinal Cord 39: 520-525.