

Study regarding the histological features of enamel caries

Cristina Nucă, Ștefan Bocskay, Corneliu Amariei, Laura-Daniela Rusu

Constanța, România

Summary

The study of the enamel caries from histological and also therapeutical point of view is one of the most important priorities of the preventive dentistry.

The present study was aimed to assess the histological features of the enamel caries, and also of the remineralization process of these lesions.

Materials and methods: the study was made on teeth demineralized with phosphoric acid (H_3PO_4 37%) to assess the enamel lesions, and then remineralized by immersing in a solution of artificial saliva, with and without addition of fluoride.

The results show the onset of the enamel caries in pits and fissures, as two independent lesions on opposite walls of the fissure, and also the histological aspects of the enamel caries, before and after the remineralization process. On the ground sections examined in polarized light in aqueous medium, the only two histological areas showed in such medium could be viewed – the body of the lesion and the surface zone. The examination in Canada balsam showed the only histological zone that could be viewed, the dark zone, with positive birefringence, different from the negative birefringence of the sound enamel and of the other areas of the enamel lesion.

To conclude, we can state that the remineralization of enamel caries is a real fact, demonstrated by the histological exam and stimulated by immersing the carious lesion in artificial saliva, with and without fluoride.

Keywords: demineralization, remineralization, initial lesion.

Introduction

In the last decades, the histological research regarding the de- and remineralization processes in the initial lesion of the enamel became a priority of the modern preventive dentistry.

In optical microscopy, the enamel lesions are examined on ground sections approximately $100\mu\text{m}$ thick, using the ordinary and polarized light. By this exam the demineralization of the enamel and also the way of progression of caries on different surfaces of the teeth can be shown [2,3].

On the surfaces with pits and fissures, the carious lesion starts bilaterally on the walls of the fissure, giving the appearance of two small smooth surface lesions „in the

mirror”. In the enamel fissures produced by microfractures, the progression of the caries is similar [4,7].

The enamel lesion on the smooth surface of a tooth is conical in shape, having its apex pointing towards the dentine [1,4,7].

The small enamel caries is placed under a well-mineralized surface layer, and has four histological zones: the translucent zone, the dark zone, the body of the lesion and the surface zone, described for the first time by L. M. Silverstone [7,8,10].

The aim of this study is to examine the histological features of the enamel caries in polarized light microscopy, before and after remineralization, and to show the way of progression of the initial caries in enamel.

Materials and Method

Twenty teeth were used in this study (first permanent molars and first sound premolars extracted for orthodontic reasons).

All teeth were carefully brushed to remove the organic tissues, then washed with distilled (non-ionic) water, and degreased with chloroform.

To study the demineralization process, the teeth were treated for two minutes, on different surfaces, with phosphoric acid (H₃PO₄ 37%), this being, after Silverstone [7,8], the only way to produce artificial enamel lesions similar to the natural carious lesions.

To study of the remineralization process, 10 of the demineralized teeth were immersed, for one week, in two different solutions:

- artificial saliva [3], made by CaCl₂ (calcium chloride), NaHCO₃ (sodium bicarbonate), NaCl (sodium chloride), KCl (potassium chloride), NaH₂PO₄ (potassium dihydrogen phosphate) and adjusted at a neutral pH – 5 teeth;

- artificial saliva with fluoride (made by artificial saliva with addition of fluoride up to 5.21 ppm) [5].

Ground sections have been prepared from all these teeth after the following method:

- the teeth were grounded in bucco-lingual direction till a thickness of 2-4 mm;
- by manual grounding on a wet glass plate, with aluminum oxide (Al₂O₃) powder with different granulations, we made sections of less than 200µm thickness.

These ground sections were then examined at the polarized light microscope, in aqueous medium, in Canada balsam medium or after coloration with PASS solution.

Results

The first section (*Figure 1*) shows *smooth surface enamel caries* examined in aqueous medium, which did not evidence the trans-

parency of the lesion.

The body of the lesion can be observed, with positive birefringence and dark aspect, and also the intact surface zone of the lesion.

The triangular shape of the lesion can also be observed, with the apex pointing towards the enamel-dentine junction. The progression of the lesion along the enamel lamella is also evident.

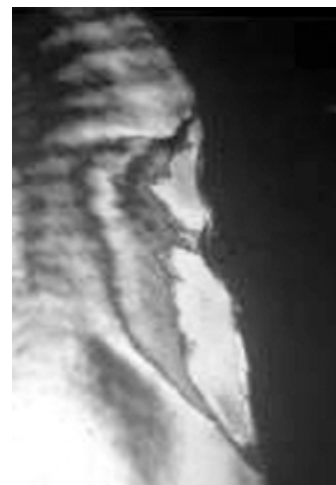
Figure 1



Figure 2 shows another *smooth surface enamel caries*, examined in Canada balsam.

The histological areas of the lesion can be seen: the translucent zone with a smaller negative birefringence than the sound enamel, the dark zone with positive birefringence, and the body of the lesion, with negative

Figure 2



birefringence. The discontinuity of the surface zone is due to the destruction of the section in the preparation time.

In the next section, examined also in Canada balsam (*Figure 3*), the demineralization produced a *deep lesion* with the loss of a part of the enamel, the destruction of the fundamental substance and the loss of a part of the mineral component. The histological zones cannot be clearly seen, and the enamel has lost its prismatic structure.

Figure 3

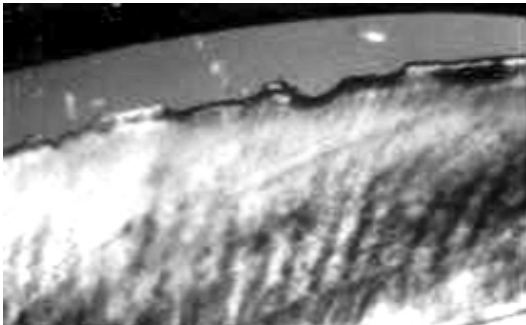
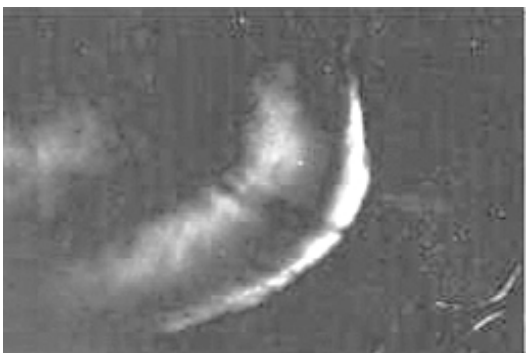

Figure 4 shows an *initial lesion* with triangular shape placed in the tip of the cusp (the slide is examined in Canada balsam). The surface zone, translucent due to the negative birefringence is evident.

Figure 4



Next slide, studied in aqueous medium (*Figure 5*), shows an *initial lesion* of enamel (the brown strip) localized on the tooth neck.

Figure 5

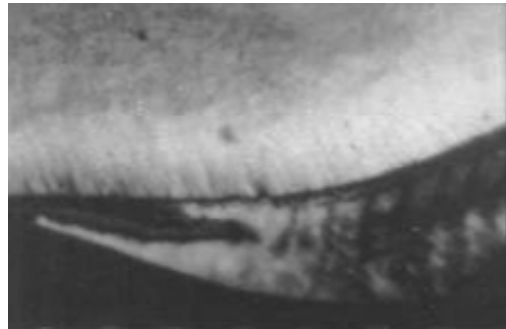
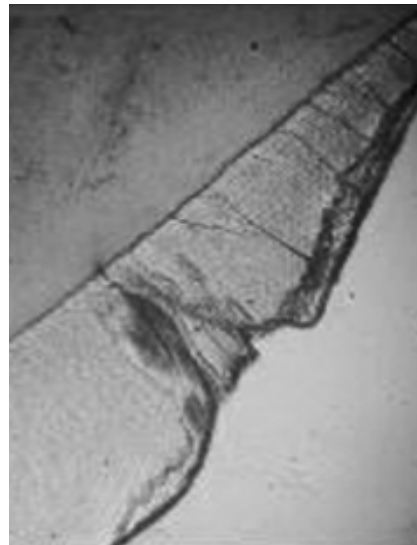


Figure 6 shows an *initial lesion* starting from a superficial ditch near the neck of the tooth. The lesion has a triangular shape and progresses along the enamel lamellae, which prolong the ditch. The slide is colored with PASS solution.

Figure 6



Next slide (*Figure 7*) shows an *initial lesion* placed on a deep and tight ditch, with a small opening orifice.

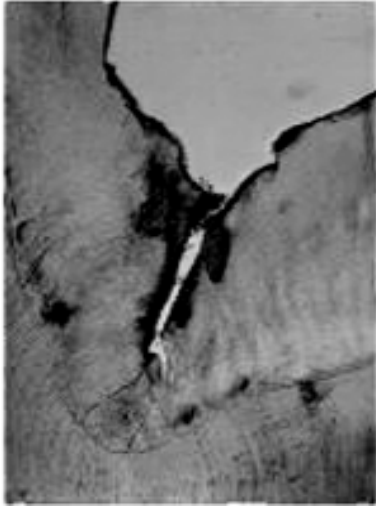
On the opposite walls of the ditch there are two independent, triangular lesions, with the top toward the enamel-dentine junction.

The slide is colored with PASS solution, the lesions appearing in red color.

The base of the ditch presents enamel lamellae oriented as a “fan” towards the enamel-dentine junction and misses the

organic plug usually existing on this type of fissure.

Figure 7



The slide is fixed in Canada balsam, medium in which the only zone that can be clearly evident on a remineralized lesion is the dark zone, with positive birefringence different from healthy enamel and other zones of the lesion.

Figure 9

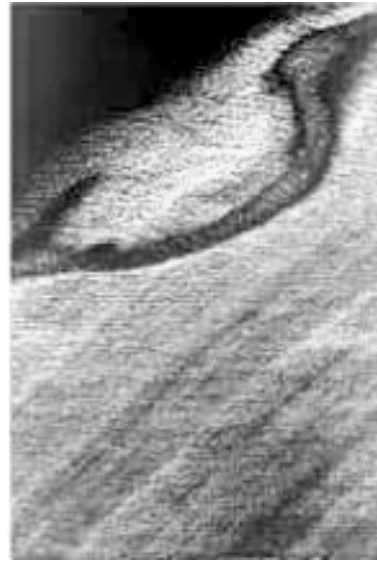

Figure 8 shows a *remineralized lesion*. After artificial demineralization the tooth was introduced for 7 days in artificial saliva solution. The slide is studied in aqueous medium.

We observe the absence of the dark appearance of the body of the lesion and the erosion of the surface zone, which encouraged the remineralization phenomenon. The prismatic structure is different from the healthy adjacent enamel structure.

Figure 8

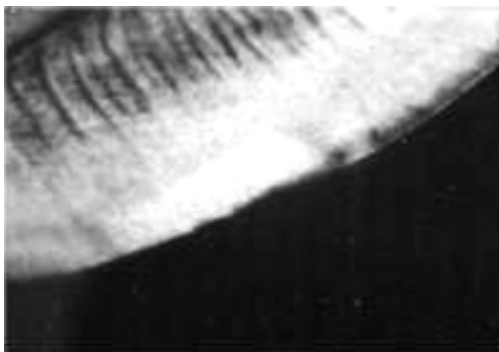


Figure 10 shows a smooth surface *lesion, remineralized* after one week of immersion in artificial saliva. The surface zone is intact and appears translucent (with negative birefringence) at examination in aqueous medium polarized light.

Figure 10

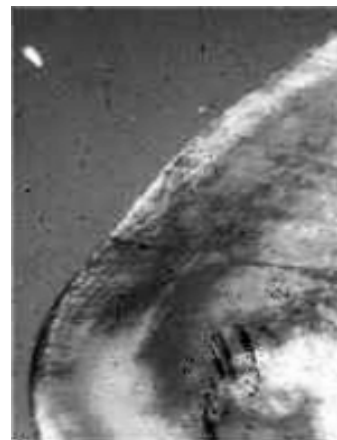
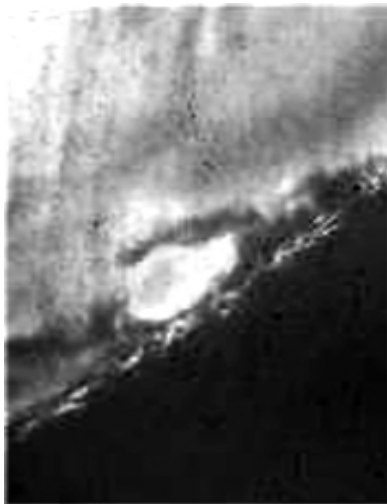

Figure 9 shows an enamel *remineralized lesion* after immersion for a week in artificial saliva solution with fluoride.

Figure 11 shows a smooth surface lesion, remineralized after immersion in artificial saliva and fluoride. The slide is examined in aqueous medium. The surface zone appears translucent and with negative birefringence, in contrast with the positive birefringence of the body lesion.

Figure 11



Next image (Figure 12) shows another smooth surface remineralized lesion, examined also in aqueous medium. After demineralization the tooth was treated with artificial saliva with fluoride. The translucent surface zone is interrupted at an enamel lamella.

Figure 12



Discussions

In order to assess the histological features of the „white spot” lesions, in the present study we used exclusively qualitative methods, as the examination in polarized light. For a correct interpretation of the results, certain specifications are needed.

The histological features of the enamel lesion have been described in many specialty studies. According to L. M. Silverstone [7,8], the enamel lesion has four histological zones, with distinct features.

The interpretation of the histological studies is usually made on the basis of the relation between the structure of the sound and carious enamel and their images in polarized light.

The mature human enamel is formed by apatite crystals arranged in aligned prisms. The intercrystal spaces are filled with organic components and water [9,10]. The mineral part, as the most non-cubical crystals, has the property to refract the polarized light in two rays with different amplitudes. These structures are named birefringent, and the structure has two refractive indices, related to the two planes of transmission within the crystal.

The positive birefringence is referring to the ray with the smaller amplitude (the slower ray), and the negative birefringence – to the ray with the biggest amplitude (the faster ray). The type of the birefringence is related arbitrarily to some morphological feature of the enamel prism, and called intrinsic birefringence of the tissue.

The enamel has a negative intrinsic birefringence, related to the prism direction.

The birefringence of the organic component of the enamel is positive, but with small amplitude, so it can be disregarded in the histological studies [7,8].

Apart from the mineral and organic constituents, the enamel also has some pores with a different birefringence. When the pores are filled with a medium with different

refractive index from that of enamel crystals (R.I.= 1.62), the birefringence of the enamel becomes „composed”, and is transformed from negative into positive.

The carious enamel will show a negative intrinsic birefringence and a „composed” positive birefringence, due to the intercrystal spaces. The observed birefringence is the sum of these two.

When the pores are filled with a medium having the same refractive index as sound enamel (such as quinoline, Thoulet solution, Canada balsam), the „composed” birefringence will be avoided [7,8,9].

The image formed at examination in polarized light depends of the medium used for examination. The higher the difference between the refraction index and the one of the examination medium, the more positive the “composed” birefringence is. The more the volume of the enamel pores grows (at the same time with the demineralization process) the higher the positive birefringence grows [7,8].

Intrinsic negative birefringence of the enamel can be reduced, compensated or inverted depending on the examination medium.

Thus it is possible to approximate the volume of the pores of the enamel decay by observing total birefringence.

The description of enamel decay structure is realized beginning with those four histological zones of which names are related with their image in polarized light and with pore volume in each zone.

Quinoline has the same refractive index as the sound enamel – 1.62.

The translucent zone is the deepest area of the lesion, having a pore volume of 1%, differing from the subjacent sound enamel (0.1% pore volume). It has a translucent appearance and can be viewed only in quinoline medium or in Canada balsam (with R.I. similar to that of the sound enamel – 1.62). It cannot be viewed when examined in an aqueous medium.

In the dark zone (above the translucent zone) the pore volume is about 2-4%, but the pores have different sizes. Quinoline cannot fill the small pores of the dark zone, these remaining filled with air (with an R.I. smaller than the enamel hidroxyapatite), giving the dark aspect – positive birefringence. At examination in an aqueous medium, the small water molecules penetrate both the large and the small pores, and the zone cannot be viewed [7,8].

The body of the lesion is the third and most porous histological zone of the lesion (the pore volume is of 5% on the outskirts and 25% in the middle). It represents the most spread zone and with the highest degree of demineralization of the enamel lesion. It appears translucent in quinoline examination. In aqueous medium examination the body of the lesion, placed under the surface zone, gets a positive birefringence and a dark aspect, unlike negative birefringence of the healthy enamel and of the rest of the lesion. The prismatic structure and transversal striations can be well visualized. The body lesion is the most evident histological zone in examination in aqueous medium.

The surface zone with a volume of pores of 1% appears relatively the same at examination in polarized light in quinoline medium [6,7].

Examining the initial lesion in aqueous medium, although the porous enamel under the surface presents a positive birefringence, the surface maintains a negative birefringence.

In experimental in vitro remineralization studies in quinoline examination, the dark zone spreads at the upper part to the healthy enamel and the body lesion gets the histological characteristics of the dark zone [7,8,11].

These explanations were necessary for the interpretation of the present study results.

Regarding the appearance of the decay

lesion, the study emphasizes once more the decay onset in grooves and fissures – as two independent, triangular lesions with a smooth surface, on the opposite walls of the fissure – and also the coalescence of these lesions in the advanced phase of the decay which has as result the formation of a cone with the base toward the enamel-dentine junction.

On the slides examined in aqueous medium they were visualized as a dark triangular shape placed under the enamel surface.

These triangles represents the only two histological zones visible at examination of ground sections under polarized light in aqueous medium – the body of the lesion with positive birefringence and dark aspect and the zone of negative birefringence surface, a little bit lower than the healthy enamel.

The surface zone of the remineralized lesion is untouched and large, having a silvery-white aspect at examination in aqueous medium.

The examination of remineralized lesion in Canada balsam showed the only histological zone visible in such medium –

the dark zone, with positive birefringence, comparing to the negative one of the healthy enamel and other histological zones of the lesion.

Conclusions

1. The decay lesion does not represent a simple and continuous demineralization phenomenon, but is an alternative process of destruction and repairing, of successive de- and remineralizations.

2. The most important repairing mechanisms of the enamel lesion are represented by the repairing saliva mechanism and by the remineralization mechanism of fluoride ions.

3. *In vitro* exposure of initial enamel lesions in artificial saliva solution with and without fluoride has as result the remineralization phenomenon.

4. The remineralization of initial enamel lesions is a clear act, which can be stimulated by relatively simple methods concerning the modifying of environment conditions of the teeth, and represents one of the most important methods of preventing decay.

References

1. Featherstone JD: Prevention and reversal of dental caries: role of low-level fluoride. *Comm Dent and Oral Epidemiol*, 1999; vol. 27, no. 1: 31-40.
2. Fejérskov O, Nyvad B, Joost LM: Human Experimental Caries Models: Intra-oral Environmental Variability. *Advances in Dental Research*, 1994; vol. 8, no. 2: 134-143.
3. Itthagarun A, Wei SHY: Morphology of initial lesions of enamel treated with different commercial dentifrices using a pH cycling model: Scanning Electron Microscopy observations. *International Dental Journal*, 1999; vol.49, no.6: 352-360.
4. Murray JJ, Rugg-Gunn AJ, Jenkins GN: Fluorides in Caries prevention. ©Butterworth-

Heinemann Ltd, 1991.

5. Nucă C, Amariei C: Studiu experimental *in vitro* privind remineralizarea leziunilor incipiente de smalț (In vitro experimental study regarding the remineralization of enamel initial lesions) – in Romanian. *Revista Dento-Medica*, 2002; no 1: 51-55.

6. Øgaard B, Seppä L, Rolla G: Professional Topical Fluoride Applications-Clinical Efficacy and Mechanism of Action. *Advances in Dental Research*, 1994; vol. 8, no. 2: 190-201.

7. Silverstone LM, Hicks MJ, Featherstone MJ: Dynamic factors affecting lesion initiation and progression in human dental enamel. Part I. The dynamic nature of enamel caries. *Quintessence International*, 1998; vol. 19, no. 10: 92-102.

8. Silverstone LM, Johnson NW, Hardie JM,

Williams RAD: Dental Caries – Aetiology, Pathology and Prevention. The MacMillan Press Ltd., 1981.

9. Sullivan RJ, Fletcher R, Bachiman R, Penugonda B, Le Geros RZ: Intra-oral Comparison and Evaluation of the Ability of Fluoride Dentifrices to Promote the Remineralization of Caries-like Lesions in Dentin and Enamel. Journal of Clinical Dentistry,

1995; vol. VI, no. 2: 135-138.

10. Thylstrup A, Bruun C, Holmen L: In vivo Caries-Models – Mechanisms for caries Initiation and Arrestment. Advances in Dental Research, 1994; vol. 8, no. 2: 144-157.

11. Thylstrup A, Fejerskov O: Textbook of Clinical Cariology. Munksgaard, Copenhagen, 1996.

Correspondence to: Lecturer Dr. Cristina Nucă, Faculty of Dental Medicine and Pharmacy, Department of Preventive Dentistry, 7, Ilarie Voronca str., 900684 Constanta, Romania.