

Submandibular Salivary Sialolith: A Case Report with Review of Literature

Harjit Kaur, Sanjeev Jain, Radhika Kamboj, Gaurav Pandav

Department of Periodontology, Guru Nanak Dev Dental College & Research Institute, Sunam, Punjab, India

Abstract

Sialolithiasis is a condition characterized by the obstruction of a salivary gland or its excretory duct due to the formation of calcareous concretions, resulting in salivary ectasia and subsequent dilatation of the salivary gland. The majority of sialoliths occurs in the submandibular gland or its duct and is a common cause of acute and chronic infections. Majority of salivary stones are less symptomatic or cause minimal discomfort but the larger stones may interfere with the flow of saliva and cause pain and swelling. Sialoliths are calcified organic matter that is formed within the secretory system of the major salivary glands. Salivary gland calculi account for the most common disease of the salivary glands, and may range from tiny particles to several centimeters in length. This case report describes a patient presenting with submandibular gland sialolith.

Key Words: salivary gland, Calculi

Introduction

The deposition of calcium salts, primarily calcium phosphate, usually occurs in the skeleton. It is referred to as heterotopic calcification when it occurs in an unorganized fashion in soft tissue. Heterotopic calcification which results from deposition of calcium in normal tissue despite normal serum calcium and phosphate levels is known as idiopathic calcification. Sialoliths belong to the category of idiopathic calcification [1].

Sialolithiasis is the most common disease of salivary glands. It is estimated that it affects 12 in 1000 of the adult population [2]. It usually appears between the age of 30 and 60 years, and it is uncommon in children as only 3% of all sialolithiasis cases occur in pediatric population [3]. Males are affected twice as much as females [4]. It involves most commonly the major salivary glands. More than 80% of the sialoliths occur in the submandibular gland or its duct, 6% in the parotid gland and 2% in the sublingual gland or minor salivary glands. The submandibular gland is more susceptible to the development of the salivary calculi than parotid gland because:

- The Wharton's duct is longer and wider than the Stensen's duct.
- The salivary flow is against gravity in the submandibular gland.
- The salivary submandibular pH is more alkaline and mucin proteins, calcium and phosphates are contained in greater amount than serous parotid saliva [5].

Dehydration, allergic states, infection of the oral cavity make saliva denser and start the accumulation of ductal debris which in turn allow the precipitation of mucoid elements and salts in order to form the organic matrix. When the stone reaches a size to obstruct the duct the secretion in the gland is hampered. This condition facilitates destruction of the gland [6].

Clinically, sialoliths are round or ovoid in shape, rough or smooth in texture and yellowish in color. Submandibular stones consist of 82% inorganic material and 18% organic material, whereas parotid stones are composed of 49% inorganic and 51% organic material [7]. The inorganic material comprises of calcium phosphate, smaller amounts of carbonates in the form of hydroxyapatite and smaller amounts of magnesium, potassium, ammonia, whereas organic material consists of

various carbohydrates and amino acids [8].

Case Report

A 55 years old patient reported to the department of periodontology with a chief complaint of pain on the right lower back tooth region since 4-5 months. Pain was mild, intermittent, radiating posteriorly to the neck which occurred on its own and relieved on taking medication. The patient visited a local doctor for the same who prescribed medicines to him. The details of medicines were not available with patient.

On Intraoral hard tissue examination, the associated teeth were non carious and on percussion none of the tooth was tender. The intraoral examination also did not present any abnormality that could be associated with the severity/ nature of pain, the patient was suffering. Although bleeding on probing was present but it could not explain the cause of pain.

On further investigation, patient gave the history of having pain and episodes of swelling on the right side of floor of mouth occurring with meals. Intraoral examination revealed a mobile, non tender swelling extending from midline to first molar, solid to the touch and not adherent to any deeper structure (*Figure 1*).

Orthopantomogram revealed (OPG), presence of

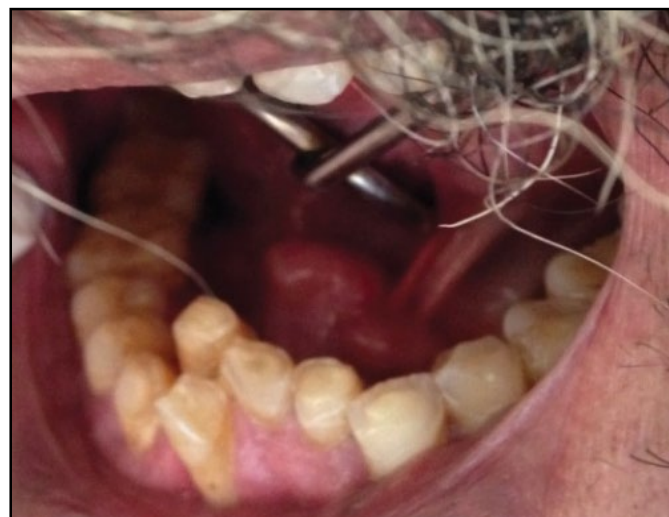

Figure 1. (Preoperative intraoral view showing the swelling in floor of mouth).

radioopaque mass seen in the right body of the mandible measuring around 2×1.1 cm in size, oval in shape extending superiorly 2 cm above the apices of 43, 44 teeth and inferiorly 4 cm above the lower border of the mandible (Figure 2).

Mandibular occlusal radiograph revealed the presence of radio-opaque mass, seen in the right body of the mandible measuring around 2×1.1 cm in size, oval in shape extending from mid of 44 to the mid of 46 (Figure 3).

Medical history revealed that patient had undergone PTCA (Percutaneous Transluminal Coronary Angioplasty) 5 months ago. Right femoral artery was punctured at time of surgery and a stent was deployed. Following the surgery, patient was on anticoagulants so the surgery for the sialolith removal was postponed. Surgery was planned on completion of 6 months and patient was advised to stop taking anticoagulant 4 days before surgery after physician consultation.

On the day of surgery, under local anesthesia, once the sialolith was located, it was distally fixed with a suture in order to prevent any movement along the duct. An incision along the mucosa of the swollen floor was given and the Warton's duct was opened creating a larger access to sialolith. Then the giant calculus was easily removed with a light digital pressure through the incision (Figure 4) and after the sialolith was out (Figure 5), suturing of the incision was performed (Figure 6).

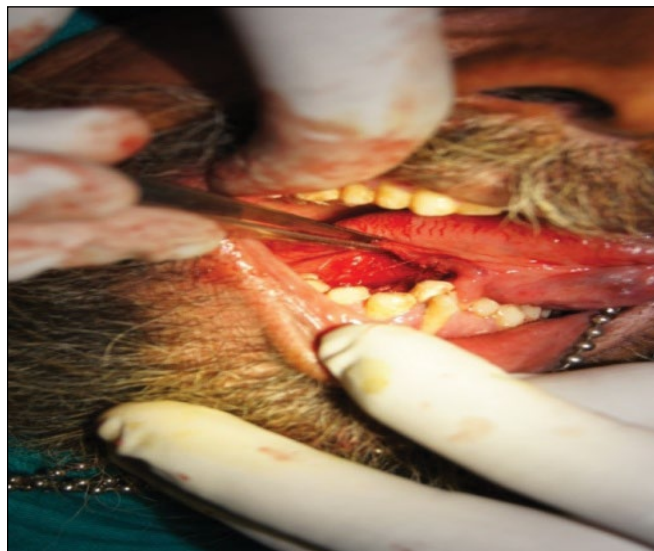


Figure 4. Intraoperative photograph of Warton's right duct after the sialolith removal.

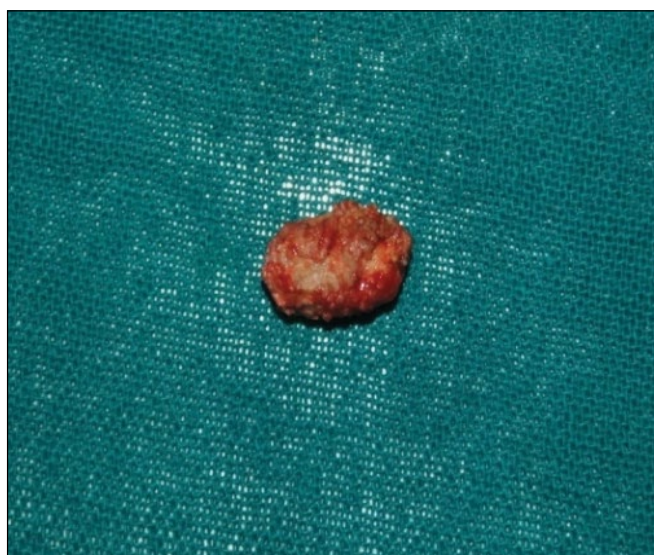

Figure 5. The Sialolith measuring 2×1.1 cm in size.

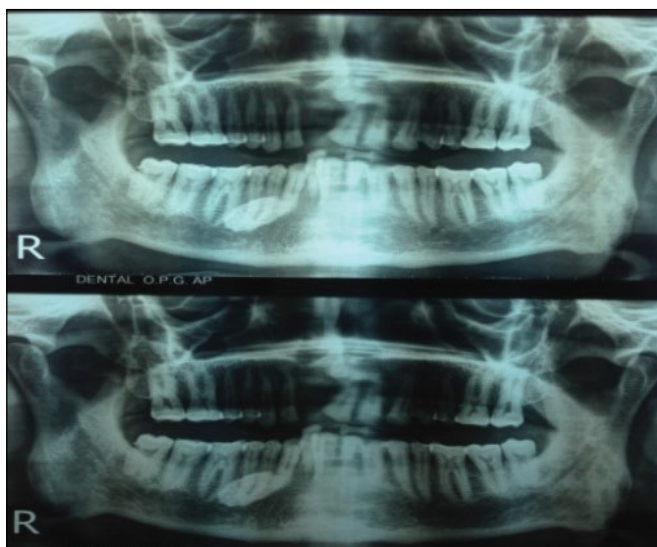


Figure 2. Orthopantomograph showing radiopaque mass in right body of mandible).

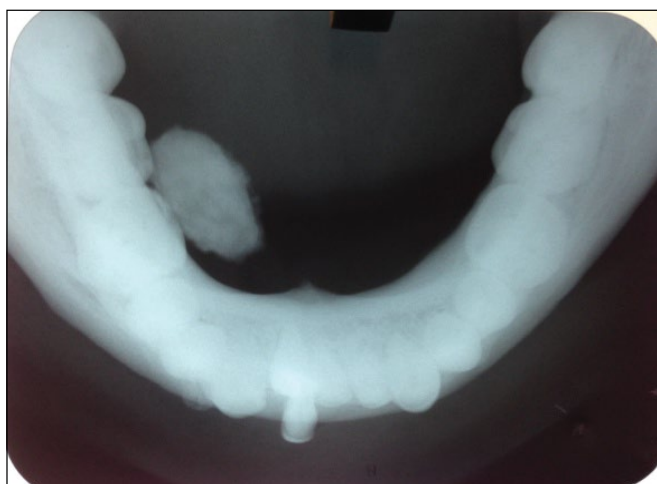

Figure 3. Trans-occlusal radiograph showing sialolith in the right body of mandible).

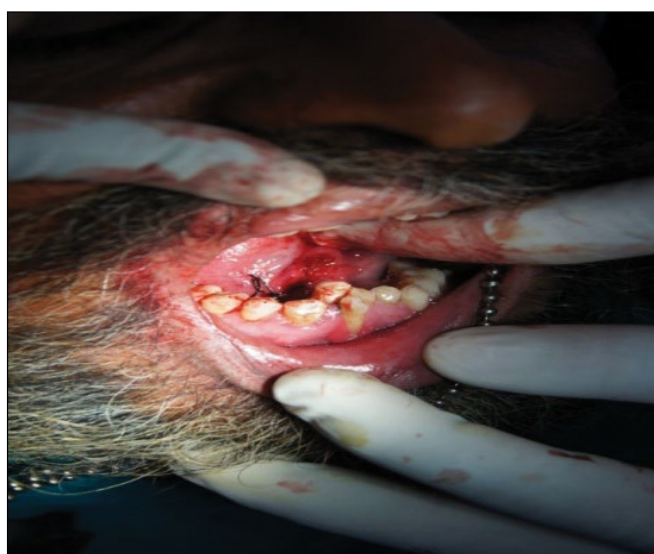

Figure 6. Intraoperative view of sutured duct after sialolith removal.

The postoperative period was uneventful and patient was prescribed analgesics and increased intake of water.

Discussion

The aetiologic factors involved in the sialolith formation can

be classified into two different groups: on the one hand, saliva retention due to morpho-anatomic factors (salivary duct stenosis, salivary duct diverticuli, etc.), on the other, saliva composition factors (high supersaturation, crystallization inhibitor deficit, etc [9]). However, the exact etiology and pathogenesis of salivary calculi is unknown. According to the literature, formation of sialolith can occur in two phases: A central core and a layered periphery [10]. The central core is formed by the precipitation of salts which are bound by certain organic substances. The second phase consists of the layered deposition of organic and inorganic material. Parotid stones are thought to form most often around a nidus of inflammatory cells or a foreign body whereas submandibular stones are thought to form around a nidus of mucous [11].

Another theory has proposed that an unknown metabolic phenomenon can increase the salivary bicarbonate content, which alters calcium phosphate solubility and leads to precipitation of calcium and phosphate ions [8]. A retrograde theory proposed for sialolithiasis suggested that, substances or bacteria within the oral cavity might migrate into the salivary ducts and become the nidus for further calcification [10]. Salivary stagnation, increased alkalinity of saliva, infection or inflammation of the salivary duct or gland, and physical trauma to salivary duct or gland may predispose to calculus formation [2]. Stone formation is not associated with systemic abnormalities of calcium metabolism [8]. Electrolytes and parathyroid hormone studies in patients with sialolithiasis have not shown abnormalities [12]. Gout is the only systemic illness known to predispose to salivary stone formation, although in gout the stones are made predominantly of uric acid [8]. The proposed association between hard water areas and salivary calculi has been shown to be incorrect [12].

Salivary calculi are usually small and measure from 1 mm to less than 1 cm. They rarely measure more than 1.5 cm. Mean size is reported as 6 to 9 mm. Giant sialoliths are rare and defined as the size of 3.5 cm or larger [13]. The largest sialolith reported in the literature was 70 mm in length in Wharton's duct and was described as having a "hen's egg" size [14]. The size of stone in this patient was 2×1.1 cm.

Salivary gland calculi are characterized by pain without any obvious reason or at meal times. In this report, patient had a history of having episodes of pain in right lower side of face since 4-5 months. Pain is only one of the symptoms and it does not occur in 17% of the cases [15]. Salivary duct swelling is another characteristic feature of salivary gland calculi as reported in this case. The symptom, referred by the patients during the meal times, are due to the higher stimulation of the salivary secretion and to the duct's obstruction that prevents its smooth flow [15].

It may be possible that obstruction caused by large calculi

is sometimes asymptomatic as obstruction is not complete and some saliva manages to seep through or around the calculus. Long term obstruction in the absence of infection can lead to atrophy of the gland with resultant lack of secretory function and ultimately fibrosis [8].

Imaging studies are very useful for diagnosing sialolithiasis. Conventional intra-oral X-ray may be more useful than extra-oral radiography, particularly trans-occlusal endoral radiography [15]. Forty percent of parotid and 20% of submandibular stones are usually radiolucent [8]. In our case however mandibular transocclusal radiograph proved more reliable as it revealed the extent of calculi better than OPG and intraoral periapical radiograph.

The treatment objective for giant sialoliths, as for the standard sized stones, is restoration of normal salivary secretion. Patients presenting with sialolithiasis may benefit from conservative management, especially if the stone is small [8]. The patient must be well-hydrated and the clinician must apply moist warm heat along with massage of the gland. Sialogogues are useful to promote production of saliva and to flush the stone out of the duct. The ultimate objective of giant sialoliths treatment is restoring a normal salivary flow. Whenever the stone can be palpated intraorally, the best option is to remove it through an intraoral approach [11].

Almost half of the submandibular calculi lie in the distal third of the duct and are amenable to simple surgical release through an incision in the floor of the mouth, which is relatively simple to perform and not usually associated with complications [16]. Alternative methods of treatment have emerged such as the use of extracorporeal shock wave lithotripsy (ESWL) and more recently the use of endoscopic intracorporeal shockwave lithotripsy (EISWL), in which shockwaves are delivered directly to the surface of the stone lodged within the duct without damaging adjacent tissue (piezoelectric principle) [13].

A diet rich in proteins and liquids including acid food and drinks is also advisable in order to prevent the formation of further new sialolith into the salivary gland [15].

Conclusion

Sialoliths are always a consideration in submandibular and facial pain when related to meal times. The correct diagnosis requires a careful history and use of correct imaging techniques to define the position and size of sialolith. Although various advanced diagnostic and treatment modalities have emerged in the management of sialolith. The conventional modalities retain their popularity to date. This case report has illustrated a case of submandibular sialolith that was diagnosed clinically and radiographically and treated surgically with no postoperative complications.

References

1. White SC, Pharoah MJ. Oral radiology principles and interpretation. 2014; 597-614
2. Leung AK, Choi MC, Wagner GA. A case report: Multiple sialoliths and a sialolith of unusual size in the submandibula duct. *Oral Surgery, Oral Medicine, Oral Pathology, Oral Radiology, and Endodontology*. 1999; **87**: 331-333.

3. Nahalieli O, Eliav E, Hasson O, Zagury A, Baruchin AM. Pediatric sialolithiasis. *Oral Surgery, Oral Medicine, Oral Pathology, Oral Radiology, and Endodontology*. 2000; **90**: 709-712.
4. Cawson RA, Odell EW. Essentials of oral pathology and oral medicine. 6th edition, Churchill Livingstone; Edinburgh 1998: 239-240.
5. Raksin SZ, Gould SM, William AC. Submandibular gland sialolith of unusual size and shape. *Journal of Oral Surgery*. 1975; **33**: 142-145.

6. Batori M, Mariotta G, Chatelou H, Casella G, Casella MC. Diagnostic and surgical management of submandibular gland sialolithiasis: report of a stone of unusual size. *European Review for Medical and Pharmacological Sciences*. 2005; **9**: 67-68.
7. Zenk J, Benzel W, Iro H. New modalities in the management of human sialolithiasis. *Minimally Invasive Therapy & Allied Technologies*. 1994; **3**: 275-284.
8. Williams MF. Sialolithiasis. *Otolaryngologic Clinics of North America*. 1999; **32**: 819-823.
9. Grases F, Santiago C, Simonet BM, Costa-Bauza A. Sialolithiasis: mechanism of calculi formation and etiologic factors. *Clinica Chimica Acta*. 2003; **334**: 131-136.
10. Marchal F, Kurt AM, Dulguerov P, Lehmann W. Retrograde theory in sialolithiasis formation. *Archives of Otolaryngology - Head and Neck Surgery*. 2001; **127**: 66-68.
11. Pietz DM, Bach DE. Submandibular sialolithiasis. *General Dentistry*. 1987; **35**: 494-496.
12. Siddiqui S J. Sialolithiasis: an unusually large submandibular salivary stone. *British Dental Journal*. 2002; **193**: 89-91.
13. Ali Iqbal, Anup K. Gupta, Subodh S. Natu, Atul K. Gupta. Case Report - Surgical Pathology. *Annals of Maxillofacial Surgery*. 2012; **2**: 70-73
14. Ledesma-Montes C, Garces-Ortiz M, Salcido-Garcia JF, Hernandez- Flores F, Hernandez-Guerrero JC. Giant sialolith: Case report and review of the literature. *Journal of Oral and Maxillofacial Surgery*. 2007; **65**: 128-130.
15. Oteri G, Procopio RM, Cicciù M. Report of two cases: Giant Salivary Gland Calculi (GSGC). *The Open Dentistry Journal*. 2011; **5**: 90-95.
16. McGurk M, Escudier MP, Brown JE. Modern management of salivary calculi. *British Journal of Surgery*. 2005; **92**: 107-12.