

Research Article

Open Access

Surgical Treatment of Fracture Base of Fifth Metatarsal in Adults

Fathey Ragab Mostafa*

Department of Orthopedic Surgery, Al-Azhar University, Cairo, Egypt

Abstract

Fractures of the fifth metatarsal present a unique set of challenges for treatment to the foot and ankle specialist. Understanding the local anatomy, vascular supply, function, and dynamic stresses placed upon the bone, as well as fracture classifications, mechanisms of injury, and expected responses to treatment aid immensely in the decision-making processes. This paper provides a critical review of the current literature with the author's preferred method of treatment of these injuries to provide the orthopaedic surgeon with a basis for treatment of these injuries based on the most recent literature. We tried to link theoretical information with our clinical skills in twenty patients having fracture base of fifth metatarsal in variable ages classification and mechanism of injury.

Keywords: Fracture; Metatarsal bone; Tuberosity; Injury

Introduction

The fifth metatarsal base fracture is very common which have a greater incidence in males in their third decade and females in their seventh decade, with a greater prevalence in women with low bone mineral density [1]. Stress fracture of the fifth metatarsal bone is a common injury in athletes [2]. Despite their incidence and associated risk of significant disability metatarsal fractures have received little attention in the literatures. Use of the term "Jones fracture" to describe all such injuries in orthopaedic literature and among treating physicians has added confusion to the topic.

Aim of the Work

To evaluate the results of recent surgical treatment of fracture base of fifth metatarsal in adults

Anatomy

The fifth metatarsal is a long bone consisting of a head, neck, shaft, base and tuberosity or styloid process. The metaphyseal base tapers distally to the more tubular diaphysis which, besides being more convex dorsally, is actually wider in cross-section from medial to lateral than it is from dorsal to plantar. Also, the diaphyseal cortices tend to be thinner on the dorsal and plantar sides than on the medial and lateral sides. The bone often bows laterally [3,4].

There are significant considerations when planning intramedullary screw placement:

- The tuberosity protrudes Laterally and plantar ward from the base [5]
- Proximal articulations of the fifth metatarsal are with the cuboid bone and adjacent base of the fourth metatarsal.
- The insertion of the peroneus tertius tendon more distally onto the dorsal base of the fifth metatarsal is thought to have minimal influence as a fracture force (Figures 1 and 2).
- Sturdy ligaments both dorsally and plantar connect the cuboid to the base of the fifth metatarsal as well as to the base of the fourth metatarsal.

The 2 adjacent bases are also connected by ligaments. The long plantar ligament extends from the distal calcaneus across the cuboid and inserts into the base of the fifth metatarsal, while superficially, the lateral band of the plantar fascia sends a slip into the plantar tuberosity. It has been suggested to be more responsible for tuberosity, fractures than the more prominent dorsal insertion of the peroneus brevis tendon into the tuberosity [6,7].

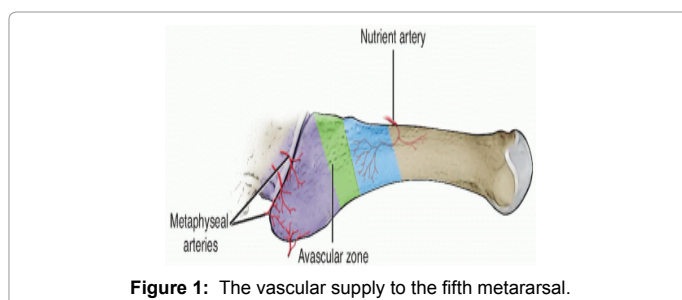


Figure 1: The vascular supply to the fifth metatarsal.

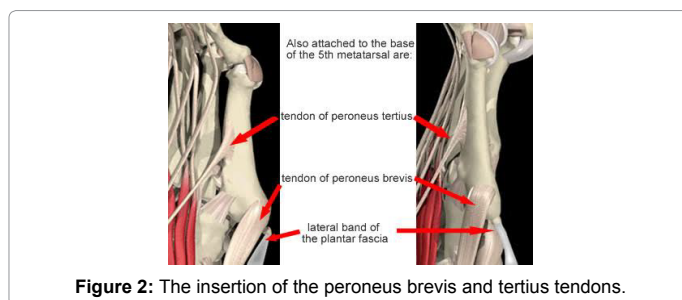


Figure 2: The insertion of the peroneus brevis and tertius tendons.

Literature Review

Stability

Dorsal and plantar cuboideometatarsal, intermetatarsal, and capsular ligaments; the short peroneal muscle (SPM) tendon; and the plantar aponeurosis (PAL) provide stability to the lateral Lisfranc complex (i.e., tarsometatarsal joint)

Blood supply

Two studies have investigated the vascular supply to the fifth metatarsal [8,9]. The tuberosity is well supplied by from numerous

***Corresponding author:** Fathey Ragab Mostafa, Department of Orthopedic Surgery, Al-Azhar University, Cairo, Egypt, Tel: +20 102 722 7142; E-mail: mostafaragab948@gmail.com

Received January 02, 2018; **Accepted** January 16, 2018; **Published** January 22, 2018

Citation: Mostafa FR (2018) Surgical Treatment of Fracture Base of Fifth Metatarsal in Adults. J Clin Case Rep 8: 1078. doi: [10.4172/2165-7920.10001078](https://doi.org/10.4172/2165-7920.10001078)

Copyright: © 2018 Mostafa FR. This is an open-access article distributed under the terms of the Creative Commons Attribution License, which permits unrestricted use, distribution, and reproduction in any medium, provided the original author and source are credited.

random vessels that are directed from the metaphysis. There is a nutrient artery supplying the diaphysis but the proximal diaphyseal region contains a watershed “no man’s land” where there is a run-out of the nutrient artery before the metaphyseal vessels are encountered. This area of poor vascular supply is thought to be the etiology of delayed union or non-union of fractures in this area, especially if the nutrient artery is disrupted [10] (Figure 1).

Mechanism of injury

Biomechanically, the fifth metatarsal functions with an independent axis of motion that allows primarily dorsiflexion and plantarflexion with inversion-eversion as potential movements as well. Strong soft tissue attachments that contain the base stabilize it against acute and repetitive force attacks. Excessive acute and repetitive strain loads on the bone are usually flexural, whereas torque can occur with inversion injuries.

- Foot plantarflexion with an addition force applied to the forefoot is the source of most acute injuries to the base of the fifth metatarsal whether it causes a tuberosity fracture or Jones fracture or even a cervical fracture. Hence, these injuries are often encountered in such sports as basketball, football, soccer and tennis as well as dancing and gymnastics. They are also seen in the general population as the result of sudden inversion injuries such as slipping while going down stairs or stepping over an edge. The locking configuration of all the soft tissue constraints about the base make.

- Dislocation of the fifth metatarsal-cuboid joint an exceedingly rare occurrence.

- Stress fractures, which usually disrupt the proximal diaphysis, are the result of repeated submaximal distraction forces. One biomechanical study revealed that the peak stress point occurs approximately 3.38 to 4.05 centimetres distal to the tuberosity when the load is directed 30 to 60 degrees from the horizontal plane relative to the long axis of the metatarsal.”

Diagnosis

Clinically

The patient with a fracture at the base of the 5th metatarsal reports sudden onset of pain in the area after torsional injury of the foot. Local edema and hematoma may be observed. Exceptions are the fatigue fractures of zone 3, where a dull pain may be present for days or even weeks before the appearance of the fracture. They are usually observed in athletes and are prone to delayed union [11-14].

Radiography is performed on almost all patients to rule out a fracture. However, only 15-20% of patients have a clinically significant fracture (15) In other words, radiography is not necessary for most of these patients. Various clinical decision rules have been introduced to pick up the patients with fracture, therefore to reduce the number of unnecessary radiographic examination in this segment of patients up to date [15-21].

Ottawa ankle rules

(OAR) is the most popular and widely accepted clinical guideline to help the physician as to decision making regarding need for x-ray examination after ankle and mid-foot injury. It was first developed in 1992 by Steill et al. [14-25] Since its introduction, several studies all around the world validated the OAR [16-18,21]. The use of the rules has been shown to have nearly 100% sensitivity for ankle and mid-foot fractures and has reduced the need for radiographic examinations.

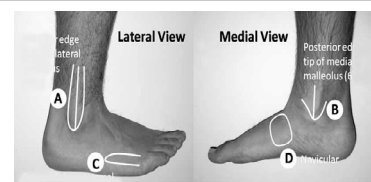


Figure 3: the application of OTTAWA ankle rules on patient.

The most important problem with this guideline, however, is its low specificity [22,23]. Concerns about increasing the specificity enforced the innovation of modifications of OAR or new guidelines [24]. Recently, Egli et al. [17] described a new indirect examination stest called Bernese Ankle Rules (BAR) that is proposed to have better specificity than OAR. 44-55-66-PM, a mnemonic that improves retention of the Ottawa Ankle and Foot Rules.

An ankle x-ray series is only required if [25]. There is any pain in the malleolar zone and any of these findings (Figure 3)

1. bone tenderness at A
- OR
2. bone tenderness at B
- OR
3. inability to take 4 complete steps both immediately and in ED

A foot x-ray series is only required if there is any pain in the midfoot zone and any of these findings:

1. bone tenderness at C
- OR
2. bone tenderness at D
- OR
3. inability to take 4 complete steps both immediately and in ED

Recommendations

Apply the ottawa ankle rules accurately:

1. Palpate the entire distal 6 cm of the fibula and tibia
2. Do not neglect the importance of medial malleolar tenderness
3. Do not use for patients under age 18

Clinical judgement should prevail over the rules if the patient:

1. Is intoxicated or uncooperative
2. Has other distracting painful injuries
3. Has diminished sensation in the legs
4. Has gross swelling which prevents palpation of malleolar bone tenderness

Give written instructions and encourage follow-up in 5 to 7 days if pain and ability to walk are not better.

Bernese ankle rules

If any of these clinical examination causes pain, the diagnosis is acute fracture and radiographic examination is required (Ankle radiographs for a and b, foot radiographs for c) (Figure 4).

(a) **Indirect:** Fibular stress. The malleolar fork is compressed

approximately 10 cm proximally to the fibular tip, avoiding direct palpation of the injured region.

(b) Direct medial malleolar stress: The thumb is pressed flatly on the medial malleolus

(c) Compression Stress of the midfoot and hindfoot: One hand fixes the calcaneus in neutral position and the other hand applies a sagittal load on the forefoot, so that the midfoot and hindfoot are compressed.

Imaging

X-ray

Views: This includes three standard views: the antero-posterior (AP), lateral and oblique views. However, some avulsion fractures at the tip of the tuberosity may not be recognised in these standard views. additional AP view of the ankle including the base of the proximal fifth metatarsal should be obtained if clinical findings are suggestive of a fracture.

Nuclear Imaging

Bone scanning is performed with the use of technetium-99 m (^{99m}Tc) methylene diphosphonate. Vascular flow and delayed images are obtained. Fractures become evident on bone scans before they become evident on radiographs. Acute fractures are seen as foci of increased uptake in the affected bone. However, scintigraphy is not routinely indicated for the diagnosis of acute fractures. This study is performed if the clinical findings suggest a fracture but the plain radiographs are negative. Bone scanning is highly sensitive; its sensitivity is surpassed only by that of MRI in certain instances. For instance, MRI and CT scanning are more sensitive than bone scanning for evaluating stress fractures, because MRI and CT scanning can depict bone marrow edema. Bone scanning, however, is not specific. Hence, its results should not be reported in isolation. A hot spot may be seen in fractures, degenerative areas, or neoplasms. Nuclear medicine images must be correlated with plain radiographs.

Ultrasound

Using ultrasound in early diagnosis and follow up of metatarsal bone stress fractures. The article by Banal et al demonstrated evidence about the potential for diagnostic musculoskeletal ultrasonography in laboratory investigations of metatarsal stress fractures. It was

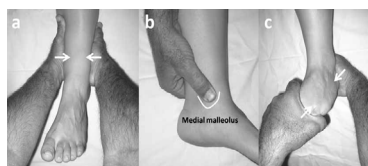


Figure 4: Bernese ankle rules.

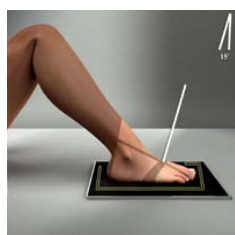


Figure 5: Position of the patient in AP view.

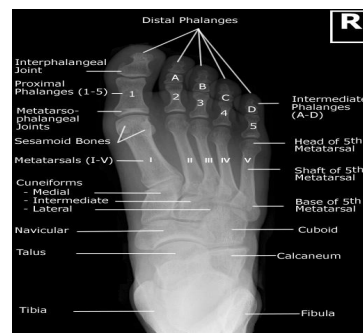


Figure 6: Normal X-ray of AP view.

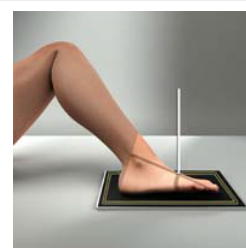


Figure 7: Position of the patient in (Medial Rotation).

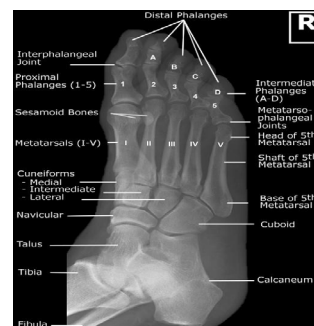


Figure 8: Normal x ray of AP oblique (Medial Rotation).

noted that there were no false-positives for stress fracture when “cortical thickening” was observed on ultrasound [26] (Figure 5) [27]. Currently, because of its low cost and high specificity (94%), plain film radiography is initially used when there is clinical suspicion of a stress fracture detection (10%-20%). Magnetic resonance imaging (MRI) or skeletal scintigraphy, because of their high sensitivities (63%-100% for MRI and 74%-100% for skeletal scintigraphy), are therefore typically required for further diagnostic workup [27]. More recently, ultrasonography (US) has been proposed as a reasonable follow-up to negative plain film radiographic results in the workup of a suspected stress fracture; and US criteria have been established that are consistent with and diagnostic of stress fractures [26].

Magnetic Resonance Imaging (MRI)

Although MRI is sensitive for the diagnosis of fractures, it is not required, because plain radiographic findings are fairly sensitive and specific. MRI is useful in the assessment of fractures and dislocations, soft tissue, the plantar plate, structures of the capsule, the extent of marrow hyperemia, the exact number of bones involved, and small chip fractures. MRI is more sensitive than radiography and even scintigraphy in the early diagnosis of stress fractures, because it shows

bone marrow edema exquisitely. MRI may be used to differentiate stress fractures from early degenerative changes and early stress fractures from synovitis (Figures 6-9).

MRI scans of the foot should include T1-weighted, T2-weighted, and short-tau inversion recovery (STIR) images in the axial, sagittal, and coronal planes.

The fracture line is visualized as a linear hypointensity in T1- and T2-weighted images, whereas STIR images may show hyperintensity. Edema of the bone has low signal intensity on T1-weighted images and high signal intensity on T2-weighted images. Soft-tissue swelling, ligamentous injuries, and plantar-plate injuries are better visualized with MRI than with other modalities [28] (Figures 10-12). According to Logan and Makwana [28]:

- Type I fracture occurred at the junction of the extra-articular and intra-articular part of the tuberosity.
- Type II fracture occurred at the proximal fourth and fifth metatarsal joint.
- Type III at the distal fourth and fifth metatarsal joint
- Type IV distal to this in the diaphysis.

Some fractures had two or three fracture lines, and these were classified as a group e.g. Types I/II when the fracture line traversed zones I and II (Figure 13).

Mehlhorn et al. [29] proposed another classification for base of fifth metatarsal fractures based on radiomorphometric analysis reflecting the risk for secondary displacement. In this classification the joint surface of the fifth metatarsal base is divided into three equal parts. Type I, type II, and type III fractures represent the lateral third, middle third, and medial third respectively (Figure 14). Adding to this classification they introduced an A type which represents no relevant displacement and a B type which denotes a fracture step off of greater or equal to two millimetres [30].

Treatment

The optimal treatment of fifth metatarsal fractures is a topic of great debate. Jones Fractures: These represent fractures at the metaphyseal-diaphyseal junction and have the propensity to become non-unions. The blood supply in this area of the 5th metatarsal is tenuous and represents a watershed area. As such, non-union of Jones fractures can occur. There are some proponents that suggest immediate ORIF, which is often advocated in high performance athletes. Jones fractures, however, can be managed by closed means with a short leg non-weight bearing cast for 6 weeks followed by another 4-6 weeks of progressive weight bearing. If during serial radiographic follow-up there are no visible signs of bony healing by about 6 weeks, AND the patient has persistent pain in the fractured site, then ORIF is recommended.

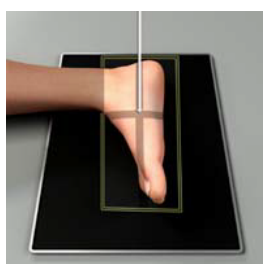


Figure 9: Position of the patient in lateral view.

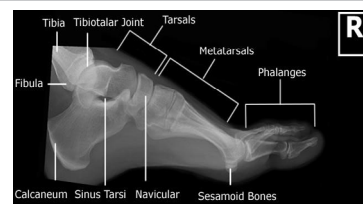


Figure 10: Normal X-ray in lateral view.

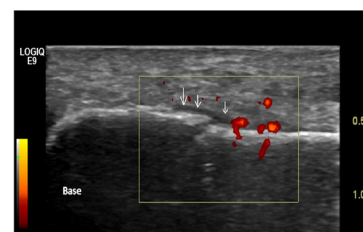

Figure 11: Initial ultrasound to detect fracture the base of fifth metatarsal. Note the cortical break, periosteal elevation (arrows) with adjacent hypoechoic area, and hyperemia observed on color Doppler. There is an absence of callus formation and soft tissue swelling. Orientation with respect to the metatarsal base is also provided.

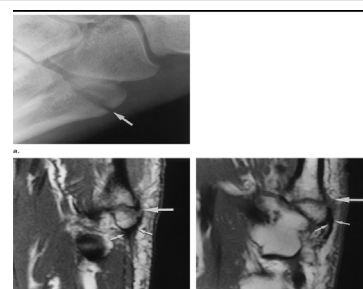


Figure 12: Images (X-ray and MRI) obtained in a 42-year-old man with an acute fracture of the tuberosity of the fifth metatarsal bone. (a) Lateral radiograph of the foot shows the fracture (arrow) traversing the proximal portion of the fifth metatarsal bone. (b) Transverse T1-weighted spin-echo MR image shows the fracture (large arrow) and the PAL (small arrows) attached to the avulsed fragment. (c) Transverse T1-weighted spin-echo MR image obtained at a level approximately 16 mm superior to b shows the fracture (large arrow) and the SPM tendon (small arrows) inserting into the lateral aspect of the tuberosity.

Postoperatively, the patient is immobilized for 4-6 weeks in a short leg splint or short leg cast, and then requires another 4-6 weeks of progressive weight bearing and physical therapy until full weight bearing with a regular shoe is possible. Return to sedentary desk work can occur as early as 2-4 weeks after initial surgery.

Base of the 5th Avulsion Fractures: These represent an avulsion fracture from the lateral tarsal metatarsal ligament pulling on the base of the 5th metatarsal. Most often these are stable injuries and can be treated in a weight bearing short leg cast, CAM walker, or postoperative shoe for 4-6 weeks with return to modified duty once the patients comfort allowed.

Significantly displaced and rotated fractures represent significant intra-articular injuries and should be reduced. If the reduction is not stable via closed means, then ORIF should be performed. Postoperatively, the patient is immobilized for 4-6 weeks in a short leg splint or short leg cast, and then requires another 4-6 weeks of progressive weight bearing and physical therapy until full weight bearing with a regular shoe is possible. Return to sedentary desk work can occur as early as 2-4 weeks after initial surgery [31,32].

Cannulated screw versus solid screw

The choice between use of a cannulated screw or a solid screw is point of controversy among surgeons [33-35].

AO principles

In 1958, the AO formulated four basic principles, which have become the guidelines for internal fixation [36]. Those principles, as applied to the 4.0 mm cannulated screw, are:

Anatomic reduction: A guide wire marks the prescribed path for the cannulated screw and secures alignment of the fragments while the screw is being inserted. The cannulated screw is inserted over the wire.

Stable fixation: Cannulated screws provide compression and absolute stability across the fracture. The screws are available in different threads lengths, allowing the surgeon to optimize purchase in the far fragment for maximum compression and stability. A cannulated screw fits over a previously placed guide pin, which has been shown to provide higher resistance to stress than a solid screw.

Preservation of blood supply: The use of small diameter guide wires allows precise placement of cannulated screws through small

incisions. This technique minimizes disruption of soft tissue and preserves vascular blood flow for bone healing.

Early, active mobilization: Cannulated screws, combined with AO technique, provide stable fracture fixation with minimal trauma to vascular supply. This helps to create an improved environment for bone healing, accelerating the patient's return to previous mobility and function.

Instruments

1. 4.0 mm cannulated screws
2. 1.25-mm threaded guide wire, 150 mm maintains reduction during drilling. Threaded spade point tip allows easy penetration into the bone and maximum resistance to inadvertent removal.
1. 2.7 mm cannulated drill bit, 160 mm, 1.35 mm cannulation, quick coupling
2. 2.7 mm/1.25 mm double drill sleeve protects soft tissue during guide wire placement and drilling.
1. Cannulated hexagonal screwdriver, 2.5 mm hex fully cannulated for insertion of any 4.0 mm cannulated screw over the guide wire.
2. Cannulated screw measuring device provides a direct reading for screw length. Measurement places screw tip at thread/shaft junction of guide wire.

Material and Methods

Twenty adult patients with fracture base of fifth metatarsal were selected from the emergency department of the university hospital of Faculty of Medicine (Damietta) Al Azhar University. From July 2016 to June 2017 and were fixed operatively by cannulated cancellous 4-mm screw

Demographic features

1. Sex incidence: There were 12 males and 8 females (Figure 15)
2. Sex: male and female.
3. Closed fractures.

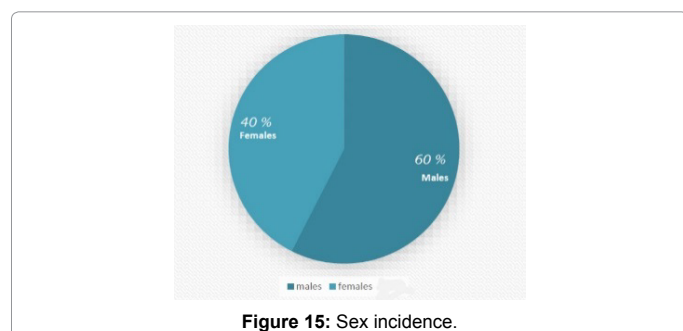
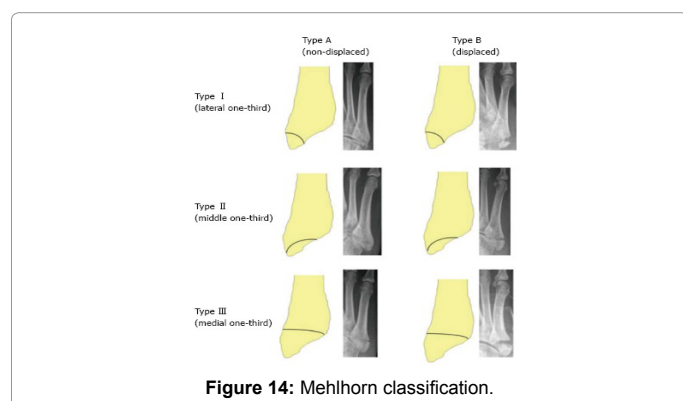
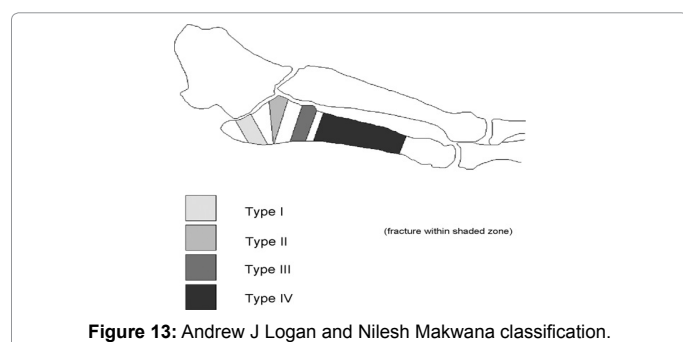
Exclusion criteria

1. Age <18 >60 years.
2. Open fractures.
3. Pathological fracture.
4. Skeletal immaturity
5. Diabetic patients
6. Patient evaluation
7. Patients history: Clinical history was taken from the patient in the sort of name, sex, age, job, address and smoking habits.
8. Associated illness like diabetes, hypertension and cardiac condition.
9. Patients were asked about the mechanism of injury and if there is any associated injuries.

Clinical examination

Standard foot examination was performed in the form of:

1. Tenderness



2. Swelling
3. Range of motion of ankle
4. Skin condition
5. Neurovascular examination and examination for associated injuries was performed.

Radiological evaluation

All patients were evaluated by plain X-rays: 1-AP., oblique and lateral views of the foot and 2-AP. view of the ankle. Preoperative imaging was used to classify the patient's fractures and to plan surgery.

Fitness to Surgery

The patients were assessed for fitness for surgery by clinical history, examination and routine preoperative laboratory investigation.

Implants

1 cannulated screw 4.00 mm with or without a washer was placed percutaneously under image intensifier perpendicular to fracture line, the length of the screw ranged from 45 mm to 60 mm.

Surgical technique:

- **Anesthesia:** All the patients were anaesthetized by spinal Anaesthesia
- **Position:** Patients were operated on a standard radiolucent orthopaedic table, in supine position under image intensifier guidance (Figure 16) The patient was placed supine with the affected foot resting over the image intensifier. This arrangement helped us obtain the anteroposterior, lateral and oblique views of the foot with great ease and it allowed easy access to the base of the fifth metatarsal bone. A

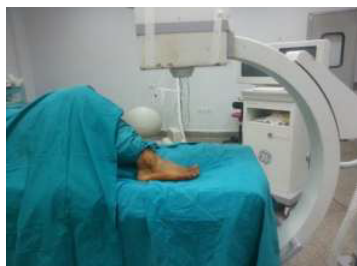

Figure 16: Position of the patient on the operating table. The patient was placed supine with the affected foot resting over the image intensifier. This arrangement helped us obtain the anteroposterior, lateral and oblique views of the foot with great ease.

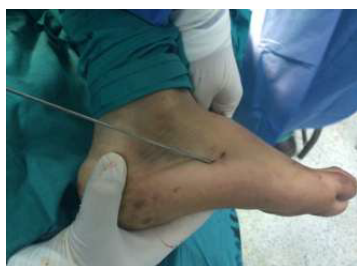

Figure 17: Guide pin insertion. After the guide pin is inserted, its position is checked under the image intensifier, we take several images as AP, LAT, and oblique, to be sure the pin is in that the intra medullary canal of the fifth metatarsal.

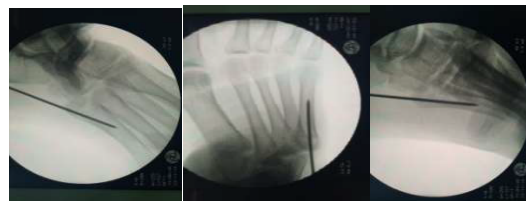

Figure 18: Arm images for the intramedullary guide pin : (a) oblique image of the foot showing the guide pin entering from the tip of the 5th metatarsal. (b) AP. Image of the foot showing the guide pin central in the canal. (c) LAT. Image of the foot.

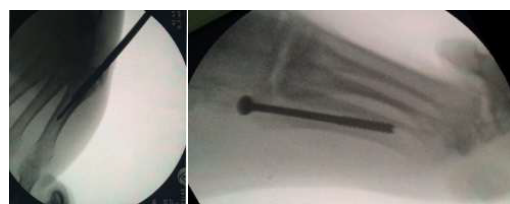

Figure 19: (a)drilling of the intramedullary canal. (b)screw in the intramedullary canal.

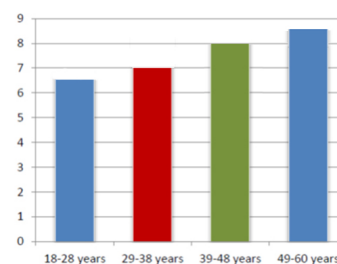


Figure 20: Graph showing time to union in weeks in operative management.

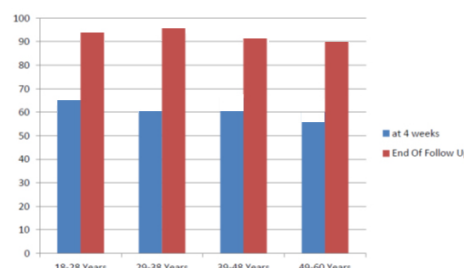


Figure 21: Graph showing AOFAS score in different age groups in operative management.

tourniquet was not applied. A stab incision about 0.5 to 1 cm proximal to the base of the fifth metatarsal bone. After the incision, a 4.0 mm cannulated screw guide pin was inserted into the space between the plantar fascia and the peroneus brevis tendon under image guidance. After the guide pin is inserted, its position is checked under the image intensifier, we take several images as AP, LAT, and oblique, to be sure the pin is in that the intra medullary canal of the fifth metatarsal (Figures 17-21). A cannulated drill was used to drill across the intramedullary canal of the fifth metatarsal. A partially threaded, 4.0 mm, cannulated screw was then inserted under image guidance over the guide pin to ensure intramedullary placement of the screw (Figure 19).

Each 4.0 mm screw had 16 mm threads, regardless of the overall length of the screw used. The guide pin was removed after placement of

the intramedullary screw. Care was taken to ensure the intramedullary position, and that all the threads were distal to the fracture site. Closure of the wound with a single stitch. We followed up all the patients for postoperative pain, function, footwear requirement, walking distance, gait abnormality, alignment. The patient remains in the hospital overnight, and prophylactic parenteral antibiotics are administered for the first 24 hours postoperatively. The American Orthopaedic Foot and Ankle Society (AOFAS): used as clinical rating system to monitor improvement following injury.

Results

We followed up all the patients for pain, function, footwear requirement, walking distance, gait abnormality, alignment and radiological assessment for union. The sample size was 20 patients, all patients achieved full union, 1 patient was complicated by superficial infection treated by antibiotics. Tables 1-4 shows high incidence among patients aged 18 to 28 years and less incidence in age group 49 to 60 years. The time of union was correlated with the time of return to normal activity, painless movement of the foot and radiological assessment, Patients achieved union ranging from six to nine weeks, average seven weeks (Figure 20).

Discussion

Fractures of the proximal fifth metatarsal specially at the junction of diaphysis and metaphysis present difficulty in treatment. Sir Robert Jones originally described the fracture in 1902 when he reported 4 cases, including his own [3]. In 1927 Carp noted the difficulty in achieving union of proximal fifth metatarsal fractures [37]. A review of literature reveals considerable variability in the results obtained with

Age in years	Number of patient
18 -28	8
29 - 38	6
39 - 48	5
49 - 60	1

Table 1: Patients in groups according to age.

Stewart	Dameron	Torg
Type I - Extra-articular fracture between the metatarsal base and diaphysis	Zone 1 – Tuberosity avulsion	Type I – Acute – Narrow fracture line with no intramedullary sclerosis
Type II - Intra-articular fracture of the metatarsal base	Zone 2 – Metaphyseal – Diaphyseal junction	Type II – Delayed Union – Widened fracture gap and intramedullary sclerosis
Type III - Avulsion fracture of the base	Zone 3 – Proximal diaphyseal stress Fracture	Type III – Nonunion – Obliteration of the medullary canal
Type IV - Comminuted fracture with intra-articular extension	-	-
Type V - Partial avulsion of the metatarsal base with or without a fracture	-	-

Table 2: Classification.

Age in years	Time of union in Each group in weeks
18-28	6.5
29-38	7
39-48	8
49-60	8.5

Table 3: Results of different groups regarding time to union.

Parameters	Points
Pain	40
No pain	40
Mild, occasional	30
Moderate, daily	20
Severe, almost always present	0
Function	45 points
Activity limitations, support	-
No limitations, no support	10
No limitations of daily activities, limitation of recreational activities, no support	7
Limitation of daily and recreational activities, cane	4
Severe limitation of daily activities and recreational activities, walker crutches, wheelchair	0
Footwear requirements	
Fashionable, conventional shoes, no insert required	5
Comfort footwear, shoe insert	3
Modified shoes, brace	0
Maximum walking distance	
>600 meter	10
400-600 meter	7
100-300 meter	4
<100 meter	0
Walking surface	
No difficulty on any surface	10
Some difficulty on uneven terrain, stairs, inclines, ladders	5
Severe difficulty on uneven terrain, stairs, inclines, ladders	0
Gait abnormality	
None, slight	10
Obvious	5
Marked	0
Alignment	
Good, plantigrade foot, midfoot well aligned	15 points
Fair, plantigrade foot, some degree of midfoot malalignment observed, no symptoms	8
Poor, non-plantigrade foot, severe malalignment, symptoms.	0
Evaluation	
Final evaluation	100 points
Excellent	Patient points
Good	>80 points
Poor	60-80 points
	<60 points

Table 4: AOFAS score midfoot scale (100 points total).

nonoperative treatment. The main goal of this study was to evaluate the results of recent surgical treatment of fracture base of fifth metatarsal in adults Early screw fixation can be strongly recommended in those who want to return to normal activity earlier. Our patient population was an active group ranging from (18-58) years. Patients in all age groups were productive and active. We used radiographic classification of Dameron, Lawrence and Quill (Table 2). The surgical group resulted in treatment success with average clinical union 7.5 weeks in operative groups we applied below knee slab and sometimes below knee walking cast to encourage the patient to early weight bearing. The minimum follow up was 2 months and maximum 6 months. Operative groups showed union in all patients with one patient with superficial infection treated by oral antibiotics. Mologn et al. which is comparable with our study, studied 37 Jones fracture mean follow up 25.3 months (range, 15-42 months). Eight of 18 (44%) in cast group were considered treatment failures: 5 non-union, 1 delayed union, and 2 refractures. One of 19 patients in the surgery group was considered a treatment failure. For the surgery group, the median time to union and return to sports was

7.5 weeks, respectively (Table 3). For the cast group, the median time 14.5. The Mann-Whitney test showed statistically significant difference between the groups in both parameters, with $P < 0.001$. This agrees of the findings of Adhikari et al. [37] who studied 31 Jones fracture. Mean follow up was 12 months (ranges 6-18 months). Six out of 16 patients (37.5%) in the cast group were considered treatment failure (3 non-union, 3 delayed union.). All patients who underwent surgery were considered treatment success with some minor complications. In surgery group, the median time to clinical union and return to normal activity were 8 week and 9 weeks respectively; whereas in cast group, the median times to clinical union and return to normal activity was 14 weeks respectively.

Roch and Cladder [38]. Published a systematic review of twenty-six studies of which 22 were level (4) evidence, with one randomized control trial. Return to sport activity after intra-medullary screw fixation for acute fracture ranged from 4 to 18 weeks. The non-operative group had a union of 76% (pooled), whereas the fracture treated operatively with intra medullary screw fixation had a union of 96% (pooled). Delayed unions treated non-operatively had a union rate of 44% and 97% in treated operatively group. Non-unions treated with screw fixation healed 97% cases.

Vivek et al. [39] reported 23 patients healed following bicortical fixation with mean 6.3 weeks (4-10) average, prone to complications with conservative management. there average AOFAS score (Table 4) was 94, they remove the implant after an average 23 weeks later, which is comparable with our results and improves that intramedullary screw fixation is better as it needs no removal.

Marta et al. [40] reported 11 male and 6 females with type II and III Jones fractures fixed with 4.0 mm cannulated compression screw, had a mean healing after surgery 7.3, 7.5 weeks respectively and all returned to previous levels of activity no reports of delay union, non-union or refracture, which agrees with our study.

Summary

Metatarsal fractures are Common injuries of the foot frequently seen in emergency departments. The base of the Fifth metatarsal is the commonest one. Classifications of these fractures are based on anatomical region, patient history and radiological findings. Depending on these classifications and patient's activity level, treatment can be conservative or operative. There has been rising concern to treat this injury operatively especially in fifth metatarsal injuries. Twenty patients were selected from Damietta teaching hospital of Faculty of Medicine (Damietta) Al-Azhar University from July 2016 to June 2017, Radiographs were assessed for displacement and Dameron, Lawrence and Quill classification was used to determine type of fracture. These Twenty patients underwent operative management in the sort of percutaneous fixation by cannulated screw. The operative group patients ages ranged from 18-59 years. We used slab until soft tissue healing and sometimes we used walking cast to encourage walking

The patients in the operative groups were instructed to begin immediate weight bearing with crutches as tolerated on the healthy side for 4 weeks, if no displacement, patient will continue to partial then full weight bearing with no aid on the affected side. We followed up the patients with X-rays to follow up the union and by AOFAS score to evaluate the function (Table 4). The surgical groups patients all achieve union with average clinical union 7.5 weeks. The limitation of our study is the short follow up of the patients to study the refracture incidence in all groups, limited number of patients with jones type III.

Complication faced in this study were

1. Lack of compliance of the patients especially in the cast or slap when instructed not to weight bear, patients came in the follow up with torn castor slap from the planter aspect denoting early weight bearing.
2. Care of foot hygiene of the patients to prevent infection.

Recommendation is that early surgical treatment results in quicker clinical union and allows patients to return to normal activities and daily activities than the cast treatment. The complication in the Operative group was one patient with superficial infection treated by oral antibiotics.

Conclusion

We recommend early screw fixation in the treatment of acute proximal fifth metatarsal fracture in patients with high demand physical activity who want to return early to their work, but also, we have to take in consideration the financial cost of the operation versus the cast application.

References

1. Kane JM, Sandrowski K, Saffel H, Albanese A, Raikin SM, et al. (2015) The epidemiology of fifth metatarsal fracture. *Foot Ankle Spec* 354-359.
2. Giske A, Erik AR (2010) Fracture of the base of the fifth metatarsal in athletes treated with intramedullary AO cancellous screw fixation. *Troms*.
3. Jones RI (1902) Fracture of the base of the fifth metatarsal bone by indirect violence. *Ann Surg* 35: 697-700.
4. Ebraheim NA, Haman SP, Jike Lu BA, Padanilam TG (2000) Anatomical and radiological considerations of the fifth metatarsal bone. *Foot Ankle Intl* 21: 212-215.
5. Dameron TB (1975) Fractures and anatomical variations of the proximal portion of the fifth metatarsal. *Bone Joint Surg Am* 57: 788-792.
6. Richli WR, Rosenthal DI (1984) Avulsion fracture of the fifth metatarsal: experimental study of pathomechanics. *Am J Roentgenol* 143: 889-891.
7. Theodorou DJ, Theodorou SJ, Kikitsubata Y, Botte MJ, Resnick D (2003) Fractures of the proximal fifth metatarsal bone: anatomic and imaging evidence of pathogenesis of avulsion of the plantar aponeurosis and the short peroneal tendon. *Radiology* 226: 857-865.
8. Shereff MJ, Yang QM, Kummer FJ, Frey CC, Greenidge N (1991) Vascular anatomy of the fifth metatarsal. *Foot Ankle* 11: 350-353.
9. Smith JXr, Amoczky SP, Hersh A (1992) The intraosseous blood supply of the fifth metatarsal. Implications for proximal fracture healing. *Foot Ankle* 13: 143-152.
10. Arangio GA, Xiao D, Salathe EP (1997) Biomechanical study of stress in the fifth metatarsal. *Clin Biomech* 12: 160.
11. Dameron TB (1995) Fractures of the proximal fifth metatarsal: Selecting the best treatment option. *J Am Acad Orthop Surg* 3: 110-114.
12. Lawrence SJ, Botte MJ (1993) Jones' fractures and related fractures of the proximal fifth metatarsal. *Foot Ankle* 14: 358-365.
13. Sanders RT (1999) Fractures of the hindfoot and forefoot, in surgery of the foot and ankle, Coughlin MJ and Mann RA (7th edn) 1574-1605.
14. Stiell IG, Greenberg GH, McKnight RD, Nair RC, McDowell I, et al. (1992) A study to develop clinical decision rules for the use of radiography in acute ankle injuries. *Ann Emerg Med* 21: 384-390.
15. Auleley GR, Kerboull L, Durieux P, Cosquer M, Courpied JP, et al. (1998) Validation of the Ottawa ankle rules in France: a study in the surgical emergency department of a teaching hospital. *Ann Emerg Med* 32: 14-18.
16. Yazdani S, Jahandideh H, Ghofrani H (2006) Validation of the Ottawa Ankle rules in Iran: a prospective survey. *BMC Emerg Med* 6: 3.
17. Eggli S, Scwabas GM, Eggli S, Zimmermann H, Exadaktylos AK (2005) The Bernese ankle rules: a fast, reliable test after low-energy, supination-type malleolar and midfoot trauma. *J Trauma* 59: 1268-1271.
18. Pijnenburg AC, Glas AS, De Roos MA, Bogaard K, Lijmer JG, et al. (2002)

- Radiography in acute ankle injuries: the Ottawa Ankle Rules versus local diagnostic decision rules. *Ann Emerg Med* 39: 599-604.
19. Broomhead A, Stuart P (2003) Validation of the Ottawa Ankle Rules in Australia. *Emerg Med (Fremantle)* 15: 126-132.
 20. Yuen MC, Sim SW, Lam HS, Tung WK (2001) Validation of the Ottawa ankle rules in a Hong Kong ED. *Am J Emerg Med; ankle rules. J Accid Emerg Med* 19: 429-32.
 21. Perry S, Raby N, Grant PT (1999) Prospective survey to verify the Ottawa ankle rules. *J Accid Emerg Med* 16: 258-260.
 22. Bachmann LM, Kolb E, Koller MT, Steurer J, Ter Riet G (2003) Accuracy of Ottawa ankle rules to exclude fractures of the ankle and mid-foot: systematic review. *BMJ* 326: 417.
 23. Dissmann PD (2006) The tuning fork test-a useful tool for improving specificity in "Ottawa positive" patients after ankle inversion injury. *Emerg Med J* 23: 788-790.
 24. Stiell IG (1994) Implementation of the Ottawa Ankle Rules. *JAMA* 271: 827-832.
 25. Banal F, Gandjbakhch F, Foltz V, Goldcher A, Etchepare F, et al. (2009) Sensitivity and specificity of ultrasonography in early diagnosis of metatarsal bone stress fractures: a pilot study of 37. *J Rheumatol* 36: 1715-1719.
 26. Dobrindt O, Hoffmeyer B, Ruf J, Seidensticker M, Steffen IG (2012) MRI versus bone scintigraphy. Evaluation for diagnosis and grading of stress injuries. *Nuklearmedizin* 51: 88-194.
 27. Gregg JM, Schneider T, Marks P (2008) MR imaging and ultrasound of metatarsalgia--the lesser metatarsals. *Radiol Clin North Am.* 46: 1061-1078.
 28. AJ Logan, Dabke H, Finlay D, Makwana N (2007) *Foot and Ankle Surgery* 13: 30-34.
 29. Mehlhorn AT, Zwingmann J, Hirschmüller A, Südkamp NP, Schmal H (2014) Radiographic classification for fractures of the fifth metatarsal base. *Skeletal Radiol* 43: 467-474.
 30. Mologne TS, Lundeen JM, Clapper MF, O'Brien TJ (2005) Early screw fixation versus casting in the treatment of acute Jones fractures. *Am J Sports Med* 33: 970-975.
 31. Mahajan V, Chung HW, Suh JS (2011) Fractures of the proximal fifth metatarsal: percutaneous bicortical fixation. *Clin Orthop Surg* 3: 140-146.
 32. Porter A, Duncan M, Meyer S (2005) Fifth metatarsal Jones fracture fixation with a 4.5-mm cannulated stainless-steel screw in the competitive and recreational athlete: a clinical and radiographic evaluation. *Am J Sports Med* 33: 726-733.
 33. Reese K, Litsky A, Kaeding C, Pedroza A, Shah N (2004) Cannulated screw fixation of Jones fractures: a clinical and biomechanical study. *Am J Sports Med* 32: 1736-1742.
 34. Freshi SA, Vardaxis V, Dodson N (2008) Analysis of compression forces between varying sizes of cannulated screws versus rail external fixation for treatment of Jones type fifth metatarsal fracture. *J Foot Ankle Surg* 47: 295-298.
 35. Massada MM, Pereira MA, de Sousa RJ, Costa PG, Massada JL (2012) Intramedullary screw fixation of proximal fifth metatarsal fractures in athletes. *Acta Ortop Bras* 20: 262-265.
 36. Carp L (1927) Fracture of fifth metatarsal bone with special reference to delayed union. *Ann surg* 86: 302-320.
 37. Adhikari BR, Thakur R, Gurung G (2010) Comparative study of early screw fixation versus cast application on the treatment of acute jones fracture. *Postgraduate Med J NAMS.*
 38. Andrew JR, James DFC (2013) Treatment and return to sport following a jones fracture of the fifth metatarsal: asystematic review. *Knee surg sports trumatol arthrosc.* 21: 1307-1315.
 39. Vivek M, Hyun WG, Jin SS (2011) Fractures of proximal 5th metatarsal percutaneous bicortical fixation. *Clin Orthopedic Surg* 3: 140-143.
 40. Marta M, Maanuel A, Richardo J, Jose L (2012) Intramedullary screw fixation of proximal 5th metatarsal fracture in athletes. *Acta Ortop Bras* 20: 262-265.