

Surgical Treatment of Urgency Urinary Incontinence, OAB (Wet), Mixed Urinary Incontinence, and Total Incontinence by Cervicosacropexy or Vaginosacropexy

Sebastian Ludwig¹, Martin Stumm¹, Elke Neumann¹, Ingrid Becker² and Wolfram Jäger^{1*}

¹Division of Urogynecology and Pelvic Reconstructive Surgery, Department of Obstetrics and Gynecology, University of Cologne, Cologne, Germany

²Institute for Medical Statistics, Informatics and Epidemiology, University of Cologne, Cologne, Germany

*Corresponding author: Wolfram Jäger, MD, PhD, Division of Urogynecology and Pelvic Reconstructive Surgery, Department of Obstetrics and Gynecology, University of Cologne, Kerpenerstr, Köln, Germany, Tel: +49 (0)221 478 97303; Fax: +49 (0)221 478 97304; E-mail: wolframjaeger@gmx.de

Received date: Aug 12, 2016; Accepted date: Sep 27, 2016; Published date: Sep 30, 2016

Copyright: © 2016 Ludwig S, et al. This is an open-access article distributed under the terms of the Creative Commons Attribution License, which permits unrestricted use, distribution, and reproduction in any medium, provided the original author and source are credited.

Abstract

We previously developed a standardized surgical method to replace the uterosacral-ligaments (USLs) in patients with genital prolapse. These cervicosacropexy (CESA) or vaginosacropexy (VASA) operations were effective in treating genital prolapse and urinary incontinence. In this study, we investigated the effects of these operations in combination with a transobturator tape 8/4 procedure (TOT 8/4) for the treatment of urgency urinary incontinence (UUI), overactive bladder (OAB), mixed urinary incontinence (MUI), and total incontinence (TI) in patients without symptomatic prolapse.

Material and Methods: Patients with UUI, OAB, MUI, and TI were eligible for the study and an informed consent was obtained. Patients with genital prolapse POP-Q stage >I were excluded. The USLs in all the patients were replaced by standardized polyvinylidene fluoride structures by CESA/VASA. If patients remained incontinent, they received a TOT 8/4. Main outcome analysis was performed 4 months after the previous surgery. Data were analyzed retrospectively.

Results: 133 patients were operated by CESA (n=57) or VASA (n=76). Subsequently, continence was reestablished in 57 patients (43%). The respective continence rates ranged from 27% (CI [5-49%]) in patients with TI to 73% (CI [54-92%]) in patients with UUI. After 76 patients received an additional TOT 8/4. The overall continence rates were 33% and 86% for patients with TI and those with UUI, respectively.

Conclusion: The results of this study strongly support the hypothesis that urinary continence is based on the anatomical changes of the different levels of the holding apparatus of the bladder.

Keywords: Urgency urinary incontinence; Overactive bladder syndrome; Total incontinence; Mixed urinary incontinence; Uterosacral ligaments; Pubourethral ligaments; Pelvic organ prolapse; Cervicosacropexy; Vaginosacropexy; Transobturator tape

Introduction

There is a close association between genital prolapse and urinary incontinence (UI) [1]. It has been reported that after prolapse surgery a considerable number of patients were cured of their UI. However, it was observed that most patients became incontinent during long-term follow-up after sacrocolpopexy, sacrospinous fixation, and even after vaginal hysterectomy [2-4].

On the basis of these clinical observations, we hypothesized that the standard prolapse operations could not prevent the subsequent development of UI.

All these prolapse operations are performed on levels I or II of the pelvic floor. On the basis of the theory of the anatomical and biomechanical principles of the pelvic floor, cardinal and uterosacral ligaments (USLs) are the most crucial structures of level I [5]. In level

II the paracolpium attaches the vagina laterally to the pelvic walls mainly throughout the endopelvic fascia.

However, the aim of the prolapse surgery is anatomical repair; it removes the uterus, vaginal stump or bladder out of the vaginal cavity and does not prevent or treat UI [6].

Sacrocolpopexy as well as sacrospinous fixation exert their suspending effect unilaterally by either fixating the middle or left side of the vagina. However, USLs are physiological holding structures that attach to the vagina laterally from both sides and not in the middle. From the lateral cervix, they extend bilaterally in a semicircular way along the lateral sides of the small pelvis [5]. Furthermore, sacrocolpopexy or sacrospinous fixation as well as other operations have not defined the minimum or maximum tension that must be achieved to maintain the bladder in its position. Therefore, we decided to consider these observations while developing our new operating procedure.

A crucial aspect in the development of these operations was that the diameters of the bony pelvis are nearly identical in different women [6]. Extensive investigations and MRI studies have revealed that these differences range from a few millimeters in women of different racial groups [7]. According to previous measurements, the vaginal length is

also nearly identical in most patients (own data). Therefore, we hypothesized that the suspension of the vagina and uterus by the respective holding structures must be well-defined and nearly identical in every patient.

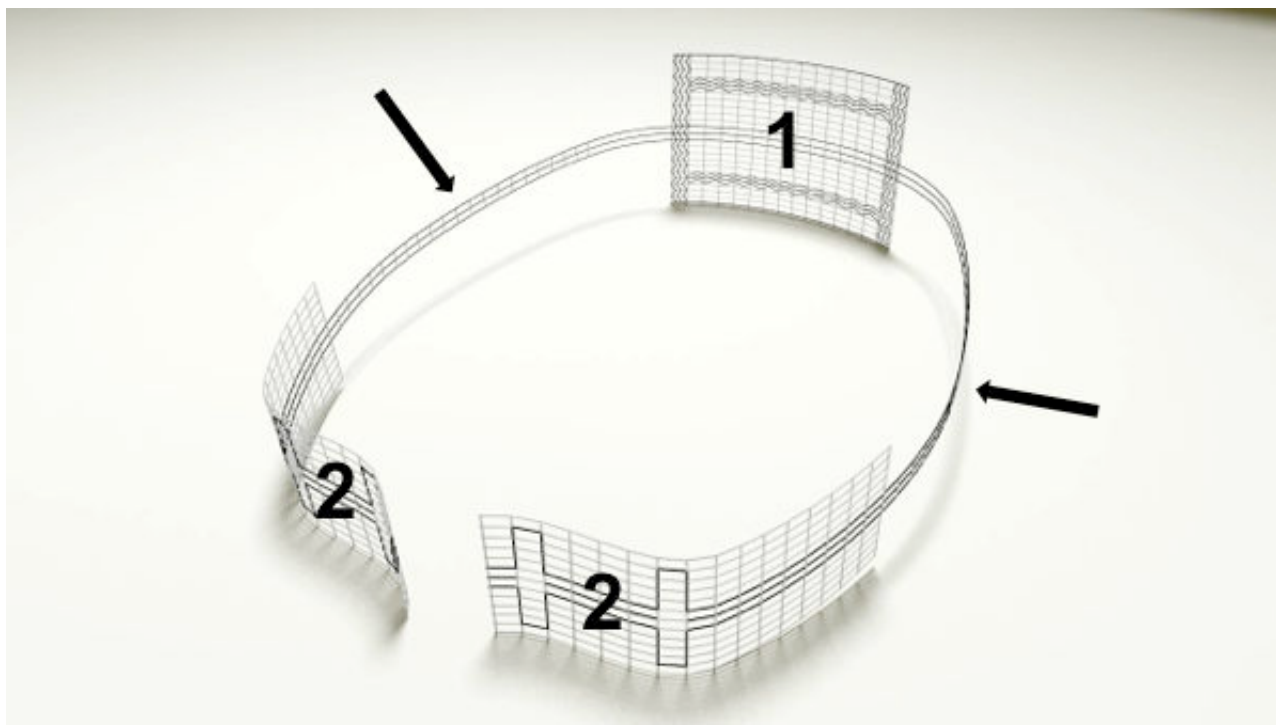


Figure 1: Polyvinylidene fluoride (PVDF) structures for replacement of uterosacral ligaments. Number 1 shows the part of the PVDF structure for fixation (“bridge”) at the cervix (Dynamesh CESA, FEG Textiltechnik mbH, Aachen, Germany). The black arrows depict the parts of the PVDF structure for replacing the left and right uterosacral ligaments (USLs, 8.8 cm in length) in the small pelvis. Number 2 shows the parts of the PVDF structure for fixation at the prevertebral fascia of S1/S2 sacral vertebra on the left and right side of the small pelvis.

Therefore, we developed a procedure by which USLs were replaced in every patient with polyvinylidene fluoride (PVDF) structures of identical length [8]. These structures were sutured to the prevertebral fascial layer in front of S1/S2 sacral vertebra and at the origin of the USL at the cervix or at the edges of the vaginal vault [9,10]. Because cervicosacropexy (CESA) or vaginosacropexy (VASA) are always identically performed in every patient, we classified these operations as “standardized” replacement of the USLs.

Although we expected a stable anatomical suspension, we were surprised that 70% of the patients with genital prolapse and UI were immediately continent after CESA or VASA [6]. Because this procedure was highly effective, several patients wanted to undergo these operations. During the initial phase of this study, we ascertained the concept of reestablishing continence through the bilateral suspension of level I of the pelvic floor [10,11]. Furthermore, we offered an additional TOT level III repair as a second treatment option to those patients who remained incontinent. Level III is the distal part of the vagina where the vaginal wall is directly attached to the surrounding structures without an intervening paracolpium [5].

In this study, we reported the outcome of 133 patients with different types of UI who were treated by CESA or VASA with or without using the TOT 8/4 technique between 2013 and 2015. Because these CESA and VASA operations were highly effective, we developed laparoscopic operations. In this manuscript, we have summarized the outcome of the patients who were operated upon the laparotomy technique.

Methods

In this retrospective observational study, patients diagnosed as having urgency urinary incontinence (UUI), overactive bladder syndrome (OAB wet), mixed urinary incontinence (MUI), and total incontinence (TI) were included. Patients with pure stress urinary incontinence (SUI) and lower urinary tract symptoms (LUTS) were excluded. Urinary incontinence (UI) were based on the subjective complaints and categorized according to the criteria of the International Continence Society (ICS) criteria [12]. Urodynamic studies were not mandatory.

Most of these patients had failed conservative (anticholinergic drugs) treatments. Pelvic organ prolapse (POP) measurements were recorded according to the POP-Q system described by Bump et al. [13]. Exclusion criteria were a previous history of prolapse surgery such as sacrospinous fixation, sacrocolpopexy, colposuspension, TOT/TVT, and vaginal or abdominal mesh implantation. Every patient made a mature decision of giving informed consent before undergoing the surgical treatment. Every patient was informed that after CESA or VASA, an additional TOT 8/4 would be provided in the second surgery. However, this second operation could be avoided when the patients were already continent after CESA or VASA.

Main outcome measure

Main outcome measure was the urinary continence recorded 4 months after each type of surgery. Thus, urinary continence was defined as the total absence of any kind of UI symptoms. To be

categorized as continent or cured, patients must have no UUI symptoms, normal voiding frequency, and no spontaneous loss of urine. Patients with TI were able to retain urine.

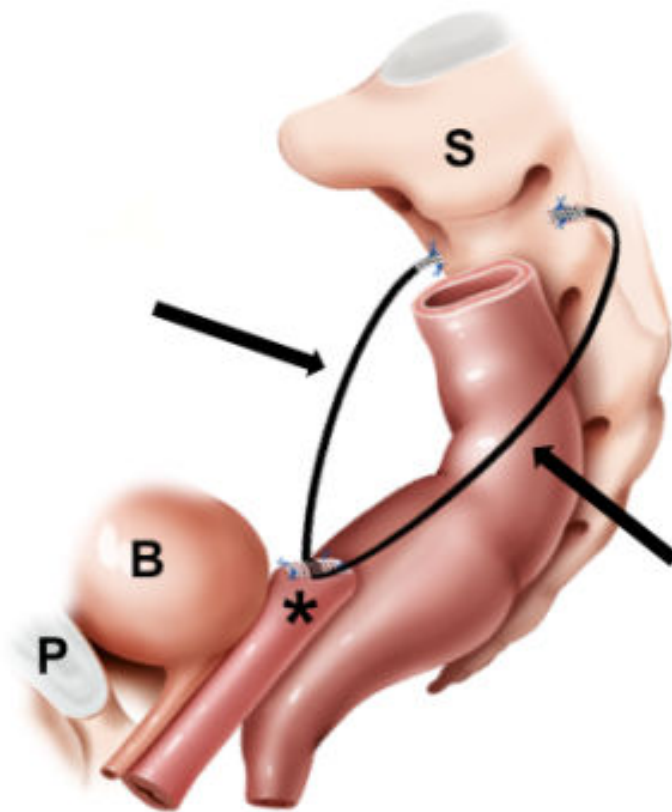


Figure 2: Sagittal view of the PVDF structures in the small pelvis. In vaginosacropexy (VASA), the uterosacral ligaments (USLs) were replaced by the polyvinylidene fluoride (PVDF) structures in bilateral order. The parts of the PVDF structure that replace the USLs (black arrows) had a length of 9.3 cm. They were sutured at the vaginal scar (black asterisk), placed below the peritoneal fold of the USL on the left and right small pelvis and sutured to the prevertebral fascia in front of S1/S2 sacral vertebra (S). B: Bladder; P: Pubic bone.

Cervicosacropexy and vaginosacropexy surgical techniques

CESA or VASA are open abdominal surgical treatments that were performed as described by Jager et al. [9,10]. In brief, specially designed polyvinylidene fluoride (PVDF) structures (Dynamesh CESA, Dynamesh VASA, FEG Textiltechnik mbH, Aachen, Germany) were used to replace the USLs (Figure 1). The parts of the PVDF structure that replaced the USLs were placed in the peritoneal fold of the USLs on both sides (left and right small pelvis) and attached to the prevertebral fascial layer in front of the S1/S2 sacral vertebra by non-absorbable sutures (Figure 2) (www.cesa-vasa.com).

In patients with a uterus, CESA was performed. After supracervical hysterectomy, the PVDF structure (Dynamesh CESA, FEG Textiltechnik mbH, Aachen, Germany) was sutured at the cervical

stump with 4 non-absorbable sutures. The parts of the PVDF structure that replaced the USLs were 8.8 cm in length and were pulled through the peritoneal fold of the USLs on both sides (left and right small pelvis) and attached to the prevertebral fascial layer in front of the S1/S2 sacral vertebra by non-absorbable sutures (Figure 2) [9].

VASA was performed in patients who had undergone vaginal hysterectomy. The surgical procedure was nearly identical to CESA. The PVDF structure (Dynamesh VASA, FEG Textiltechnik mbH, Aachen, Germany) was attached at the vaginal stump with 4 non-absorbable sutures. Two sutures each were horizontally placed below and above the running vaginal scar. The parts of the PVDF structure that replaced the USLs were 9.3 cm in length and were pulled through the peritoneal fold of the USL on both sides (left and right small pelvis)

and attached to the prevertebral fascial layer in front of the S1/S2 sacral vertebra by non-absorbable sutures (Figure 2) [10].

Transobturator Tape 8/4 Surgical Technique

The TOT was placed following the procedure described by Delorme [14]. We modified the technique and named it TOT 8/4. Subsequently, a Hegar 8 dilator was placed in the urethra and another Hegar 4 dilator was placed suburethrally between the tape and the urethra. The surgeon held the Hegar dilators in a parallel position and the surgical

assistant tightened the TOT until the tape could not be advanced anymore. Both Hegar dilators remained in a parallel position during vaginal epithelium suturing and were removed before the last stitch [15,16].

A TOT 8/4 was suggested as a treatment when the patients remained incontinent after CESA or VASA. Furthermore, on the basis of our previous experiences, the TOT 8/4 treatment was also suggested when the patients showed UUI symptoms [8].

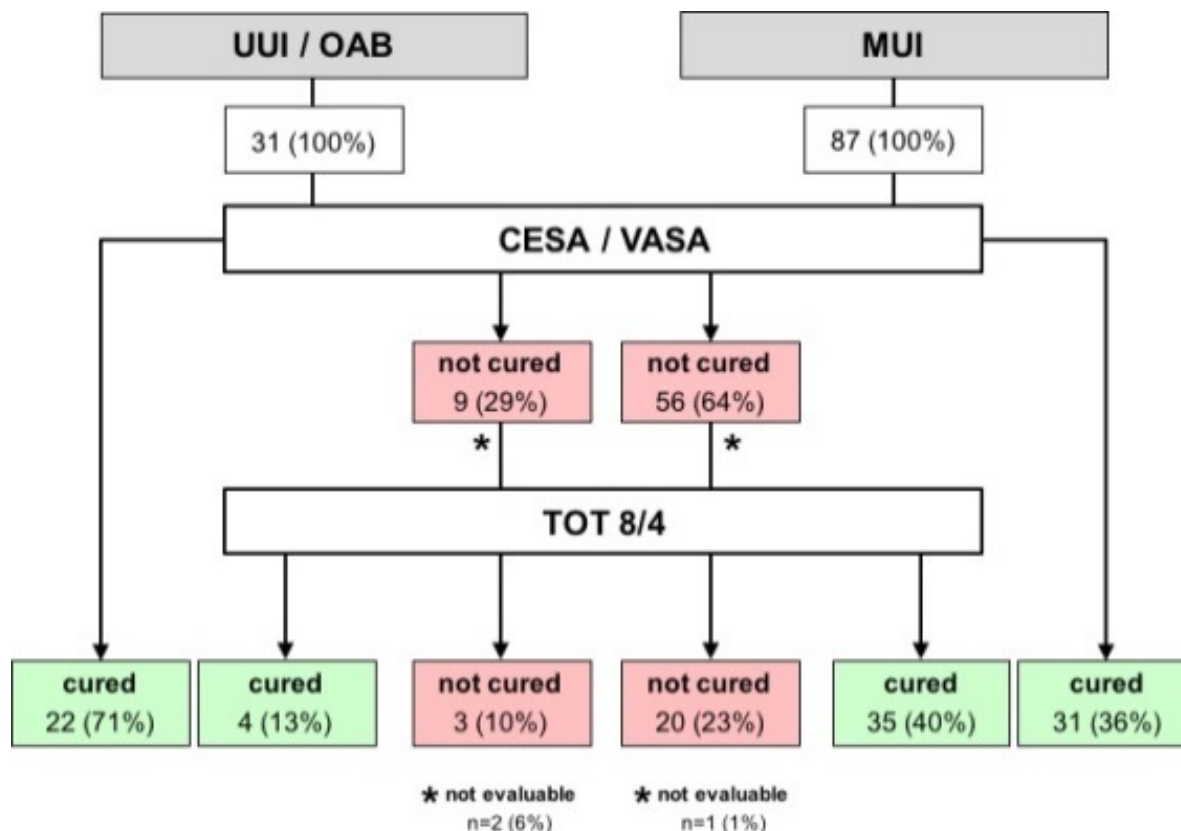


Figure 3: Distribution and outcome of 118 patients with urgency urinary incontinence (UUI)/overactive bladder syndrome wet (OAB) and mixed urinary incontinence (MUI) (the 15 patients with total incontinence (TI) are not depicted in this figure). Thus, urinary continence was defined as the total absence of any kind of UI symptoms after either cervicosacropexy (CESA)/vaginosacropexy (VASA) or additional transobturator tape (TOT 8/4).

Postoperative management

All patients were requested to visit the outpatient clinic 2 weeks, 4 weeks, and 4 months after each type of surgery. Thereafter, patients were interviewed once a year after each type of surgical intervention.

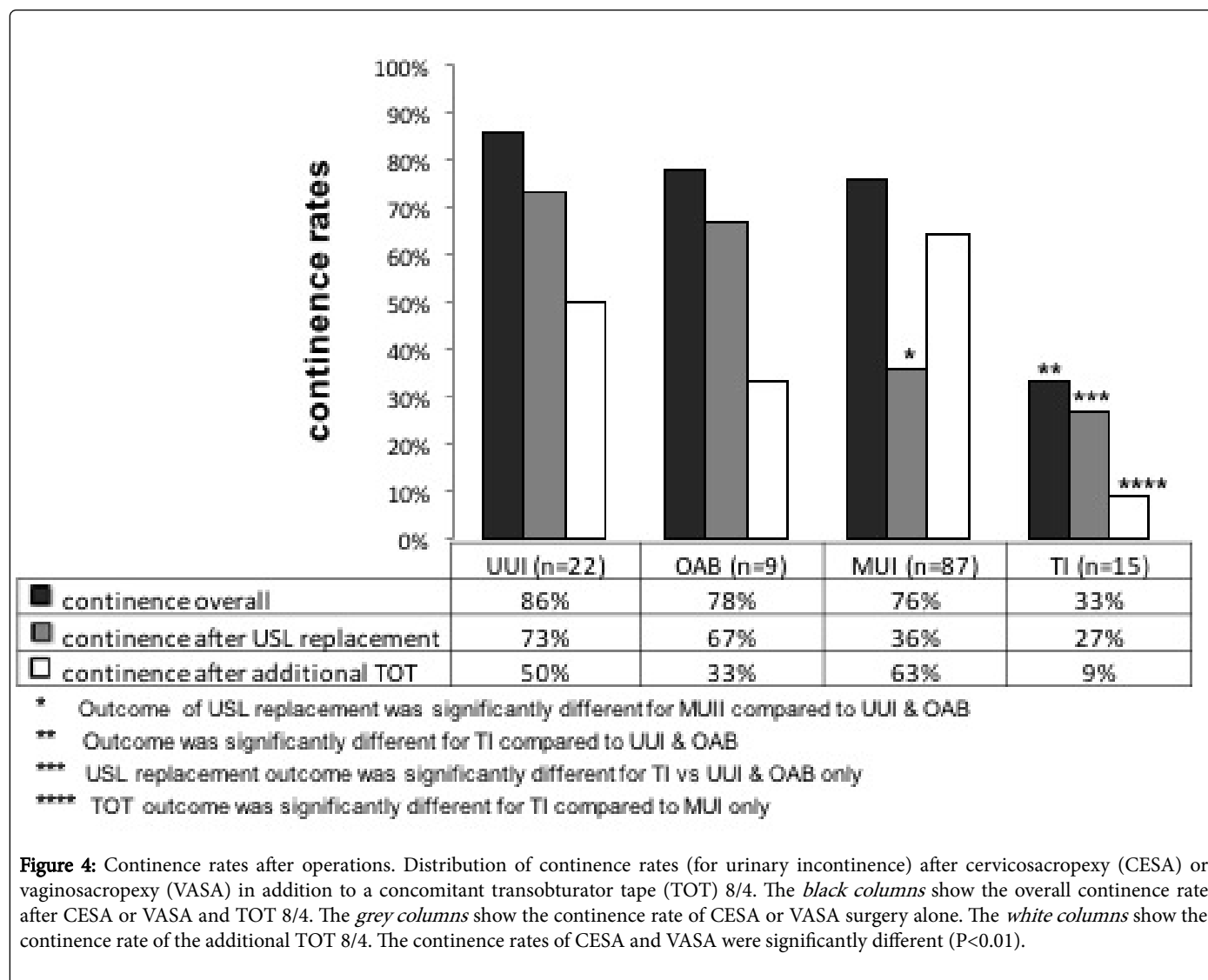
Details of ethical approval

Ethical approval for CESA, VASA and TOT surgical procedures was obtained from the Local Ethics Commission of the Medical Faculty of the University of Cologne, Germany, in November 2011 (No. 11-016) and extended in March 2013 (ext. No 13-016).

Statistical Methods

Numeric data are presented as mean and median. Frequencies are given in percentages. Comparisons between different types of urinary incontinence were done by U Mann-Whitney test or Chi-square test. Continence rates are presented with 95% confidence interval (CI).

Data were analyzed with SPSS version 22 or SAS 9.3 (SAS Institute Inc., Cary, NC, USA) at a significance level of 1%.



Results

149 patients met the study criteria and gave informed consent. 16 patients that were lost during follow-up or did not want further treatment were excluded from the analyses. The retrospective analysis was conducted on patients who were operated between October 2013

and October 2015. The median observation time was 11 months (ranging between 6 and 36 months).

The pertinent clinical data of the 133 patients that were evaluated did not significantly differ. However, patients with total incontinence (TI) were older than the others (Table 1).

	UUI (n=22)	OAB (n=9)	MUI (n=87)	TI (n=15)
Age at surgery (years)				
Mean (SD)	65 (±12)	60 (±10)	61 (±11)	71 (±9)*
Median	68	57	60	70*
Range	43-81	50-72	28-79	50-83*
Body mass index (kg/m²)				
Mean (SD)	26 (±5)	23 (±3)	27 (±5)	27 (±5)
Median	26	22	26	29

Range	18-32	18-30	18-45	17-32
Parity				
Median	2	2	2	2
Range	0-5	1-3	0-6	0-3
Urinary incontinence (since age)				
Mean (SD)	52 (±13)	53 (±12)	50 (±12)	55 (±14)
Median	49	50	50	55
Range	26-75	40-70	25-75	28-79
Menopausal Status at start of symptoms				
Pre (%)	5 (33%)	4 (57%)	26 (33%)	3 (23%)
Post (%)	10 (67%)	3 (43%)	52 (67%)	10 (77%)
Missing	7	2	9	2
UUI: Urgency Urinary Incontinence; OAB: Overactive Bladder Syndrome wet; MUI: Mixed Urinary Incontinence; TI: Total Incontinence; SD: Standard Deviation				
*P-value<0.01 (age at surgery TI vs all others)				

Table 1: Baseline clinical parameters of the 133 patients before CESA and VASA operations.

Before CESA and VASA operations all patients had POP-Q stage I of the apex.

22 patients (16.5%) had UUI and 9 patients (6.8%) had OAB (wet). 87 patients (65.4%) were diagnosed as having MUI and 15 patients (11.3%) were totally incontinent (TI).

57 patients were operated by CESA and 76 patients were treated by VASA. Major intraoperative complications such as major hemorrhages and bladder lesions were not observed. The operations lasted for mean 85 min (45-240 min). Mesh erosions or recurrence of prolapse were not observed within the follow-up period. One patient of the CESA group had elevated postvoid residuals 2 days after VASA and needed intermittent catheterization for 1 day. Two patients of the CESA group had urinary tract infection, which was resolved after administering oral antibiotics.

The continence rates after CESA or VASA varied according to the type of UI (Table 2). UUI was cured immediately after CESA or VASA in 16 of the 22 patients (72.7%) (CI [54-92%]). A nearly identical continence rate was found in 6 of the 9 patients with OAB (wet) (66.7%) (CI [36-98%]). Of the 87 patients with MUI, 31 patients (35.6%) (CI [26-46%]) were cured by CESA or VASA and of the 15 patients with TI, only 4 patients (26.6%) (CI [5-49%]) became continent (Table 3).

The remaining 75 patients (including 15 patients with TI) received a TOT 8/4. One of the 3 incontinent patients of the OAB (wet) group and 3 of the 6 patients of the UUI group became continent, which led to an overall continence rates of 86.3% (CI [72-100%]) and 77.7% (CI [51-100%]) in the UUI and OAB (wet) groups, respectively (Figure 3). However, this difference was not statistically significant (P>0.01) (Tables 2 and 3).

56 patients of the MUI group who remained incontinent after CESA or VASA and received a TOT 8/4. 35 patients (62.5%) became

continent, thus leading to an overall cure rate of 75.9% (Figure 3). Of the 15 patients of the TI group, 11 patients received a TOT 8/4; however, only one patient was cured thereafter. The overall cure rate for these patients was 33.2% (Figure 4).

	UUI (n=22)	OAB (n=9)	MUI (n=87)	TI (n=15)
Continence overall	19/22	7/9	66/87	5/15
	86%	78%	76%	33%
	(72-100)	(51-100)	(67-85)	(9-57)
Continence by USL replacement	16/22	6/9	31/87	4/15
	73%	67%	36%	27%
	(54-92)	(36-98)	(26-46)	(5-49)
Continence by additional TOT	3/6	1/3	35/56*	1/11
	50%	33%	63%	9%
	(10-90)	(0-86)	(51-77)	(0-26)
Data shown as n, % and (95% CI)				
UUI: Urgency Urinary Incontinence; OAB: Overactive Bladder Syndrome Wet; MUI: Mixed Urinary Incontinence; TI: Total Incontinence				
*n=1 not evaluable				

Table 2: Outcome of USLs replacement (CESA/VASA) and TOT 8/4 according to the type of urinary incontinence.

The replacement of the USL by CESA or VASA resulted in the disappearance of SUI symptoms in 31 of the 87 patients with MUI (35.6%). The TOT 8/4 level III repair led to the disappearance of

urgency incontinence symptoms in 30 of the remaining 55 patients with MUI (54.5%) and in 4 of the 9 patients with UUI and OAB (wet) who remained incontinent after CESA or VASA.

	UUI vs. OAB	MUI vs. UUI & OAB	TI vs. UUI & OAB	TI vs. MUI
Continence overall	ns	ns	≤0.01	≤0.01
Continence by USL replacement	ns	≤0.01	≤0.01	ns
Continence by additional TOT	ns	ns	ns	≤0.01
UUI: Urgency Urinary Incontinence; OAB: Overactive Bladder Syndrome Wet; MUI: Mixed Urinary Incontinence; TI: Total Incontinence				
ns: non-significant				

Table 3: Comparison of the outcome of the different types of UI after replacement of the USLs (CESA/VASA) and TOT 8/4.

Subsequently, the overall continence rates for patients who underwent the two-step surgical procedure (CESA or VASA with or without an additional TOT 8/4) were 75.9% for the CESA group (42 of the 54 patients were continent) and 62.0% for the VASA group (49 of the 79 patients were continent).

Conclusions

This study demonstrated that approximately 70% of the patients with UI were cured by surgically supporting the level I and level III of the pelvic floor. Since the early 1990s, researchers have hypothesized that UI depended on the anatomical defects in these levels; however, only the level III repair using suburethral tapes became a clinical standard [12-14,17]. Level I surgical repair did not find its way into the clinical UI treatments.

In level I the uterosacral ligaments (USLs) are the most crucial structures [5]. Therefore, level I surgical repair should consist of a functional repair of the USLs. Barber and Amundsen published fixation techniques by suturing the vaginal vault to the remnants of the USLs [18,19]. In order to compare the effects on urinary incontinence this technique had to be standardized. Therefore, we developed the CESA and VASA not only with an intention to repair prolapse but also to prevent or treat UI [6,8,19].

In the crucial first step, we realized that the bony pelvis is identical in every woman. In the subsequent steps, we evaluated the accurate anatomical length of the USL as well as the suitable material for replacing and fixing the USLs on both sides [6,20]. PVDF was chosen as material because of its limited tendency of shrinking and its biocompatibility [6,21]. Finally, a common PVDF structure was developed, which could be used in every woman in the same identical technique.

The standardization of the CESA or VASA procedures in all patients facilitated in analyzing the causes of UI. When the patients remained incontinent after CESA or VASA, we perceived that these patients might have an additional defect in another level of the pelvic floor. Without the standardization of these procedures, we would have probably assumed that incorrect length of the tapes or incorrect anatomical placement and fixation led to UI.

The same principles were applied for the TOT. We resolved the main problem in level III repair, which is to define a standard distance between the urethra and suburethral tape, by developing the TOT 8/4 procedure [15]. However, when the patients remained incontinent even after an additional TOT 8/4, we assumed that these patients had an additional defect in level II ("three-levels defect").

After CESA or VASA, the urgency incontinence symptoms were cured in 22 of the 31 patients with UUI and OAB (wet), indicating that these symptoms were mainly due to a level I defect that could be cured by CESA or VASA. However, why 4 of the remaining 9 incontinent patients became continent after receiving TOT 8/4 could not be explained so far. Our detailed analysis of all measured parameters could not delineate the patients who needed more than a level I repair.

An overwhelming number of patients (65%) were diagnosed as having MUI. Our results indicated that these patients showed a nearly balanced problem in levels I and III because their continence rates were 36% after CESA or VASA alone and increased to 76% after receiving an additional TOT 8/4.

This conclusion has to be viewed with caution. In a preliminary study, we proposed that the patients with MUI should first be treated with a less stressful TOT 8/4 surgery. However, this study had to be discontinued after treating 10 patients with MUI because none of these became continent. This finding may indicate that a level III repair is only effective in patients with MUI if level I of the pelvic floor remained intact or was already repaired.

Our experience in providing the surgical treatment for TI is limited to the 15 patients in this study, who were considered for a neobladder or continuous urine ablation system. However, these patients insisted on undergoing a trial procedure of CESA or VASA despite our lack of previous experience in providing TI treatments. We observed that 4 of these 15 patients became totally continent just by repairing the USL. The TOT 8/4 technique was helpful in one more patient. The remaining 10 patients did not improve and remained totally wet.

So far, we were unable to explain this observation. Our preliminary experience with an additional level II repair indicated that in most of these patients all 3 levels of the pelvic floor are involved.

Before conducting this study, we believed TOT would be a classical level III repair that would only cure SUI. However, we did not expect a level I repair by CESA or VASA would also cure SUI. Astonishingly, CESA or VASA cured SUI symptoms and we observed that TOT cured urgency incontinence symptoms. However, we were unable to explain the significance of these complementary effects on incontinence.

The findings of this study are consistent with previous assumptions and clinical experiences, which stated that UI is based on pelvic anatomical defects. On the basis of the previous surgical techniques for prolapse surgery, we developed new methods to restore physiological bladder suspension. These operations were extremely effective and were basically able to cure all kinds of UI.

Furthermore, we believed an additional level II defect persisted in those patients in whom the treatment was ineffective. With the standardization of level I and III repairs, future research is warranted to investigate about the level II repair.

References

1. de Boer TA, Salvatore S, Cardozo L, Chapple C, Kelleher C, et al. (2010) Pelvic organ prolapse and overactive bladder. *Neurourol Urodyn* 29: 30-39.
2. Halaska M, Maxova K, Sottner O, Svabik K, Mlcoch M, et al. (2012) A multicenter, randomized, prospective, controlled study comparing sacrospinous fixation and transvaginal mesh in the treatment of posthysterectomy vaginal vault prolapse. *Am J Obstet Gynecol* 207: e301-307.
3. Nygaard I, Brubaker L, Zyczynski HM, Cundiff G, Richter H, et al. (2013) Long-term outcomes following abdominal sacrocolpopexy for pelvic organ prolapse. *JAMA* 309: 2016-2024.
4. van der Vaart CH, van der Bom JG, de Leeuw JR, Roovers JP, Heintz AP (2002) The contribution of hysterectomy to the occurrence of urge and stress urinary incontinence symptoms. *BJOG* 109: 149-154.
5. DeLancey JO (1993) Anatomy and biomechanics of genital prolapse. *Clin Obstet Gynecol* 36: 897-909.
6. Jager W, Ludwig S, Stumm M, Mallmann P (2016) Standardized bilateral mesh supported uterosacral ligament replacement - cervico-sacropexy (CESA) and vagino-sacropexy (VASA) operations for female genital prolapse. *Pelviperiology*.
7. Rizk DE, Czechowski J, Ekelund L (2004) Dynamic assessment of pelvic floor and bony pelvis morphologic condition with the use of magnetic resonance imaging in a multiethnic, nulliparous, and healthy female population. *Am J Obstet Gynecol* 191: 83-89.
8. Jager W, Mirenska O, Brugge S (2012) Surgical treatment of mixed and urge urinary incontinence in women. *Gynecologic and obstetric investigation* 74: 157-164.
9. Jager W (2016) Cervico-Sacropexy (CESA) and Cervico-Recto-Sacropexy (CERESA). In: Alkatout I and Mettler L. *Hysterectomy - A Comprehensive Surgical Approach*. Cham, Switzerland: Springer International Publishing.
10. Jäger W (2016) Vagino-Sacropexy (VASA) and Vagino-Recto-Sacropexy (VARESA). *Hysterectomy-A Comprehensive Surgical Approach*. Cham, Switzerland: Springer International Publishing.
11. DeLancey JO (1994) Structural support of the urethra as it relates to stress urinary incontinence: the hammock hypothesis. *Am J Obstet Gynecol* 170: 1713-1720.
12. Petros PE, Ulmsten UI (1993) An integral theory and its method for the diagnosis and management of female urinary incontinence. *Scand J Urol Nephrol* 153: 1-93.
13. Haylen BT, de Ridder D, Freeman RM, Swift SE, Berghmans B, et al. (2010) An International Urogynecological Association (IUGA)/International Continence Society (ICS) joint report on the terminology for female pelvic floor dysfunction. *Int Urogynecol J* 29: 4-20.
14. Bump RC (2014) The POP-Q system: two decades of progress and debate. *Int Urogynecol J* 25: 441-443.
15. Delorme E (2001) Transobturator urethral suspension: mini-invasive procedure in the treatment of stress urinary incontinence in women. *Prog Urol* 11: 1306-1313.
16. Ludwig S, Stumm M, Mallmann P, Jager W (2016) TOT 8/4: A Way to Standardize the Surgical Procedure of a Transobturator Tape. *BioMed Research International* 2016: 1-4.
17. Ulmsten U (2001) An introduction to tension-free vaginal tape (TVT)--a new surgical procedure for treatment of female urinary incontinence. *Int Urogynecol J Pelvic Floor Dysfunct* 12: S3-S4.
18. Barber MD, Visco AG, Weidner AC, Amundsen CL, Bump RC (2000) Bilateral uterosacral ligament vaginal vault suspension with site-specific endopelvic fascia defect repair for treatment of pelvic organ prolapse. *Am J Obstet Gynecol* 183: 1402-1410.
19. Amundsen CL, Flynn BJ, Webster GD (2003) Anatomical correction of vaginal vault prolapse by uterosacral ligament fixation in women who also require a pubovaginal sling. *J Urol* 169: 1770-1774.
20. Ludwig S, Stumm M, Mallmann P, Jager W (2016) Surgical Replacement of the Uterosacral- and Pubourethral-Ligaments as Treatment for Urgency Urinary Incontinence. *Austin J Womens Health* 3: 1019.
21. Siddique SA, Gutman RE, Ybarra MAS, Rojas F, Handa VL (2006) Relationship of the uterosacral ligament to the sacral plexus and to the pudendal nerve. *Int Urogynecol J Pelvic Floor Dysfunct* 17: 642-645.
22. Klinge U, Klosterhalfen B, Ottinger AP, Junge K, Schumpelick V (2002) PVDF as a new polymer for the construction of surgical meshes. *Biomaterials* 23: 3487-3493.