

## Tandem Spinal Stenosis (TSS): Literature Review and Report of Patients Treated with Simultaneous Decompression

Robert W Molinari\*, William L Gruhn and Christine Molinari

University of Rochester Medical Center, Rochester, NY, USA

### Abstract

#### Summary

There is a paucity of published literature involving the incidence and management of tandem spinal stenosis (TSS). A retrospective study evaluating both the incidence and surgical management of TSS with simultaneous decompressive surgery in different regions of the spine was performed in a busy university degenerative spine treatment center. Simultaneous spinal surgery is associated with high perioperative morbidity, but appears to be safe and effective in this small subset of adult patients.

**Introduction:** Tandem spinal stenosis is defined as spinal stenosis that involves 2 different regions of the spine with the stenosis typically appearing the cervical and lumbar spine. The purpose of this study is review the existing literature and to evaluate the safety and efficacy of simultaneous decompressive surgery in different regions of the spine in a small subset of adult patients who require surgical treatment for TSS.

**Methods:** During the period from 2003-2010, 1023 consecutive patients were treated surgically for symptomatic spinal stenosis by the same surgeon (RWM) at a university medical center. 9 of the 1023 patients (0.88%) had signs, symptoms and imaging studies consistent with the diagnosis of tandem spinal stenosis (TSS). Each of the 9 patients presented with clinical manifestations of TSS to include neurogenic claudication, complex gait disorder, and a mixed pattern of diffuse upper and lower motor neuron signs and symptoms. All 9 TSS patients underwent simultaneous decompressive surgery in different regions of the spine performed by the same fellowship-trained spinal surgeon (RWM) and his team. The average age of the patients was 67 yrs (range 52-81 yrs). 7 patients had combination cervical/lumbar stenosis and 2 patients had combination thoracic/lumbar stenosis. Operative times, blood loss, length of hospital stay, major and minor complications, and preoperative pain scores were recorded for all patients. The average follow-up was 24 months (range 6-48 months). Functional outcomes (NDI and Oswestry scores), pain, and satisfaction scores were recorded at the time of ultimate follow-up. Additionally, preoperative pain scores were compared with pain scores at ultimate follow-up.

**Results:** Mean operative time was 2 hours 39 minutes (range 1 hr 51 min - 4 hrs 17 min). Blood loss for the simultaneous procedures averaged 558 cc (range 150 -1300 cc). Hospital stay length averaged 7.4 days (range 3-18 days) and 6 patients required prolonged postop rehabilitation. There were no major postoperative complications in all 9 patients. 7 patients (78%) were available for long-term follow-up at average 24 months postop. Analog pain scores demonstrated an average 5-point improvement at ultimate followup, and there was a statistically significant difference between preoperative and postoperative analog pain scores (Preop 7.8, Postop 1.9,  $p=0.0001$ ). Functional outcomes at the time of ultimate follow-up demonstrated an average NDI score of 15.6 points (range 2-25) and an Oswestry score of 21 points (range 8-34)- both consistent with mild disability. Scores for patient satisfaction scores were high, averaging 8.7 points on a 0-10 scale.

**Conclusion:** The incidence of TSS among patients requiring surgery for spinal stenosis is extremely low, and there is a paucity of existing literature on this topic. Simultaneous surgery in different regions of the spine appears to be an effective treatment option for the few patients who present with the classic findings of TSS. In this case series, patient morbidity is higher than reported for isolated spinal decompressive procedures. However, functional outcomes do not appear to be adversely affected by the simultaneous technique, and patient satisfaction is high.

**Significance:** Simultaneous decompressive surgery is a viable treatment option for the small subset of adult patients who present with symptomatic TSS.

**Keywords:** Spinal stenosis; Tandem; Surgery; Simultaneous; Cervical; Lumbar

### Introduction

Tandem spinal stenosis (TSS) is defined as significant spinal stenosis occurring in two different regions of the spine [1]. TSS typically involves both the cervical and lumbar regions. The primary manifestations of TSS include intermittent neurological claudication, progressive gait disturbance, and mixed symptoms and signs of the upper and lower extremities. These patients typically present with both upper and lower neurologic findings on examination. While spinal decompressive procedures for isolated regional spinal stenosis are very common in the adult population, there is a paucity of existing literature addressing the surgical management of symptomatic combination stenosis in different regions of the spine.

The concept of multiple areas of concomitant spinal stenosis in different was first described by Brain and Wilkerson in 1957 [1].

**\*Corresponding author:** Robert W. Molinari, University of Rochester, Department of Orthopaedics, 601 Elmwood Ave, box 665, Rochester, New York 14534, USA, Tel: 5856627756; E-mail: E-mail: [Robert\\_Molinari@URMC.Rochester.edu](mailto:Robert_Molinari@URMC.Rochester.edu)

**Received** November 10, 2013; **Accepted** December 06, 2014; **Published** December 08, 2014

**Citation:** Molinari RW, Gruhn WL, Molinari C (2014) Tandem Spinal Stenosis (TSS): Literature Review and Report of Patients Treated with Simultaneous Decompression. J Spine 4: 200. doi:[10.4172/2165-7939.1000200](https://doi.org/10.4172/2165-7939.1000200)

**Copyright:** © 2014 Molinari RW, et al. This is an open-access article distributed under the terms of the Creative Commons Attribution License, which permits unrestricted use, distribution, and reproduction in any medium, provided the original author and source are credited.

Subsequently, we could identify only 10 articles having been published to date on TSS. At the present time, both the incidence and most appropriate surgical management of TSS remain unclear in the existing literature. There is wide variation in the reported incidence of TSS ranging from 0.9-25% [2-5]. In addition, four publications recommend a staged decompression approach for TSS patients [2,3,6,7]. These studies ascribe too much potential risk to the simultaneous surgical approach. However, there are several theoretical advantages inherent to the simultaneous approach including decreased operative and postoperative costs, shorter recovery times, and with the need for only a single hospitalization. The procedure may also be better-suited for high anxiety patients.

The purpose of this study is to review the literature and evaluate the safety and efficacy of simultaneous decompressive surgery in different regions of the spine in a small subset of adult patients who require surgical treatment for TSS.

## Material and Methods

During the period from 2003-2010, 1023 consecutive patients were treated surgically for symptomatic spinal stenosis by the same surgeon (RWM) at a university spine center. Patients treated in the university spine center are first treated nonoperatively by a staff of board-certified, spine-trained physiatrists. Patients who are deemed to have exhausted or failed nonoperative management are then referred for surgical evaluation.

Nine of the 1023 surgical patients (0.88%) had symptoms and imaging studies consistent with the diagnosis of tandem spinal stenosis (TSS) (Figure 1a and 1b). Each of the 9 patients presented with clinical manifestations of TSS to include neurogenic claudication, complex gait disorder, and a mixed pattern of diffuse upper and lower motor neuron signs and symptoms. Imaging studies revealed degenerative spinal stenosis without instability in 2 separate regions of the spine in all of the patients. Seven patients had combination cervical and lumbar symptomatic stenosis and two patients had combination symptomatic thoracic and lumbar stenosis. All 9 TSS patients underwent simultaneous surgery in different regions of the spine performed by the same fellowship-trained spinal surgeon (RWM) and his team, with the senior surgeon (RWM) performing the decompressed portions in both regions. (Figures 1c, 1d, and 2). When wide laminectomy procedures were performed, patients had concomitant posterior instrumentation for stabilization.

The average age of the patients was 67 yrs (range 52-81). Operative times, blood loss, length of hospital stay, major and minor complications, and preoperative pain scores were recorded for all patients. The average follow-up was 24 months (range 6-48 months). Functional outcomes (Neck Disability (NDI) and Oswestry (ODI) scores), analog pain, and satisfaction scores were recorded at the time of ultimate follow-up. Preoperative pain scores were also compared with pain scores at ultimate follow-up. Electronic hospital medical record reviews were performed to determine the number of major and minor complications experienced by each patient.

Operative procedures consisted of multilevel lumbar decompression in all 9 patients. Six of the seven cervical surgeries and one of the two thoracic surgeries included instrumentation. Intraoperative and postoperative complications were recorded for each patient.

## Results

### Operative time

Mean operative time was 2 hours 39 minutes with a range from

1 hr 48 min to 4 hrs 17 min. There was a trend toward cases involving multilevel decompression of more than 6 spinal levels combined with the use of instrumentation having longer operative times than those without instrumentation and including less than 6 spinal decompressive levels.

### Blood Loss (EBL)

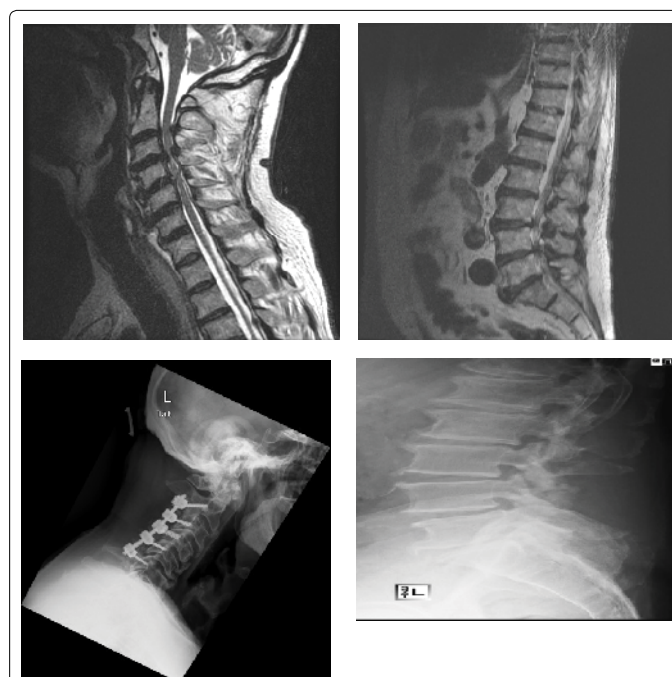
Blood loss for the simultaneous procedures averaged 558 cc (range 150 –1300 cc). The procedure portion with the highest blood loss (900 cc) involved a C2-C6 posterior cervical laminectomy and instrumented fusion. The procedure portion with the smallest amount of blood loss was 75 cc involving an L3-5 laminotomy procedure. In the 3 cases with the highest combined EBL, the cervical portion of the surgery was noted to attribute to at least double the EBL of the lumbar portion.

### Hospital stay length

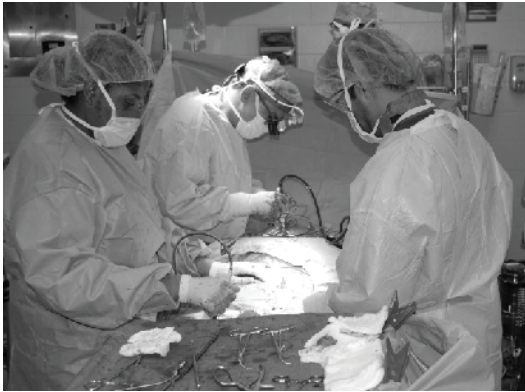Hospital stay length for all 9 TSS patients averaged 7.4 days, with a range from 3 to 18 days. 6 of the 9 patients were noted to have prolonged postoperative rehabilitation lasting more than 3 days. 3 of the 6 patients who required prolonged post-operative rehabilitation reported higher transient postoperative levels of pain. 3 patients were discharged directly to home, 3 patients were transferred to the in-hospital physical medicine rehab service, and the final 3 were transferred directly to skilled nursing facilitate.

### Complications

There were no major postoperative complications in all 9 patients and none of the 9 patients required postoperative ICU management. One patient who had clinical evidence of preoperative chronic hepatitis experienced and exacerbation of the hepatitis postoperatively. This patient's hepatitis improved to baseline status with postoperative medical management.



**Figure 1.** Preoperative midsagittal (a) cervical and (b) lumbar MRI images of a TSS patient demonstrating severe multilevel spinal stenosis. Postoperative (c) cervical and (d) lumbar standing lateral radiographs after multilevel simultaneous decompression surgery.



**Figure 2.** Intraoperative image demonstrating operative field and performance of simultaneous TSS surgery.

Minor complications included acute blood loss anemia in 6 of the 9 patients (66%) who required perioperative blood transfusion. Perioperative blood transfusion amount averaged 1.7 units of packed red blood cells (range 0-4 units), with an intraoperative average of 0.77 units and a postoperative average of 0.88 units. TSS surgical cases requiring blood transfusion involved those cases requiring more than 2 cervical and lumbar decompression levels combined with the use of cervical instrumentation. No patient experienced further complication related to blood loss anemia.

Three patients (33%) reported transient higher postoperative levels of pain lasting more than 72 hrs. All three of these patients had prolonged hospital stay. Six of the 9 patients (66%) required the need for prolonged postoperative rehabilitation. One patient had new-onset transient postoperative cervical radicular parathesias that resolved within 4 weeks.

### Functional outcomes

7 of the 9 patients (78%) were available for long-term follow-up at average 24 months postop with a range from 6- 48 months. One patient could not be located 18 months after TSS surgery, and another patient died 2 years after surgery from non-related medical causes and prior to obtaining ultimate TSS surgery follow-up data.

At the time of ultimate follow-up all patients completed analog pain and satisfaction scoring forms, the Neck Disability Questionnaire, and the Oswestry Disability Index questionnaire

### Pain

Preoperative analog pain scores averaged 7.8 points for all of the patients in this series with a range from 7-9 points. Analog pain scores at the time of ultimate follow-up averaged 1.9 points (range 0- 5 points). There was a statistically significant improvement noted between preoperative and postoperative analog pain scores defined using the paired t-Test statistical analysis ( $p=0.0001$ ). All of the 7 patients who were available for longer-term follow-up had pain scores that improved after TSS surgery.

### Neck Disability Index (NDI)

The average neck disability index score for all 7 patients at ultimate follow-up was 15.6 points with a range from 8 to 26 points. Scores for all 7 patients indicated only mild neck disability at the time of ultimate follow-up.

### Oswestry Disability Index (ODI)

The average ODI score at ultimate follow-up was 21 with a

range from 12 to 34 points. Scores for 6 of the 7 patients (86%) were consistent with mild lumbar disability. Only one of the 7 (14%) had residual moderate disability.

### Satisfaction

Patients were asked to rate their degree of satisfaction with the surgical procedure and outcome using an analog scoring scale. Analog satisfaction scores for the 7 patients who were available for ultimate follow-up averaged 8.7 points on a scale from 0-10 with 10 indicating the highest degree of patient satisfaction. The range of patient satisfaction was 7 to 10 points- all indicating a high degree of patient satisfaction.

### Discussion

A search of the Medline database using the key words “tandem stenosis” and “cervical and lumbar stenosis” was performed. A total of 11 articles were identified as having been published on this topic. Only 7 of the 11 published articles included patients who had surgical management for tandem spinal stenosis. Four publications included patients who were treated with a staged surgical approach, and only 3 publications included small numbers of patients who had a one-staged or simultaneous surgical approach. All 11 published studies were either commentary or retrospective reviews containing small numbers of patients with multiple surgeons.

With increasing age of the population, the occurrence of degenerative spinal stenosis increases. Isolated symptomatic stenosis in either the cervical, thoracic or lumbar spine that is refractory to conservative measures usually presents a straight-forward and well-defined decision-making process for the spinal surgeon. Isolated regional decompressive procedures are associated with high success rates in the existing literature [8,9].

Several authors have described spondylotic conditions of the spine that may confuse clinical presentations by producing significant symptoms from the both regions. Laban et al. suggested that the combination of symptomatic spinal stenosis from different spinal regions may confuse the clinical picture and complicate the surgical decision making process [4]. The authors also suggested that the symptoms of either the cervical or the lumbar stenosis initially predominate early in the clinical picture, and only after the primary pathology is treated does the secondary problem become more evident.

Since 1964 when TSS was first described, estimates of its frequency have varied widely, ranging from a low of 0.9% to a high of 28%. Two studies in the existing literature attempt to accurately define the incidence of TSS [4,10]. Lee et al. examined the cervical and lumbar spines of 440 skeletally mature cadaver specimens obtained from the Cleveland Museum of Natural History and found the prevalence of tandem stenosis to range from 0.9 to 5.4%. The authors defined spinal stenosis as an absolute mid-sagittal canal diameter measurement of less than 12 mm at least one spinal level [10]. LaBan et al. performed a 10-year review of hospital admissions to determine the frequency of tandem spinal stenosis [4]. In this retrospective study of 460,964 hospital admissions, the authors identified a base population of only 54 patients with TSS. These patients presented with multiple complaints, including neurogenic claudication, progressive gait disturbances, and neurologic signs of both upper and lower motor neuron dysfunction. For all ages, the frequency rate of TSS in this series was 12 per 100,000 admissions.

In our series of 1023 consecutive spinal stenosis surgical patients only 9 had the diagnosis of TSS (0.87%). The incidence of TSS in our

spinal stenosis surgical population is consistent with the findings reported for TSS prevalence by Lee et al. It is the senior author's opinion that 0.87% TSS incidence may be reflective of the very small number of TSS surgical patients reported to date in the literature. We believe that the diagnosis of symptomatic TSS should be based on the neurophysiologic examination findings and coupled with corresponding imaging studies showing specific regional neural compression. Simultaneous surgery should only be considered when there is clear correlation between physical examination and imaging findings

While the literature is replete with publications addressing single-region decompressive procedures, the authors were only able to identify 7 published studies to date that address the surgical management of TSS [2,3,6,7,11-13]. Each of these studies is a report of a retrospective case series involving small numbers of patients.

A staged approach to TSS patients who require surgical management is supported in the literature. Dagi et al. recommended that the surgical intervention be directed at decompression of the stenotic lesions in both the cervical and lumbar regions, but the most symptomatic level should be treated first [6]. In this retrospective review of 19 TSS patients with a mean follow-up period of 22 months, an excellent outcome was obtained in five patients (26%), four improved (21%), five deteriorated despite initial improvement (26%), and one was unchanged. Three patients could not be traced for follow-up review, and there was one postoperative death. Postoperative improvement correlated inversely with symptom duration. The authors also suggested that the presentation of TSS may mimic amyotrophic lateral sclerosis and other forms of motor-neuron disease. In contrast to these conditions, however, TSS is amenable to treatment. Functional recovery in TSS depended on early diagnosis and timely surgical intervention.

Hsieh et al. reported series of 158 patients who underwent surgery for degenerative spinal stenosis and 12 of these patients were diagnosed with TSS- an overall incidence of 7.6% [7]. Management guidelines in the 12 TSS patients required that cervical surgery be performed first if the patients had signs in the upper motor neuron region or predominant signs in the upper extremities. In the patients who had significant symptoms in the lower extremities and no signs in the upper motor neuron region, lumbar surgery was performed first. In this series, 8 of 12 patients received cervical surgery first and only 4 required further lumbar surgery. Among the 8 patients who received cervical surgery, 2 had laminoplasty, 3 laminectomy, and 3 anterior decompression and fusions. The other 4 patients received lumbar surgery only. At average 32 months follow-up, 8 patients (66.7%) had excellent or good clinical results. Ossification of the posterior longitudinal ligament (OPLL) was noted in 7 of 12 patients (58.3%) in this study. The authors concluded that OPLL might be a predominant factor in TSS, and larger population's studies are needed to confirm this finding.

Epstein et al. reported that the order of operative intervention in TSS was related to the degree of myelopathy and radiculopathy [3]. Patients requiring cervical surgery first had absolute stenosis with a spinal canal equal to or less than 10 mm in anteroposterior diameter. Those requiring lumbar surgery first presented with stenosis and a canal between 11 and 13 mm in diameter. In the latter group, patients presented with radiculopathy in the lower extremities. A significant portion (50%) had intermittent neurogenic claudication. In this series cervical cord decompression often resulted in improvement in lumbar symptoms with resolution of pain, spasticity, and sensory deficits of myelopathic origin. However, latent symptoms of claudication caused by lumbar stenosis were not affected by cervical decompression and increased in severity. The surgical management was staged and

included extensive, multiple level laminectomy, unroofing of the lateral recesses, and foraminotomy. Significant improvement was shown by 90% of the patients in this series.

Aydogan et al. also performed a retrospective study was to report the existence and management of tandem (concurrent) cervical and lumbar spinal stenosis [2]. Between 1998 and 2004, 8 adult patients were diagnosed with tandem spinal stenosis in a series of 230 patients who underwent surgery for spinal stenosis (3.4%). Three patients received cervical surgery first and 5 patient's lumbar surgery first. The Japanese Orthopaedic Association Score of all patients improved from an average of 8.1 preoperatively to an average of 12.7 points at final follow-up. Oswestry Disability Score improved from mean 58.1 to 19.3 at latest follow-up. All the patients had excellent or good results and none deteriorated neurologically. The authors concluded that although tandem spinal stenosis occurred relatively infrequently, it's possible presence should not be overlooked. They also recommended that the treatment plan must be designed according to the chief complaints and symptoms of the patient.

The concept of simultaneous surgery for TSS has not been adequately addressed in the literature. Only 3 published studies were identified involving patients who had simultaneous surgery for TSS [11-13]. Each of these studies also included a small number of patients and was retrospectively performed.

Naderi and Mertol described two patients with symptomatic combined stenosis of the cervical and lumbar spinal canal in which simultaneous decompressive surgery was performed [12]. Total surgical time for each of these patients was 130 and 150 minutes. The authors reported neurologic improvement and gait improvement postoperatively, but no outcomes measures were utilized in this case report. The authors recommended simultaneous surgery as an alternative approach for patients with symptomatic multilevel spinal stenosis in different regions of the spine.

Kikuie et al. performed a retrospective study of clinical outcomes of 1-staged combined cervical and lumbar decompression for 17 elderly patients with TSS with average five-year follow-up [13]. Eight of the 17 patients had simultaneous surgery and 9 had staged same-day procedures. The JOA-B, JOA-C scores, and activities of daily life improved significantly 6 months after surgery, but ultimately deteriorated with additional follow-up. Complications involving other parts of the body significantly influenced clinical deterioration. Twelve patients (71%) were satisfied with their surgical outcome. The authors opined that reasons other than spinal pathology affected symptom deterioration at final follow-up, and most patients expressed satisfaction at middle-term follow-up periods.

Most recently, Eskander et al. compared outcomes after simultaneous decompression of the cervical and lumbar spine versus staged operations in 43 patients [11]. Twenty-one patients underwent simultaneous decompression of both the cervical and lumbar spine and 22 underwent staged decompression of the cervical spine followed by decompression of the lumbar spine at a later date. With a mean follow-up of 7 years, both groups improved in JOA and ODI scores without a significant difference between the 2 operative groups in terms of major or minor complications, JOA, or ODI scores. Age above 68 years, estimated blood loss  $\geq$ 400 mL, and operative time  $\geq$ 150 minutes significantly increased the number of complications in both groups. The authors concluded that TSS can be effectively managed by either surgical intervention, simultaneous, or staged decompressions. However, patient age, blood loss, and operative time do significantly impact outcomes. Therefore, operative management should be tailored

to the patient's age and the option which will limit blood loss and operative time, whether that is by simultaneous or staged procedures.

Our series of 9 consecutive TSS patients treated with simultaneous surgery is the second largest series to be reported in the existing literature. The results of our series demonstrate that simultaneous surgery is an effective technique for the management of TSS. Operative time in our series averaged 2 hours and 39 minutes and total blood loss averaged 558 cc. These numbers are similar to those previously reported in the existing literature. However, complications in our series appear to be less than those previously reported. A contributing factor to this finding may be the relatively younger age of the patients in our series (ave age 67).

The average hospital stay-length of 7.4 days in our series demonstrates the propensity towards prolonged hospitalizations after simultaneous surgery. Six of the nine patients (66%) experienced delayed progress with their postoperative rehabilitation, an additional three of the nine (33%) experienced prolonged increased levels of postoperative pain. Only one-third of our study patients were discharged directly to home after surgery, another third were transferred to the in-patient rehabilitation service, and the final third were transferred to a lesser care level skilled nursing facility.

Acute blood loss anemia was a frequent occurrence in our series. Six of the nine TSS patients (66%) required perioperative blood transfusion with an average of 2.5 units per patient who required transfusion. We believe that expected high EBL preoperatively should be a relative contraindication to the simultaneous procedure.

While there were no significant major complications, minor complications including blood loss anemia and prolonged increased levels of postoperative pain, and prolonged rehabilitation and hospitalization time contributed to seemingly high postoperative patient morbidity with simultaneous TSS surgery.

Midterm functional outcomes in our series at average 24 month follow-up demonstrated significantly decreased levels of pain and a high level of patient satisfaction. Both NDI and Oswestry scores indicated a mild level of residual disability in our series of patients. These results suggest that overall functional outcomes of TSS simultaneous surgery are not affected by the relative increase in perioperative morbidity which may be inherent to this surgical approach. Satisfaction scores were high for all patients at the time of ultimate follow-up.

Limitations of our study include the small sample size and the retrospective method of data collection. Further comparative study between the staged and simultaneous techniques for the treatment symptomatic TSS is encouraged.

## Conclusion

The incidence of TSS among patients requiring surgery for spinal stenosis is extremely low, and there is a paucity of existing literature on this topic. Simultaneous surgery in different regions of the spine appears to be an effective treatment option for the few patients who present with the classic findings of TSS. In this case series, patient morbidity is higher than reported for isolated spinal decompressive procedures. However, functional outcomes do not appear to be adversely affected by the simultaneous technique, and patient satisfaction is high.

## References

1. Brain R, Wilkinson M (1957) The association of cervical spondylosis and disseminated sclerosis. *Brain* 80: 456-478.
2. Aydogan M, Ozturk C, Mirzanli C, Karatoprak O, Tezer M, et al. (2007) Treatment approach in tandem (concurrent) cervical and lumbar spinal stenosis. *Acta Orthop Belg* 73: 234-237.
3. Epstein NE, Epstein JA, Carras R, Murthy VS, Hyman RA (1984) Coexisting cervical and lumbar spinal stenosis: diagnosis and management. *Neurosurgery* 15: 489-496.
4. LaBan MM, Green ML (2004) Concurrent (tandem) cervical and lumbar spinal stenosis: a 10-yr review of 54 hospitalized patients. *Am J Phys Med Rehabil* 83: 187-190.
5. Long DM (1993) Lumbar and cervical spondylosis and spondylotic myelopathy. *Curr Opin Neurol Neurosurg* 6: 576-580.
6. Dagi TF, Tarkington MA, Leech JJ (1987) Tandem lumbar and cervical spinal stenosis. Natural history, prognostic indices, and results after surgical decompression. *J Neurosurg* 66: 842-849.
7. Hsieh CH, Huang T.J, Hsu RW (1998) Tandem spinal stenosis: clinical diagnosis and surgical treatment. *Changgeng Yi Xue Za Zhi* 21: 429-435.
8. Yamashita K, Ohzono K, Hiroshima K (2006) Five-year outcomes of surgical treatment for degenerative lumbar spinal stenosis: a prospective observational study of symptom severity at standard intervals after surgery. *Spine (Phila Pa 1976)* 31: 1484-1490.
9. Arinzon Z, Adunsky A, Fidelman Z, Gepstein R (2004) Outcomes of decompression surgery for lumbar spinal stenosis in elderly diabetic patients. *Eur Spine J* 13: 32-37.
10. Lee MJ, Garcia R, Cassinelli EH, Furey C, Riew KD (2008) Tandem stenosis: a cadaveric study in osseous morphology. *Spine J* 8: 1003-1006.
11. Eskander MS, Aubin ME, Drew JM, Eskander JP, Balsis SM, et al. (2011) Is there a difference between simultaneous or staged decompressions for combined cervical and lumbar stenosis? *J Spinal Disord Tech* 24: 409-413.
12. Naderi S, Mertol T (2002) Simultaneous cervical and lumbar surgery for combined symptomatic cervical and lumbar spinal stenoses. *J Spinal Disord Tech* 15: 229-231.
13. Kikuike K, Miyamoto K, Hosoe H, Shimizu K (2009) One-staged combined cervical and lumbar decompression for patients with tandem spinal stenosis on cervical and lumbar spine: analyses of clinical outcomes with minimum 3 years follow-up. *J Spinal Disord Tech* 22: 593-601.