

The Duplication of the Appendix: A Look Crossed Between the Surgeon and the Pathologist

Doh K^{1*}, Thiam I¹, Nigobora J², Ndour M² and Woto-Gaye G³

¹Laboratory of Anatomy and Cytology, Hospital Aristide Le Dantec, Dakar, Senegal

²Departement of Pediatric Surgeon, Laboratory of Anatomy and Cytology, Hospital Aristide Le Dantec, Dakar, Senegal

³University of Dakar, Senegal

*Corresponding author: Doh K, Pathologist, Laboratory of Anatomy and Cytology, Hospital Aristide Le Dantec, Dakar, Senegal, Tel: 0022177476144; E-mail: kwame.doh@ucad.edu.sn

Received date: Nov 22, 2015; Accepted date: Jan 25, 2016; Published date: Jan 27, 2016

Copyright: © 2016 Doh K, et al. This is an open-access article distributed under the terms of the Creative Commons Attribution License, which permits unrestricted use, distribution, and reproduction in any medium, provided the original author and source are credited.

Abstract

The appendicular duplication is a rare congenital malformation. From an uncertain pathogeny, it can be a fortuitous discovery or reveal by an appendicular syndrome or an occlusive syndrome intestinal. We are carrying a particular form of appendicular duplication, siege of an acute appendicitis at uncommon elements suppurated with a peritoneal reaction to a patient aged of 14 years. We discuss then the viewpoint of the surgeon and the one of the pathologist in the assistance of that affection not well known.

Keywords: Appendicular duplication; Surgeon; Pathologist

Introduction

The duplication of the appendix (DA) is a malformation congenital digestive rare. It can be isolated or associated to others malformation pathology [1-4]. The exact pathogenic of the affection remains up to now misunderstood but the theory the most admitted is an anomaly of differentiation embryonic [1]. The DA can be a discovery fortuitous, revealed by a syndrome appendicular or a syndrome occlusive. Recognized by the surgeon, the diagnostic of confirmation of the DA is histologic. The aim of that study is to carry through an anatomic particular of the DA, the part of the surgeon and the pathologist in the management of such affection.

Observation

The patient D.B aged of 14 years doesn't have any particular medical past story. He was admitted at chirurgial emergencies of the hospital Aristide le Dantec for the assistance of an abdominal pain diffused with the right iliac pit as a starting point. That pain was accompanied with post prandial vomiting late and a fever not quantified. At the admission, the patient wasn't at all good well. His temperature was 38°C. The cardiac frequency was of 90 flapping the minute and the respiratory frequency of 16 cycles the minute. The abdomen was at all supple and sensitive with a maximum at the right iliac pit. The Douglas bag was bulged and painful whenever the rectal touched. The numeration of the leucocyte was of 18800/mm³. An abdominal scan concluded gangrene appendicitis. The chirurgial exploration noted the DA at normal position, perforated to his distal end. It was associated with some adherence of lank and lodge rising up pus in the hypo-gastric sites and pelvic. An appendectomy by way retrograded realized was followed by an abundant washing peritoneal. The following immediate operations were easy. At anatomy and cytology pathologic laboratory, the appendix receiving was measure 6 cm of length. It was covered by false membranes and perforated at the point. That appendix was duplicated. It had two bases and a one point (Figure

1). At the cut, stercoral materials could be seen in the light. The histopathologic examination confirmed the digestive origin of the two « hands » of the appendix (Figure 2). That appendix was destroyed by an inflammatory process suppurated all-parietal associated to vast lobbies of calcification at contact of others matters (Figure 3). Seen again 3 months after the chirurgial intervention, the patient didn't present any complaint.

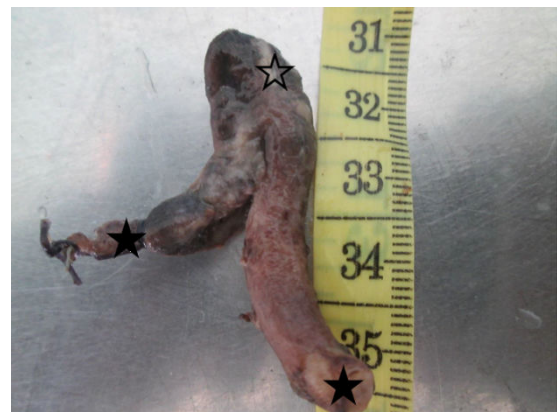

Figure 1: Macroscopic aspect of a duplicated appendicitis: Note here two basic (full star) and one tip (blank star)

Discussion

The DA was described for the first time in 1892 by Picoli et al. [2]. Since then, only a hundred of case has been described in literature. All as us, the majority of studies speak about case clinic confirming the rarity of the affection [1,2,4]. The exact prevalence of the DA is not known. Collins et al. in a series of 50,000 appendixes had reported 4 cases whether 0.008% [3]. The classification of the DA proposed by

Cave in 1936 has been modified in 1963 by Wallbridge and actualized in 1993 by Biermann [4].

Viewpoint of the surgeon

The discovery of the DA by the surgeon is mostly fortuitous as in our case [2,3]. The circumstances of discovery are the intestinal occlusion and the appendicitis [2,4].

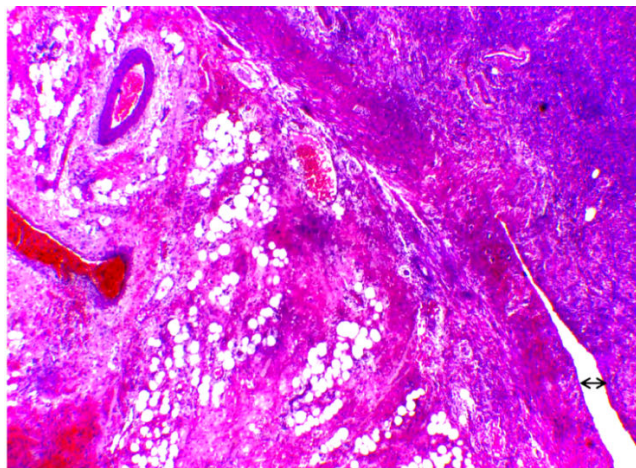


Figure 2: Suppurated appendicitis acute. Note here the duplication of the appendicitis (↔) (Hematoxylin eosin X10)

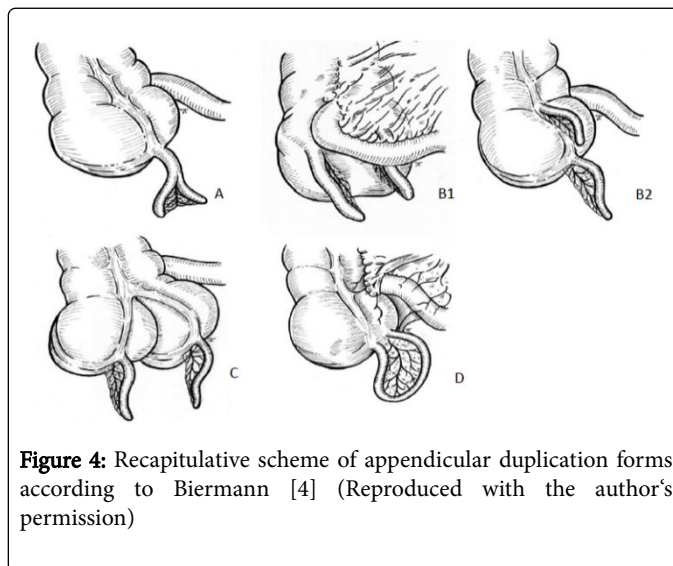


Figure 4: Recapitulative scheme of appendicular duplication forms according to Biermann [4] (Reproduced with the author's permission)

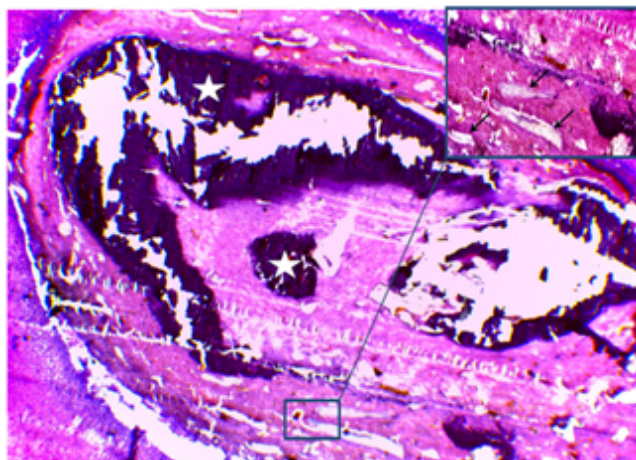


Figure 3: Vast center of calcification (star) at contact with uncommon elements (arrow) (Hematoxylin eosin X10; cartridge X40)

The radiologic examinations as the scan and the scanner are a little bit specifics [2,4]. In our case, a scan realized had unrecognized the DA. The utilization of the washing barite has given evidential results but that examination is rarely practiced in emergency situation [5]. The ignorance of an AD by the surgeon might have forensic consequences and juridical serious hence his systematic research despite its rarity [6]. In case of an appendicular lesion, even only, it is recommended to remove the whole appendixes [2]. The way to behave toward a duplicated appendix with « normal appendixes » is to controvert, but the tendency would be at the preservation [1,6]. The surgeon establishes also the classification of the DA according to the modified criterions of Bierman and asks a certification anatomopathologic.

Viewpoint of the pathologist

The pathologist confirms the DA by the underscore microscopic of a digestive side appendicular. That recognition can be sometimes hard face to the necrosis of the mucosa and/or the fibrous involution of the side. The underscore of two muscular layer separated by nerve plexus ganglionic is a good argument of diagnostic to research with minuteness. He will eliminate by this fact others structures that can gesture a DA such a primary appendicitis epiploic, a solitary diverticulitis of cecum or a diverticulosis of the appendix [7]. The pathologist identifies an eventual lesion inflammatory at level of one or of the whole appendixes. In our case of report, the two « hands » of the duplicated appendix were injured. Others authors have carried the inflammatory attack of a one appendix, the other being the histologic structure normal [1]. The pathologist appreciates the severity of the lesion and the parietal attack. He identifies if possible, the etiology of the appendicitis. We are carrying the case of an all-appendicitis suppurated with a peritoneal reaction complicating the presence of others elements.

It takes into account three forms. The type A refers to the incomplete duplication, where the two appendixes come from a common basis from the cecum. The type B1 where the two appendixes are disposed symmetrically by input at the valve of Bauhin. In the type B2 an appendix take place in the usual emplacement where taenias converge, whereas the localization of the other varies. The duplication of the cecum is classified as a type C where each cecum has its own appendix (Figure 4). Next to its forms, others authors have reported the form of an iron of horse as a type D (Figure 4) [4]. We report, one case of the type D of appendicular duplication.

Conclusion

The DA is a rare affection. Its acknowledgement and its classification are done by a surgeon. Despite its rarity, disregard it is a medical fault with juridical consequences for the surgeon. The certification anatomopathologic is recommended. The pathologist confirm the diagnostic of the DA. He establishes the positive diagnostic etiologic in case of a lesion. The DA diagnostic represents then the resultant of efforts conjugated of the surgeon and the pathologist.

Acknowledgements

The reproduction of the Figure 4 was cordially authorized to us by the doctor Firmilian Carlota and we are thanking him for that.

References

1. Boleken ME, Yildiz E, Kaya M, Deniz M (2010) Appendix duplication in association with persistent cloaca and type B2 pouch colon. *International Journal of Anatomical variation* 3: 12-4.
2. Christodoulidis G, Symeonidis D, Spyridakis M, Koukouli G, Manolakis A, et al. (2012) Acute appendicitis in a duplicated appendix. *Int J Surg Case Rep* 3: 559-62.
3. Collins DC (1955) A study of 50,000 specimens of the human appendix. *Surgery Gynec Obst* 101: 437-445.
4. Calota F, Vasile I, Mogoanta S, Zavori R, Pasalega M, et al. (2010) Horseshoe appendix: a extremely rare anomaly. *Chirurgical* 105: 271-274.
5. Peddu P, Sidhu PS (2004) Appearance of a type B duplex appendix on barium enema. *The British Journal of Radiology* 77: 248-249.
6. Al-Bdour MN, Rashaideh MA, Alkasasbeh MA, Shawaqfey JS (2008) Appendiceal duplication: a rare condition with serious clinical and medico-legal implication. *Pakistan Journal of Surgery* 24: 74-75.
7. Tiryaki C, Yazicioglu B, Haksal MC, Ciftci A, Yildiz S (2014) Primer epiploic appendagitis mimicking appendix duplication. *National Journal of Medical Research* 4: 95-97.