

## The Use of Biological 'Infill' Materials for the Treatment of Recto/Ano-vaginal Fistulae-A Systematic Review

Nuha A Yassin<sup>1\*</sup>, Alan Askari<sup>1</sup>, John T Jenkins<sup>1</sup>, Ahmad Uraiqat<sup>1</sup>, Omar D Faiz<sup>1</sup>, Ailsa L Hart<sup>2</sup> and Robin K S Phillips<sup>1</sup>

<sup>1</sup>Department of Colorectal Surgery, St Mark's Hospital and Academic Institute, Watford Road, Harrow, HA1 3UJ, United Kingdom

<sup>2</sup>The IBD Unit, St Mark's Hospital and Academic Institute, Watford Road, Harrow, HA1 3UJ, United Kingdom

\*Corresponding author: Nuha A Yassin, St Mark's Hospital and Academic Institute, Watford Road, Harrow, HA1 3UJ, United Kingdom, Tel: 0208 2354251; E-mail: nayassin@gmail.com

Received date: September 18, 2015; Accepted date: August 19, 2016; Publication date: August 25, 2016

Copyright: © 2016 Yassin NA, et al. This is an open-access article distributed under the terms of the Creative Commons Attribution License; which permits unrestricted use; distribution; and reproduction in any medium; provided the original author and source are credited.

### Abstract

**Aim:** Recto-vaginal fistulae are distressing. They are most commonly caused by obstetric injury, a failed pelvic anastomosis, or Crohn's disease. Biological infill materials have been used in their management. We assessed the efficacy of biological infill materials when recto-vaginal fistulae.

**Methods:** We applied the Preferred Reporting Items for Systematic Reviews and Meta-Analyses (PRISMA) guidelines.

**Results:** Twenty-five articles yielded a pooled total of 105 patients; 27% had Crohn's disease. Fifty-six percent of patients had treatment with glue, 31% with plug, 6% with permacol paste and 7% with stem-cells. For Crohn's, 50% were treated with glue, 39% with a fistula plug and 11% with stem cells. The overall healing rate for all infill materials was 41%, with the highest reported rate amongst the stem cell group (71%) and the lowest (32%) for glue. For Crohn's, the overall healing rate was 36%, glue was the lowest (14%), followed by the anal fistula plug (55%). Stem cells had a healing rate of 67%.

**Conclusions:** Overall, the use of infill materials to treat Crohn's and non-Crohn's related recto-vaginal fistulae is associated with healing in approximately 41% of cases. Crohn's related recto-vaginal fistulae represent a more challenging group of patients to treat.

**Keywords:** Rectovaginal fistula; Anovaginal fistula; Proctology; Glue; Plug; Infill material

### Introduction

Fistulae to the vagina distress and stigmatise women and their management remains a challenge [1]. Some may arise from intraperitoneal organs, such as the appendix, terminal ileum or sigmoid colon, where they usually communicate with the vaginal fornix. Treatment involves surgical resection of the origin of fistulation. Rectovaginal fistulae (RVF) are more complicated to manage. They will usually be found in the posterior midline of the vagina. Those that are obstetric-related may have a concomitant anal sphincter injury. Several factors are implicated in the success of any surgical repair including anatomical aspects and aetiology. The rectovaginal septum may be thin and poorly vascularised. Many cases of local repair result in failure. Other confounders are medical comorbidities, inflammatory bowel disease, persistent infection and the presence of scar tissue [2,3].

The most common cause is obstetric injury [4], followed by Crohn's disease [5]. Less common causes include malignancies, for example of the cervix, vagina, uterus or rectum. In addition, recto-vaginal fistulae can result after radiotherapy or as postoperative complications, typically after a low anterior resection with stapled anastomosis, hysterectomy or rectocele repair. The diagnosis is mainly clinical by direct observation supported by examination under anaesthetic.

Radiology is frequently disappointing, but in some case anal ultrasound, MRI or contrast radiology may be useful [6].

Surgical options include extended anal sphincter repair (applicable when there is an associated anal sphincter injury), transanal advancement flap (made easier when perineal descent/internal intussusception are present), transvaginal or transperineal approaches (frequently with an adjunct of either a Martius flap or a biological material) or an abdomino-anal pull-through operation [7]. Other techniques and adjuncts include omentum and local muscle flaps, such as gracilis.

Reported success rates of clinical healing vary from 41-100% for non-IBD fistulae [8-17] and 40-67% with Crohn's [18-27].

Novel surgical techniques include ligation of the intersphincteric fistula tract (LIFT) [28] and the use of biological infill material [29]. The added benefit of these infill materials is unclear. We systematically reviewed the role of biological infill materials (not including biological meshes) when treating rectovaginal fistulae of all aetiologies.

### Methods

This review was conducted according to the Preferred Reporting Items for Systematic Reviews and Meta-Analyses (PRISMA) guidelines [30].

### Search strategy

Two independent reviewers searched PubMed (January 1966 to August 2013), the Cochrane Database and EMBASE (January 1980-August 2013). The keywords used were: rectovaginal, fistula, anovaginal, glue, paste, plug, bioprosthetic and stem cell. Searches were limited to English language articles. The abstracts of all potentially relevant studies were consulted to identify studies suitable for inclusion. The full texts of all eligible articles were retrieved. Additional strategies included searching the cited references of selected articles.

### Selection criteria

All studies investigating biological infill material as a treatment for rectovaginal fistulae were included. We did not include studies assessing biological mesh as an adjunct to surgical repair of rectovaginal fistula.

### Data collection and analysis

We determined study design, patient demographics, fistula aetiology, previous seton drainage, previous anal surgery, peri-operative management, management of the internal fistula opening, fistula healing, faecal incontinence, follow-up duration and all complications. Data were independently extracted by two reviewers (NY and AA). Quality assessment of the included articles was performed using criteria from the Cochrane Reviewers' Handbook and the Newcastle-Ottawa scale [31] (for non-randomised studies). Disagreement was resolved according to the predefined strategy using consensus and arbitration.

As a consequence of the methodological nature of the studies, quantitative data analyses were only performed for eligible studies with adequate data. Due to study heterogeneity, small patient numbers and dearth of comparative studies, meta-analysis was not suitable; therefore data were pooled without formal statistical analysis.

### Results

Two-hundred and sixty-eight studies were identified, of which 121 were excluded: reviews (n=7), letters or commentaries (n=3), or those that did not specifically assess rectovaginal fistulae (n=111). 147 studies were assessable for abstract screening. Manual searching of references provided a further 22 studies, giving 169 studies for full evaluation. Of these, 143 were subsequently excluded as they did not satisfy the inclusion criteria and failed to provide adequate detail for data retrieval. Twenty-six studies were included in the systematic review.

### Study characteristics

Of the 26 eligible studies, 14 were prospective studies [32-45] and 12 were retrospective [46-57]. A total of 18 studies were either case reports or case series [32-34,40,44-57], four were non-randomised clinical trials [35-38], one was a multi-centre case series [42] and one was a single multi-centre randomised controlled trial [41] (Table 1 and Figure 1).

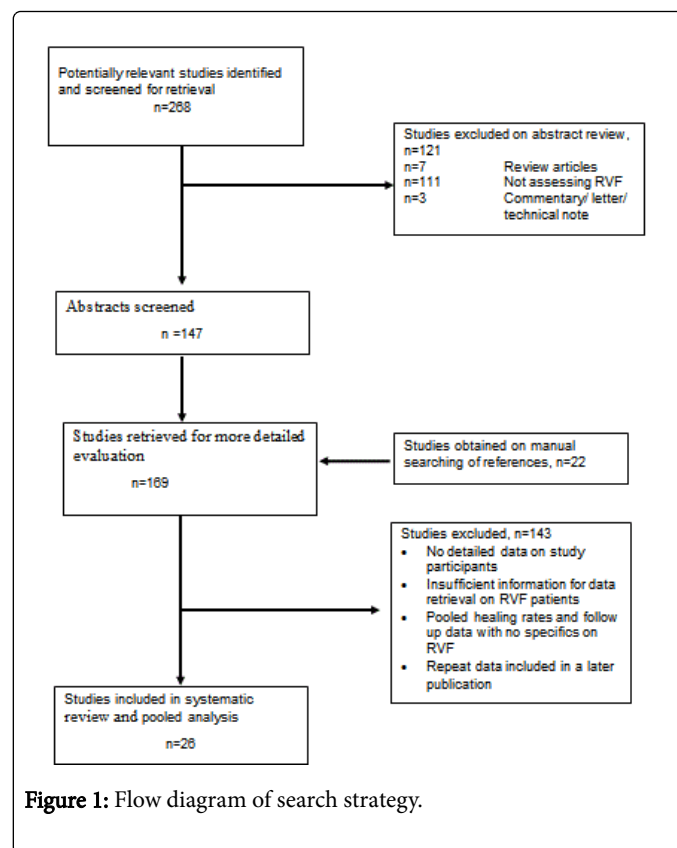


Figure 1: Flow diagram of search strategy.

Patient age ranged from 17-76 years with the mean follow up reported between 2 and 46 months. Most studies reported glue as the infill material under assessment either alone (n=16) or in combination with stem cells (n=1), or in comparison with a fistula plug (n=2). Four studies used plugs alone and one study compared fistula plug and mesh. Only one study reported the use of stem cells alone as the chosen infill material (Table 1).

Author	Year	Country	Type of Study	Prospective or Retrospective	Infill Material	F/U in months [mean]	F/U in months [range]	Follow up in months [median]	F/U in months [range]
Abel [32]	1993	USA	case series	Prospective	Glue	7.2	-	-	-
Venkatash [33]	1999	USA	case series	Prospective	Glue	-	Sep-57	-	-
Aitola [34]	1999	Finland	case series	Prospective	Glue	6	-	-	-
Cintron [35,36]	2000	USA	clinical trial-non randomised	Prospective	Glue	12	-	-	-
Park [36]	2000	USA	clinical trial-non randomised	Prospective	Glue	6	-	-	-

Halverson [46]	2001	USA	case series	Retrospective	Glue	-	-	4	Jan-25
Buchanan [37]	2003	UK	clinical trial-non randomised	Prospective	Glue	-	-	14	-
Loungnarath [47]	2004	USA	case series	Retrospective	Glue	-	-	23	Jun-36
Garcia-Olmo [38]	2005	Spain	clinical trial-non randomised	Prospective	Stem Cells	22	Dec-30	-	-
Singer [39]	2005	USA	RCT	Prospective	Glue	-	23-28	-	-
Ellis [48]	2008	USA	case series	Retrospective	Plug and Mesh	12	Jun-22	-	-
Alexander [40]	2008	Netherlands	case series	Prospective	Glue	-	-	-	-
Garcia-Olmo[41]	2009	Spain	Multi-centre RCT	Prospective	Glue and Stem Cells	12	-	-	-
Thekkinkattil [42]	2009	UK & Netherlands	Multi-centre case series	Prospective	Plug	-	Mar-18	-	-
Safar [49]	2009	USA	case series	Retrospective	Plug	4	-	-	-
El-Gazzaz [50]	2010	USA	case series	Retrospective	Glue and Plug	-	-	44.6	13.1-79.1
El-Gazzaz [51]	2010	USA	case series	Retrospective	Glue	45.8	-	-	-
Grimaud [43]	2010	France	Multi-centre RCT	Prospective	Glue	2	01-Mar	-	-
De Parades [52]	2010	France	case series	Retrospective	Glue	11.7	0.2-33.5	-	-
Gaertner [53]	2011	USA	case series	Retrospective	Glue and Plug	38.6	-	-	-
Gajsek [44]	2011	UK	case series	Prospective	Plug	-	-	118	81.5-129
Kleif [54]	2011	Denmark	case series	Retrospective	Plug	-	02-Aug	-	-
Choi [55]	2012	USA	case series	Retrospective	Glue	9.2	-	-	-
Garcia [56]	2012	USA	case report	Retrospective	Glue	6	6	-	-
Sileri [45]	2012	Italy	case series	Prospective	Permacol Paste	-	Mar-36	-	-
Binda [57]	2013	Italy	case report	Retrospective	Glue	12	-	-	-

**Table 1:** Study characteristics.

### Patient characteristics

In total, 105 patients underwent treatment for RVF using infill material, of which 28 patients (27%) had Crohn's Disease. Overall, 59 (57%) patients had treatment with glue, 33 (31%) with a plug, six (6%) with permacol paste and seven (7%) with stem cells. Within the Crohn's group, the majority were treated with glue (n=14; 50%), in 11 a fistula plug was used (n=11/28, 39%) and three had stem cells (n=3/28, 11%).

Eleven studies used a single dose of Pre-operative antibiotics at induction of anaesthesia, one used antibiotics during the peri-operative period, and two used antibiotics Post-operatively. One study used antibiotics both pre and Post-operatively.

A further two studies used antibiotics but did not specify at what time period, whilst two studies did not use antibiotics at all and six studies did not mention their use.

### Peri-operative management

**Antibiotic therapies:** Significant differences existed in the selected studies regarding peri-operative management and surgical technique (Table 2).

Author	N	Prior Seton drainage (Yes/No)	Bowel Prep (Yes/No)	Antibiotics	Fistula Tract Management	Peri-operative Management	Name of Material Used
--------	---	-------------------------------	---------------------	-------------	--------------------------	---------------------------	-----------------------

Abel	5	-	Yes	Pre-operative	Curettage	Post-operative oral intake restriction	Thrombinar
Choi	1	No	-	-	-	-	Fibrin Sealant
El-Gazzaz	2	-	-	Pre-operative	-	-	Glue
El-Gazzaz	1	-	-	Pre-operative	-	-	Plug
El-Gazzaz	7	-	-	Pre-operative	-	-	Glue
Ellis	7	05-Jul	No	Pre-operative	Nil	post operative laxatives, reduction in physical activity and sitz baths	Surgisis AFP - Cook
Gaertner	8	Yes	-	Peri-Operative	-	-	Glue
Gaertner	4	Yes	-	Peri-Operative	-	-	Plug
Gajsek	9	Yes	Yes	Pre-operative and Post-operative	Brush, Hydrogen Peroxide and Saline	post-operative antibiotics, laxatives and restriction to physical activity and intercourse	Surgisis Biodesign Button Plug - Cook
Garcia	1	-	Yes	-	-	post-operative low residue diet and no intercourse	BioGlue®, CryoLife,
Halverson	3	-	Yes	Yes	Curettage	-	Tisseel
Cintron	3	-	No	No	Curettage	nil	ViGuard-FS®
Garcia-Olmo	4	-	-	-	Curettage	nil	Tissucol Duotm, Baxter
Garcia-Olmo	4	-	-	-	Curettage	-	ASC, Cellerix, Spain; company code, Cx401
Garcia-Olmo	3	-	-	-	-	nil	ASC, Cellerix, Spain; company code, Cx401
Buchanan	1	-	No	Pre-operative	Curettage, Hydrogen Peroxide and Saline	nil	Tisseel™
Loungnarath	3	-	Yes	Pre-operative	Curettage	Liquid diet and no driving or sitting for 2 weeks	Tisseel®
Grimaud	3	-	Yes	-	Curettage	2 weeks of sexual abstinence	Beriplast + Trasylol
Alexander	1	-	Yes	Pre-operative	Curettage	5 day IV Metronidazole, immobilisation and liquid diet	BioGlue®
Venkatesh	8	-	Yes	Pre-operative	Curettage	48 hours liquids, 7 day antibiotics	Autologous fibrin
Thekkinkattil	9	-	Yes	Post-operative	Hydrogen Peroxide and Saline	Antibiotics and laxatives for 1 week, restrict activity	Surgisis® AFP™
Park	3	-	-	-	Curettage	-	ViGuard-F.S
Singer	1	-	Yes	No	Curettage	Not to have sitz baths, given laxatives	Tissucol®
Sileri	6	Yes	Yes	Yes	Curettage and Saline	-	Permacol (TM) Injection, Covidien plc.
Kleif	1	Yes	Yes	Pre-operative	Brush, Hydrogen Peroxide and Antibiotics	Bed rest 24 hrs, restrict activity and no intercourse 2 weeks	Surgisis AFP
Safar	1	-	Yes	Pre-operative	Hydrogen Peroxide	Restrict activity, topical antibiotics for 10 days	Surgisis AFP
De Parades	5	Yes	Yes	Pre-operative	Curettage and Saline	Immobilisation in theatre for 15 mins, Post-operative antibiotics, restrict activity and no intercourse	Tissucol

Binda	1	Yes	-	Post-operative	Curettage and Hydrogen Peroxide	-	Gore BioA
-------	---	-----	---	----------------	---------------------------------	---	-----------

**Table 2:** Perioperative management.

**Tract management:** Over half of the studies (n=15/26) used curettage of the fistula tract, either alone or in conjunction with either saline or hydrogen peroxide. Two studies used a brush in the tract in conjunction with hydrogen peroxide. In one of these studies antibiotics were also applied to the fistula tract.

**Primary outcomes**

Fistula healing was assessed clinically only in all but two studies. In these two studies, MRI was used to determine resolution of the tract in addition to clinical healing [36,56]. The overall fistula “healing” rate with all available infill materials was 41% (n=43/105) with the highest

rate being amongst those receiving stem cells therapy (n=5/7, 71%), followed by permacol paste (67%, n=4/6) although it is important to note that the number of included patients is small (Tables 3 and 4). Fibrin glue was associated with the poorest healing rate of 32% (n=19/59). Within the Crohn’s population, the overall healing rate was lower (n=10/28, 36%). Glue had the lowest healing rates with 2/14 patients healed (14%), followed by the anal fistula plug (n=6/11, 55%). The use of stem cells yielded a healing rate of 67% (n=2/3), although it is important to note the small number of patients included in the Crohn’s group.

Author	Year	Material	N	Age Range	IO management	All patient's healed (N)	All patients healed (%)	Crohn's (N)	Crohn's Healed (N)*	Crohn's Healed (%)
Abel	1993	Glue	5	25-48	-	04-May	80	1	0/1	0%
Venkatesh	1999	Glue	8	22-69	-	06-Aug	75	6	0/6	0%
Cintron	2000	Glue	3	30-50	-	01-Mar	33	-	-	-
Park	2000	Glue	3	28-53	-	01-Mar	33	-	-	-
Halverson	2001	Glue	3	27.4-46.6	2 MAF, 1 suture	01-Mar	33	-	-	-
Buchanan	2003	Glue	1	44	-	0/1	0	-	-	-
Loungnarath	2004	Glue	3	20-76	-	01-Mar	33	-	-	-
Singer	2005	Glue	1	41	-	0/1	0	-	-	-
Garcia-Olmo	2005	Stem Cells	3	35-40	suture + MAF	2	66	3	01-Mar	33%
Alexander	2008	Glue	1	46	suture + MAF	0/1	0	-	-	-
Ellis	2008	Plug	7	17-48	suture	06-Jul	86	5	4	80%
Garcia-Olmo	2009	Glue	4	33-51	suture	03-Apr	75	-	-	-
Garcia-Olmo	2009	Glue & Stem Cells	4	41-53	suture	0/4	0	-	-	-
Thekkinkattil	2009	Plug	9	18-65	suture	02-Sep	22	-	-	-
Safar	2009	Plug	1	46	suture	0/1	0	1	0	0%
El-Gazzaz	2010	Glue	2	40-44	-	01-Feb	50	2	1	50%
El-Gazzaz	2010	Glue	1	40-44	-	0/1	0	1	0	0%
El-Gazzaz	2010	Glue	7	32.8-52.8	suture	03-Jul	43	-	-	-
Grimaud	2010	Glue	3	27-41	-	0/3	0	3	0	0%
De Parades	2010	Plug	5	22.8-69.1	-	0	0	-	-	-
Kleif	2011	Permacol Paste	1	44	suture + MAF	0/1	0	-	-	-
Gaertner	2011	Plug	4	39	-	02-Apr	0	4	02-Apr	50%

Gaertner	2011	Glue	8	39	-	0/8	50	8	0	-
Gajsek	2011	Glue	9	32-45	suture	04-Sep	44	9	4	44%
Choi	2012	Glue	1	33	-	0/1	0	-	-	-
Garcia	2012	Glue	1	45	-	01-Jan	100	-	-	-
Sileri	2012	Plug	6	22-75	EAF	04-Jun	67	-	-	-
Binda	2013	Glue	1	46	suture	01-Jan	100	-	-	-

**Table 3:** Patient demographics and outcomes. IO=Internal opening (of fistula tract), MAF=Mucosal advancement flap, EAF=Endorectal advancement flap, -Blank spaces denote information unavailable from the papers, \*Data on concomitant medical therapy is not available for all studies.

Pooled healing rates - all patients			
Material	Total (N)	Healed (N)	Healed (%)
Glue Healing	59	19	32%
Plug Healing	33	15	46%
Permacol Healing	6	4	67%
Stem Cell Healing	7	5	71%
TOTAL	105	43	41%
Crohn's subgroup healing rates			5
Material	Total (N)	Healed (N)	Healed (%)
Glue	14	2	14%
Plug	11	6	54%
Stem Cells	3	2	67%
Total	28	10	36%

**Table 4:** Pooled analysis of healing rates, overall and in the Crohn's subgroup.

## Discussion

Many studies have reported the outcomes using infill materials in the management of anal fistulae but few have considered rectovaginal fistulae. The difficulty in reproducing the early high anal fistula healing rates using fibrin glue and the anal fistula plug has been reiterated in reports assessing their role in rectovaginal fistula. To date, the overall healing rate when all infill materials are considered has been around 41%. In the Crohn's patients with recto-vaginal fistulae, the overall healing rate was 36%.

The reasons for treatment failure are multifactorial. Fistula aetiology clearly plays an important role. Crohn's fistulae are more refractory to therapies. El Gazaz et al identified smoking and steroid use to be associated with lower healing rates, whereas immunomodulator use assisted healing [50]. The same group published in a separate study on obstetric and cryptoglandular rectovaginal fistulae that a higher body mass index (BMI), in addition to the number of previous attempts at repair, reduced fistula healing rates. Patient age, smoking status and other comorbidities exerted no obvious effect upon fistula healing [51].

Some of the limitations of this systematic review are the small numbers included in some of the studies, which make positive healing results seem significant. Researchers have to bear in mind that the results of pilot and feasibility studies although encouraging, should be taken with the limitations of small sample numbers in mind. Healing was seen in 67% and 71% of the permacol and stem cell groups respectively for all patients [41,45,38]. In the Crohn's cohort, 67% of patients healed using stem cells. However, as highlighted above, the sample numbers were rather small for these studies and therefore the results should be interpreted with that limiting factor in mind.

The existing literature has significant limitations, including variability in follow up duration, which has been as short as two months, and the assumption that clinical healing alone reflects true healing without verification using suitable imaging modalities. Only two studies have reported the use of MRI as part of the assessment of healing of anal fistulae [36,56]. Although radiological healing rates of rectovaginal fistulae were not specifically addressed in those studies, it was reported for transphincteric fistulae that skin healing was identified as early as two weeks after treatment in 77% of patients, yet only 3% of those patients remained asymptomatic at 14 months or healed at 16 months [36].

In order to optimise fistula healing rates, surgeons may find it beneficial to consider each component of the fistula tract and the underlying pathology, and even employ a multimodal approach. The internal opening, the fistula tract itself, and any secondary extensions all need management. Some argue that removing granulation tissue, epithelial lining and surrounding fistula tract tissue might favour wound healing.

The operative management of the internal opening and fistula tract varied between the studies in this systematic review. A simple 'figure of eight' suture was placed before or after the instillation of the chosen infill materials. Some studies combined this with the use of a mucosal advancement flap and in one study an endorectal advancement flap was used. A number of studies were excluded if more extensive surgery was reported, as it is unclear whether the reported healing rates were due to the use of a specific infill material or due to the surgical management of the internal opening. Similarly, the fistula tract management varied widely, with some surgeons advocating curettage whereas others advised against it; some used a brush to deal with the granulation tissue and others washed with either saline or hydrogen peroxide. No consensus was found regarding bowel preparation, peri-operative antibiotics, restriction in physical activity and sexual intercourse, or the use of sitz baths. The evidence is limited by the

diversity of study designs and the low quality of the published literature in this area.

An appropriate and durable biological material has the potential to fill in the defect and act as a scaffold for the delivery of cells, be they fibroblasts or stem cells. Animal studies show that fibrin glue is an unsuitable material for use and as an alternative collagen paste may act as a better infill material as well as a vehicle for the delivery of cells and drugs [45,57]. Rectovaginal fistulae pose an additional challenge regarding the choice of infill material, as the tracts are short and more difficult to manage with a lower chance of success. Nevertheless, the use of the anal fistula plug was supported in the Anal Fistula Plug (AFP) consensus statement in 2007. A Consensus conference was held in Chicago to develop uniformity of opinion from 15 experienced surgeons with first-hand experience of using the AFP, five of whom had success rates as high as 85% in 50 or more cases each. The expert panel felt that transphincteric fistulae were the optimal indication for the use of the plug. For ano/recto-vaginal fistulae, it was felt that due to the short tract it was less likely that the plug would be successful. However, the plug was still felt to be a reasonable alternative to other operative options. It is also important to note that all 15 surgeons acknowledged that they had received full payment and honoraria by the AFP designers to produce such a consensus statement [58].

Management of fistulae with autologous stem cells represent a novel approach which might yield promising results in the future. Only one group have published in this area [57], with very small numbers of rectovaginal fistulae, but encouraging healing rates. Whether a combination of stem cells and an infill material as a vehicle alters outcome remains to be determined.

Another potentially novel scaffold for fistula repair and drug delivery material is the poly-porous microsphere. Such microspheres have yet to be used in the treatment of rectovaginal fistulae, and their retention at the fistula site may pose difficulties, but animal models have provided promising results. An animal model using poly-porous (D,L-lactide-co-glycolide) microspheres containing either antibacterial silver-releasing degradable phosphate glass or metronidazole has shown that they may be a potentially useful scaffold for guided tissue regeneration and for local drug delivery [59].

Fistula trials, such as the FIAT [60] randomised controlled trial, are currently recruiting to assess the safety and efficacy of the Surgisis® anal fistula plug in high transphincteric anal fistulae. The outcome measures include fistula healing rates, faecal incontinence, quality of life and cost effectiveness. Conceivably, a similar study that includes radiological verification of healing and quality of sexual function might be designed for the much rarer recto-vaginal fistulae so that we can better evaluate the role of infill materials in this challenging condition.

This systematic review summarises the evidence with regards the use of infill materials as management options when treating rectovaginal fistulae. Patients are more aware of the variety of surgical options available, and may choose simpler options over more invasive alternatives [61]. Patients with Crohn's disease have limited options including medical treatment in the form of immunomodulators +/- anti-TNF therapy, but some may still require proctectomy [62]. Overall healing rates of 41% for rectovaginal fistula patients, or 36% for the patients with Crohn's disease, may be an acceptable option when the alternative could be major surgery or a stoma.

## References

1. Bangser M (2006) Obstetric fistula and stigma. *Lancet* 367: 535-536.
2. Fenner DE, Genberg B, Brahma P, Marek L, DeLancey JO (2003) Fecal and urinary incontinence after vaginal delivery with anal sphincter disruption in an obstetrics unit in the United States. *Am J Obstet Gynecol* 189: 1543-1549.
3. Signorello LB, Harlow BL, Chekos AK, Repke JT (2000) Midline episiotomy and anal incontinence: retrospective cohort study. *BMJ* 320: 86-90.
4. Venkatesh KS, Ramanujam PS, Larson DM, Haywood MA (1989) Anorectal complications of vaginal delivery. *Dis Colon Rectum* 32: 1039-1041.
5. Cohen JL, Stricker JW, Schoetz DJ, Collier JA, Veidenheimer MC (1989) Rectovaginal fistula in Crohn's disease. *Dis Colon Rectum* 32: 825-828.
6. Shobeiri SA, Quiroz L, Nihira M (2009) Rectovaginal fistulography: a technique for the identification of recurrent elusive fistulae. *Int Urogynecol J Pelvic Floor Dysfunct* 20: 571-573.
7. Tozer PJ, Balmforth D, Kayani B, Rahbour G, Hart AL, et al. (2013) Surgical management of rectovaginal fistula in a tertiary referral centre: many techniques are needed. *Colorectal Dis* 15: 871-877.
8. Rahman MS, Al-Suleiman SA, El-Yahia AR, Rahman J (2003) Surgical treatment of rectovaginal fistula of obstetric origin: a review of 15 years' experience in a teaching hospital. *Journal of obstetrics and gynaecology. J Obstet Gynaecol* 23: 607-610.
9. Ayhan A, Tuncer ZS, Dogan L, Pekin S, Kisinisci HA (1995) Results of treatment in 182 consecutive patients with genital fistulae. *Int J Gynaecol Obstet* 48: 43-47.
10. Tancer ML, Lasser D, Rosenblum N (1990) Rectovaginal fistula or perineal and anal sphincter disruption, or both, after vaginal delivery. *Surg Gynecol Obstet* 171: 43-46.
11. Mazier WP, Senagore AJ, Schiesel EC (1995) Operative repair of anovaginal and rectovaginal fistulas. *Dis Colon Rectum* 38: 4-6.
12. Watson SJ, Phillips RK (1995) Non-inflammatory rectovaginal fistula. *Br J Surg* 82: 1641-1643.
13. Chew SS, Rieger NA (2004) Transperineal repair of obstetric-related anovaginal fistula. *Aust N Z J Obstet Gynaecol* 44: 68-71.
14. Lowry AC, Thorson AG, Rothenberger DA, Goldberg SM (1988) Repair of simple rectovaginal fistulas. Influence of previous repairs. *Dis Colon Rectum* 31: 676-678.
15. Tsang CB, Madoff RD, Wong WD, Rothenberger DA, Finne CO, et al. (1998) Anal sphincter integrity and function influences outcome in rectovaginal fistula repair. *Dis Colon Rectum* 41: 1141-1146.
16. Khanduja KS, Yamashita HJ, Wise WE, Aguilar PS, Hartmann RF (1994) Delayed repair of obstetric injuries of the anorectum and vagina. A stratified surgical approach. *Dis Colon Rectum* 37: 344-349.
17. Zimmerman DD, Gosselink MP, Briel JW, Schouten WR (2002) The outcome of transanal advancement flap repair of rectovaginal fistulae is not improved by an additional labial fat flap transposition. *Techniques in coloproctology* 6: 37-42.
18. Pearl RK, Andrews JR, Orsay CP, Weisman RI, Prasad ML, et al. (1993) Role of the seton in the management of anorectal fistulas. *Dis Colon Rectum* 36: 573-577.
19. White RA, Eisenstat TE, Rubin RJ, Salvati EP (1990) Seton management of complex anorectal fistulas in patients with Crohn's disease. *Dis Colon Rectum* 33: 587-589.
20. Scott HJ, Northover JM (1996) Evaluation of surgery for perianal Crohn's fistulas. *Dis Colon Rectum* 39: 1039-1043.
21. Williams JG, Rothenberger DA, Nemer FD, Goldberg SM (1991) Fistula-in-ano in Crohn's disease. Results of aggressive surgical treatment. *Dis Colon Rectum* 34: 378-384.
22. Sher ME, Bauer JJ, Gelernt I (1991) Surgical repair of rectovaginal fistulas in patients with Crohn's disease: transvaginal approach. *Dis Colon Rectum* 34: 641-648.

23. Sonoda T, Hull T, Piedmonte MR, Fazio VW (2002) Outcomes of primary repair of anorectal and rectovaginal fistulas using the endorectal advancement flap. *Dis Colon Rectum* 45: 1622-1628.
24. Sangwan YP, Schoetz DJ, Murray JJ, Roberts PL, Collier JA (1996) Perianal Crohn's disease. Results of local surgical treatment. *Dis Colon Rectum* 39: 529-535.
25. Michelassi F, Melis M, Rubin M, Hurst RD (2000) Surgical treatment of anorectal complications in Crohn's disease. *Surgery* 128: 597-603.
26. Hyman N (1999) Endoanal advancement flap repair for complex anorectal fistulas. *Am J Surg* 178: 337-340.
27. Makowiec F, Jehle EC, Becker HD, Starlinger M (1995) Clinical course after transanal advancement flap repair of perianal fistula in patients with Crohn's disease. *Br J Surg* 82: 603-606.
28. Yassin NA, Hammond TM, Lunniss PJ, Phillips RK (2013) Ligation of the intersphincteric fistula tract in the management of anal fistula. A systematic review. *Colorectal Dis* 15: 527-535.
29. Lewis R, Lunniss PJ, Hammond TM (2012) Novel biological strategies in the management of anal fistula. *Colorectal Dis* 14: 1445-1455.
30. Liberati A, Altman DG, Tetzlaff J, Mulrow C, Gotzsche PC, et al. (2003) The PRISMA statement for reporting systematic reviews and meta-analyses of studies that evaluate healthcare interventions: explanation and elaboration. *BMJ* 339: b2700.
31. Wells BS, O'Connell D, Peterson J, Welch V, Losos M, et al. (2000) The Newcastle-Ottawa Scale (NOS) for assessing the quality of nonrandomised studies in meta-analyses. 3rd Symposium on Systematic Reviews: Beyond the Basics 3-5.
32. Abel ME, Chiu YS, Russell TR, Volpe PA (1993) Autologous fibrin glue in the treatment of rectovaginal and complex fistulas. *Dis Colon Rectum* 36: 447-449.
33. Venkatesh KS, Ramanujam P (1999) Fibrin glue application in the treatment of recurrent anorectal fistulas. *Dis Colon Rectum* 42: 1136-1139.
34. Aitola P, Hiltunen KM, Matikainen M. Fibrin glue in perianal fistulae-a pilot study. *Ann Chir Gynaecol* 88: 136-138.
35. Cintron JR, Park JJ, Orsay CP, Pearl RK, Nelson RL, et al. (2000) Repair of fistulas-in-ano using fibrin adhesive: long-term follow-up. *Dis Colon Rectum* 43: 944-949.
36. Park JJ, Cintron JR, Orsay CP, Pearl RK, Nelson RL, et al. (2000) Repair of chronic anorectal fistulae using commercial fibrin sealant. *Arch Surg* 135: 166-169.
37. Buchanan GN, Bartram CI, Phillips RK, Gould SW, Halligan S, et al. (2003) Efficacy of fibrin sealant in the management of complex anal fistula: a prospective trial. *Dis Colon Rectum* 46: 1167-1174.
38. García-Olmo D, García-Arranz M, Herreros D, Pascual I, Peiro C, et al. (2005) A phase I clinical trial of the treatment of Crohn's fistula by adipose mesenchymal stem cell transplantation. *Dis Colon Rectum* 48: 1416-1423.
39. Singer M, Cintron J, Nelson R, Orsay C, Bastawrous A, et al. (2005) Treatment of fistulae-in-ano with fibrin sealant in combination with intra-adhesive antibiotics and/or surgical closure of the internal fistula opening. *Dis Colon Rectum* 48: 799-808.
40. Alexander SM, Mitalas LE, Gosselink MP, Oom DM, Zimmerman DD, et al. (2008) Obliteration of the fistulous tract with BioGlue adversely affects the outcome of transanal advancement flap repair. *Tech Coloproctol* 12: 225-228.
41. García-Olmo D, Herreros D, Pascual I, Pascual JA, Del-Valle E, et al. (2009) Expanded adipose-derived stem cells for the treatment of complex perianal fistula: a phase II clinical trial. *Dis Colon Rectum* 52: 79-86.
42. Thekkinkattil DK, Botterill I, Ambrose NS, Lundby L, Sagar PM, et al. (2009) Efficacy of the anal fistula plug in complex anorectal fistulae. *Colorectal Dis* 11: 584-587.
43. Grimaud JC, Munoz-Bongrand N, Sproudhis L, Abramowitz L, Sénéjoux A, et al. (2010) Fibrin glue is effective healing perianal fistulas in patients with Crohn's disease. *Gastroenterology* 138: 2275-2281, 2281.
44. Gajsek U, McArthur DR, Sagar PM (2011) Long-term efficacy of the button fistula plug in the treatment of ileal pouch-vaginal and Crohn's-related rectovaginal fistulas. *Dis Colon Rectum* 54: 999-1002.
45. Sileri P, Boehm G, Franceschilli L, Giorgi F, Perrone F, et al. (2012) Collagen matrix injection combined with flap repair for complex anal fistula. *Colorectal Dis* 14 Suppl 3: 24-28.
46. Halverson AL, Hull TL, Fazio VW, Church J, Hammel J, et al. (2001) Repair of recurrent rectovaginal fistulas. *Surgery* 130: 753-757.
47. Loungnarath R, Dietz DW, Mutch MG, Birnbaum EH, Kodner IJ, et al. (2004) Fibrin glue treatment of complex anal fistulas has low success rate. *Dis Colon Rectum* 47: 432-436.
48. Ellis CN (2008) Outcomes after repair of rectovaginal fistulas using bioprosthetics. *Dis Colon Rectum* 51: 1084-1088.
49. Safar B, Jobanputra S, Sands D, Weiss EG, Noguera JJ, et al. (2009) Anal fistula plug: initial experience and outcomes. *Dis Colon Rectum* 52: 248-252.
50. El-Gazzaz G, Hull T, Mignanelli E, Hammel J, Gurland B, et al. (2010) Analysis of function and predictors of failure in women undergoing repair of Crohn's related rectovaginal fistula. *J Gastrointest Surg* 14: 824-829.
51. El-Gazzaz G, Hull TL, Mignanelli E, Hammel J, Gurland B, et al. (2010) Obstetric and cryptoglandular rectovaginal fistulae: long-term surgical outcome; quality of life; and sexual function *J Gastrointest Surg* 14: 1758-1763.
52. de Parades V, Far HS, Etienney I, Zeitoun JD, Atienza P, et al. (2010) Seton drainage and fibrin glue injection for complex anal fistulas. *Colorectal Dis* 12: 459-463.
53. Gaertner WB, Madoff RD, Spencer MP, Mellgren A, Goldberg SM, et al. (2011) Results of combined medical and surgical treatment of rectovaginal fistula in Crohn's disease. *Colorectal Dis* 13: 678-683.
54. Kleif J, Hagen K, Wille-Jørgensen P (2011) Acceptable results using plug for the treatment of complex anal fistulas. *Dan Med Bull* 58: A4254.
55. Choi JM, Nguyen V, Khavari R, Reeves K, Snyder M, et al. (2012) Complex rectovaginal fistulae after pelvic organ prolapse repair with synthetic mesh: a multidisciplinary approach to evaluation and management. *Female Pelvic Medicine & Reconstructive Surgery* 18: 366-371.
56. Garcia S, Dissanaik S (2012) Case report: Treatment of rectovaginal fistula with Bioglue®. *Int J Surg Case Rep* 3: 327-329.
57. Binda GA, Piscitelli A, Longhin R (2013) Treatment of high ano-vaginal fistula with GORE BIO-A® Fistula Plug in an immunocompromised patient. *Tech Coloproctol* 17: 609-611.
58. (2008) The Surgisis AFP anal fistula plug: report of a consensus conference. *Colorectal Dis* 10: 17-20.
59. Blaker JJ, Pratten J, Ready D, Knowles JC, Forbes A, et al. (2008) Assessment of antimicrobial microspheres as a prospective novel treatment targeted towards the repair of perianal fistulae. *Aliment Pharmacol Ther* 28: 614-622.
60. Jayne D (2010) The Fistula-In-Ano Trial comparing Surgisis® anal fistula plug versus surgeon's preference (advancement flap, fistulotomy, cutting seton) for transsphincteric fistula-in-ano.
61. Ellis CN, Rostas JW, Greiner FG (2010) Long-term outcomes with the use of bioprosthetic plugs for the management of complex anal fistulas. *Dis Colon Rectum* 53: 798-802.
62. Hellers G, Bergstrand O, Ewerth S, Holmström B (1980) Occurrence and outcome after primary treatment of anal fistulae in Crohn's disease. *Gut* 21: 525-527.