

Therapeutic Plasmapheresis in Patients with Thyrotoxicosis. Report of Two Cases

Guillermo E Guzmán G*, Diego F Bautista R, Luis Guillermo Arango V, Lina M García M, Luz Ángela Casas F and Karen Milena Feriz

Fundacion Clinica Valle del Lili, Colombia

*Corresponding author: Guillermo E Guzmán, Fundacion Clinica Valle del Lili, Av Simón Bolívar Cra 98#18-49, Cali - Colombia, Tel: 57-2-33190907434; E-mail: guillermoequzhangomez@hotmail.com

Received date: May 24, 2015; Accepted date: August 13, 2015; Published date: August 25, 2015

Copyright: © 2015 Guzmán GE, et al. This is an open-access article distributed under the terms of the Creative Commons Attribution License, which permits unrestricted use, distribution, and reproduction in any medium, provided the original author and source are credited.

Abstract

Background: Therapeutic plasmapheresis (TPE) in patients with thyrotoxicosis increases the elimination of thyroid hormones and the dilution of the ones remaining in the plasma infusion.

Objectives: To describe two cases of patients with thyrotoxicosis, both scheduled for thyroidectomy and who received TPE via a pre-surgical preparation.

Methods: Case reports in which the characteristics of the individuals, plasmapheresis time, free thyroxine values during follow-up and successful surgical procedures were described.

Results: Two cases are presented. Both patients had agranulocytosis related to the use of methimazole. The first patient presented with Graves' disease and failed to reduce levels of free thyroxine (FT4) with TPE, even after two sessions. The second case describes a patient with toxic multi-nodular goiter, who had a good response to TPE: after 4 sessions, FT4 decreased by 33%.

Conclusion: TPE may be a successful therapeutic alternative as a bridge therapy in thyroidectomy in patients with severe hyperthyroidism that has been refractory to conventional treatment options.

Keywords: Plasmapheresis; Hyperthyroidism; Thyroid function test; Thyrotoxicosis

Introduction

Therapeutic plasmapheresis (TPE) is an extracorporeal blood purification technique in which blood removed from a patient can be separated into its various components, with selective removal of the full plasma. Special techniques allow high molecular weight substances, such as autoantibodies, immune complexes, cryoglobulins, hormones and immunoglobulins, to be removed from the plasma, followed by their replacement with human albumin or synthetic colloid and crystalloid solution [1]. Such substances are comparatively large and therefore suitable for hemofiltration, and they also have a long half-life, meaning that the extracorporeal removal is much faster than endogenous clearance [2].

Due to its ability to remove autoantibodies and immune complexes, TPE is indicated in autoimmune diseases, and also as an alternative therapy for fulminant hepatitis, agranulocytosis, vasculitis, skin rashes, and other diseases. The use of TPE in hyperthyroidism has been described for more than 25 years, for example in the treatment of iodine-induced thyrotoxicosis due to the rapid clearance of thyroid hormones (especially the portion bonded to plasma proteins) and the dilution of hormones remaining in the infusion of plasma, with the introduction of new binding sites of thyroid hormones (including albumin and other transport proteins) (Category III of the American Association of Blood Banks 2013) [3].

Here, the cases of two patients are described, both with thyrotoxicosis: one due to a toxic multi-nodular goiter and the other due to Graves' disease. Both patients had agranulocytosis related to the use of methimazole. For both patients, also, other treatment options had failed to achieve a euthyroid state; it was therefore decided to use TPE as a bridge therapy for thyroidectomy.

Subjects and Methods

Two cases of patients with thyrotoxicosis (due to a toxic multi-nodular goiter and Graves' disease) are described. Both patients required TPE as a bridge therapy for thyroidectomy. The demographic characteristics, symptoms on admission, physical examination findings, laboratory values before and after the TPE and the complications are described.

Results

Case 1

32-year old male patient with a 3-month history of hyperthyroidism due to Graves' disease; he was treated with up to 40 mg/day of methimazole and 80 mg/day of propranolol. He consulted for 15 days prior to the intervention, with palpitations, fever greater than 104°F, myalgia, arthralgia and hiporexia. In his physical examination upon admission, blood pressure of 130/90 mmHg; pulse, 125 beats/min.; body temperature, 102.5°F; respiratory rate, 19/min; oxygen saturation, 98% while he was breathing ambient air lower, bilateral

exophthalmos (less than 3 mm). He didn't had diarrhea, jaundice or abdominal pain and his Burch and Wartofsky score of 35, all of which suggested an impending thyroid storm. Thyroid function tests were performed with 0.005 IU/L of ultrasensitive Thyroid Stimulating Hormone (TSH) and 7.7 ng/dl of free thyroxine (FT4) (with a reference value of 0.8 to 1.7 ng/dL). Laboratory examinations were taken, showing a total white blood cell count of $3,250 \times 10^3/\text{mm}^3$, an absolute neutrophil count of 620 cells and a 1950 lymphocyte count. Infectious diseases that could explain the symptoms and laboratory findings were discarded, and it was considered that the hematological compromise was associated with the antithyroid medication, so methimazole was discontinued. Case management began with lithium carbonate (300 mg every 8 hours), 4g of cholestyramine every 12 hours, 100 mg of hydrocortisone every 8 hours, 80mg of propranolol every 8 hours and 14 drops of lugol every 6 hours. To allow assessment of the response to therapy thyrotropin levels were performed daily for three days however were found to be unchanged (Table 1). As the patient had recently undergone cranial Computed Tomography (CT) with contrast medium (less than a month ago) for headache, it was considered that iodine therapy was not a suitable treatment. It was decided that TPE was needed to quickly prepare the patient for thyroidectomy, but his FT4 measurement 6hrs post-TPE was unchanged. A second session of TPE was performed, again without achieving any reduction in his levels of FT4 and he was classified as non-responder to TPE. It was decided, therefore, that a total thyroidectomy would be performed. The patient had all medications until the day of surgery. By the time the surgery had started, he had a pulse less than 60 beats/min. Any surgery or cardiovascular complications was related. Improvement in thyroid function was achieved in the immediate post-operative period without any complications in the 2 weeks following the surgery. Antibody concentrations have not been determined after TPE. The patient was discharged at this point when their euthyroid state had reached an optimal condition.

Case 2

50 year old female patient, presenting with fatigue, weakness, anxiety, loss of approximately 5kg in weight, with no criteria for thyroid storm and with an initial TSH of <0.01 mIU/L, FT4 of 2.1 ng/dl, anti-TPO (thyroid microsomal) autoantibodies of 2 UI/l (with a negative reference value <4 IU/ml), antithyroglobulin antibodies of 6 IU/ml (with a negative reference value <100 IU/ml) and anti TSH-receptor antibodies weren't determined. An ultrasound of thyroid gland showed increase volume with multiple nodules in both lobes consistent with multinodular goiter (multiple nodules of the thyroid gland; left lobe nodules measuring $0.8 \times 0.6 \times 0.7$ cm and $0.5 \times 0.6 \times 0.3$ cm; and right lobe with 4 nodules with largest measuring $0.5 \times 0.6 \times 0.8$ cm without microcalcifications) and her gammagraph report showed Tc-99m pertechnetate uptake compatible with a hyperfunctioning multi-nodular goiter. It was established that the patient was a candidate for therapy with I-131, but as there were difficulties in the immediate availability of this; treatment was started with methimazole, up to 30mg of which was provided daily. During the third week after the start of the antithyroid medication, the patient entered the emergency department due to an exacerbation of her symptoms and a worsening of her thyroid function. He presented blood pressure of 120/80 mmHg; pulse, 110 beats/min and body temperature, 99.0°F . At this stage, her TSH was <0.001 mIU/L and FT4 was 3.33 ng/dl with total leukocytes of $2.210 \times 10^3/\text{mm}^3$, an absolute neutrophil count of 70 and a lymphocyte count of 1790. Hemoglobin

was 9.30 g/dl, hematocrit 28%, mean corpuscular volume 80 fl and mean corpuscular hemoglobin was 32 g/dL, with 407000 mm^3 platelets and a corrected reticulocyte of 0.4%. Therefore, methimazol adverse reaction was considered and it was discontinued. The patient had a soft tissue infection in her right arm for which she received antibiotic therapy. Due to persistent febrile neutropenia, therapy with granulocyte colony stimulating factor (filgrastim) was initiated and given the worsening of her thyroid function, with FT4 rising to 3.44 ng/dL, associated with symptoms, 100 mg of hydrocortisone was administered every 8 hours, 300 mg of lithium carbonate every 8 hours, 80 mg of propranolol every 6 hours and 4 g of cholestyramine every 12 hours. 678 mg/ml of ioversol, equivalent to 320 mg of iodine (OptirayTM), was administered via 4 ml (1280 mg of iodine) in a continuous infusion for 24 hours. After three days of treatment, FT4 levels were increased to 4.18 ng/dl, at which point it was decided to perform the thyroidectomy with pre-treatment with TPE. A first session was scheduled which achieved a reduction in FT4 of 18%, and an additional 3 sessions were performed, with a total reduction of 33%. At the time of surgery, she had blood pressure of 120/80 mmHg; pulse, 68 beats/min and FT4 value of 2.8 ng/dl. There were no complications during surgery or post-operatively (Figure 1).

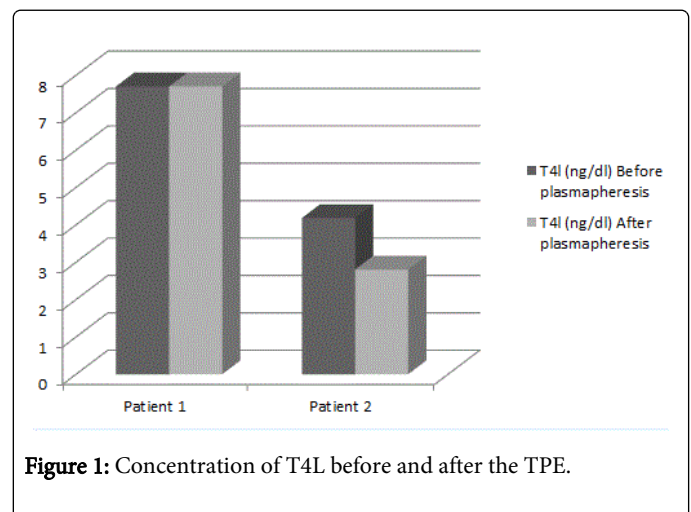


Figure 1: Concentration of T4L before and after the TPE.

Discussion

Antithyroids, radioactive iodine and surgical therapies are classic interventions for managing thyrotoxicosis [4]. Adverse reactions to drug therapy may, however, be frequent and serious to the point of threatening the life of patients, as in the cases described here. The use of antithyroids is associated with agranulocytosis in 0.2 to 1.75% of patients and is more frequent in patients who also use methimazole in the first 100 days of treatment [5-8]. Other treatment options, such as radioactive iodine (I-131) and surgery should therefore be considered in such cases. I-131 has several disadvantages, however: it fails to produce a euthyroid state immediately; its effect is greater when the FT4 is two or three times above the reference value; and it is necessary to continue with antithyroids, for up to 4-8 weeks after the I-131 therapy, in order to normalize thyroid function. Normally with an average dose of 15mci of I-131, 75% and 86% of patients are hypothyroid at 6 and 12 months respectively. The others are classified as refractory and require a new dose [4,9]. In a patient with severe hyperthyroidism who is in thyroid storm, or who is facing an imminent thyroid storm, options that achieve earlier therapeutic control are needed; in these cases thyroidectomy is indicated [4].

In a patient with uncontrolled hyperthyroidism, the goal is to minimize the risks before surgery. This is accomplished by bringing the patient to a euthyroid state or by decreasing the maximum levels of FT4 and FT3 [10]. If the proposed control is not achieved, mortality associated with surgery can be up to 46%. The surgical option should be considered for cases of persistent thyrotoxicosis complicated with heart, ventilatory or renal failure that have not responded to the appropriate treatment; in these cases acceptable results have been achieved with early mortality of 0%, and late mortality (at 3 weeks) being 20% [11].

During the preoperative preparation, beta-blockers are indicated, offered at the maximum tolerated dose [12], in order to achieve heart rates within normal limits, to control symptoms such as tremors and anxiety, and also to minimize the surgical risk. The use of lithium carbonate as a blocker of thyroid hormone synthesis, with doses of 900 to 1200 mg/day [13], has been demonstrated to be safe and efficacious, with varying results in the control of thyroid disease. Glucocorticoids (hydrocortisone, dexamethasone and methylprednisolone) also play an important role not only in decreasing the inflammatory response but also in inhibiting the peripheral conversion of T4 [4,9]. Finally, among the therapeutic options, there are solutions such as Lugol iodine and, also, contrast media [14].

The above strategies were used in the two cases presented, none of which gave results, and so TPE was used as a preparation for surgery in order to reduce thyroid function. TPE is indicated as an alternative therapy in refractory to medical management of hyperthyroidism and is preferred for the prevention of thyroid storm. In case 1, no change was achieved following TPE in terms of pre-surgical FT4 levels, while for case 2, a slow reduction in FT4 levels was achieved with each session of TPE. TPE is a safe strategy and is uncomplicated, during which it is necessary to provide fluid replacement with adequate monitoring. As described in the literature, the second case presented here show that TPE enables the risk of morbidity and mortality associated with uncontrolled hyperthyroidism to be controlled.

Autoimmune diseases are those that see the greatest benefits of TPE. The benefits of TPE go beyond solely decreasing the quantity of immune complexes in patients. In our case, for example, the best response to TPE was in a patient with a non-autoimmune disease. The success of TPE in this case was attributed to the dilution of hormones and the generation of free proteins with new binding sites, which reduced their free fractions and thus their biological activity [15-21]. While this is effective in the short-term, its effect is transient and so TPE cannot be used as definitive therapy. In an emergency or in the absence of response to other treatments, it is necessary, therefore, to resort to consolidation therapies such as thyroidectomy [3,22,23]. The therapy goal is not only to achieve a reduction in biochemical markers, however, but also to reduce the incidence of clinical outcomes such as thyroid storm and associated mortality.

It is still unclear why some patients achieve the maximum benefit from TPE, regardless of their etiology, that is the problem in our first case exposed with Graves's disease. To this day it is unclear which elements are responsible for determining patient response to TPE. At the moment, it is believed that the measurement of FT4, FT3 and anti thyroid (RTSH) antibodies is a good initial way to approach the problem. If no change is noted in the measurement of FT4 and FT3 at the sixth hour post therapy, there is no justification for an additional TPE session. It should be noted, however, that any reductions in FT4 and FT3 could have a minimum, according to the reductions previously reported, ranging from 8.3-64.9% for FT4 and from

22.2-88-9% for FT3 [22]. Nevertheless, make a decision based for any change of FT4, FT3 and anti thyroid (RTSH) antibodies has a poor level of evidence.

Conclusion

In cases when the patient is unresponsive to medical therapy or when such therapy is contraindicated, TPE could be useful for preparing patients with thyrotoxicosis for surgery. TPE is a safe procedure that allows the replacement of fluids with colloid solutions. It has preventable complications when used under appropriate clinical situations with adequate monitoring systems. There remain, however, many doubts about the use of TPE in thyroid disease, which should be clarified through clinical trials.

References

1. Restrepo CA, Márquez E, Sanz MF (2009) Plasmaféresis terapéutica, tipos, técnica e indicaciones en medicina interna. *Acta Med Colomb* 34: 23-32.
2. Ozbey N, Kalayoglu-Besik S, Gul N, Bozboru A, Sencer E, et al. (2004) Therapeutic plasmapheresis in patients with severe hyperthyroidism in whom antithyroid drugs are contraindicated. *Int J Clin Pract* 58: 554-558.
3. Winters JL; American Society for Apheresis (2014) American Society for Apheresis guidelines on the use of apheresis in clinical practice: practical, concise, evidence-based recommendations for the apheresis practitioner. *J Clin Apher* 29: 191-193.
4. Bahn Chair RS, Burch HB, Cooper DS, Garber JR, Greenlee MC, et al. (2011) Hyperthyroidism and other causes of thyrotoxicosis: management guidelines of the American Thyroid Association and American Association of Clinical Endocrinologists. *Thyroid* 21: 593-646.
5. Andersohn F, Konzen C, Garbe E (2007) Systematic review: agranulocytosis induced by nonchemotherapy drugs. *Ann Intern Med* 146: 657-665.
6. Cepkova J, Gabalec F, Svilius I, Horacek J (2014) The occurrence of agranulocytosis due to antithyroid drugs in a cohort of patients with Graves' disease treated with radioactive iodine 131I during 14 years. *Vnitř Lek* 60: 832-6.
7. Tsuboi K, Ueshiba H, Shimojo M, Ishikawa M, Watanabe N, et al. (2007) The relation of initial methimazole dose to the incidence of methimazole-induced agranulocytosis in patients with Graves' disease. *Endocr J* 54: 39-43.
8. Cooper DS, Goldminz D, Levin AA, Ladenson PW, Daniels GH, et al. (1983) Agranulocytosis associated with antithyroid drugs. Effects of patient age and drug dose. *Ann Intern Med* 98: 26-29.
9. Alexander EK, Larsen PR (2002) High dose of (131)I therapy for the treatment of hyperthyroidism caused by Graves' disease. *J Clin Endocrinol Metab* 87: 1073-1077.
10. Baeza A, Aguayo J, Barria M, Pineda G (1991) Rapid preoperative preparation in hyperthyroidism. *Clin Endocrinol (Oxf)* 35: 439-442.
11. Scholz GH, Hagemann E, Arkenau C, Engelmann L, Lamesch P, et al. (2003) Is there a place for thyroidectomy in older patients with thyrotoxic storm and cardiorespiratory failure? *Thyroid* 13: 933-940.
12. Trzepacz PT, Klein I, Roberts M, Greenhouse J, Levey GS (1989) Graves' disease: an analysis of thyroid hormone levels and hyperthyroid signs and symptoms. *Am J Med* 87: 558-561.
13. Takami H (1994) Lithium in the preoperative preparation of Graves' disease. *Int Surg* 79: 89-90.
14. Panzer C, Beazley R, Braverman L (2004) Rapid preoperative preparation for severe hyperthyroid Graves' disease. *J Clin Endocrinol Metab* 89: 2142-2144.
15. Enghofer M, Badenhop K, Zeuzem S, Schmidt-Matthiesen A, Betz C, et al. (2000) Fulminant hepatitis A in a patient with severe hyperthyroidism: rapid recovery from hepatic coma after plasmapheresis and total thyroidectomy. *J Clin Endocrinol Metab* 85: 1765-9.

16. Schlienger JL, Faradji A, Sapin R, Blicke JF, Chabrier G, et al. (1985) [Treatment of severe hyperthyroidism by plasma exchange. Clinical and biological efficacy. 8 cases]. *Presse Med* 14: 1271-1274.
17. Ashkar FS, Katims RB, Smoak WM 3rd, Gilson AJ (1970) Thyroid storm treatment with blood exchange and plasmapheresis. *JAMA* 214: 1275-1279.
18. De Rosa G, Testa A, Menichella G, Cecchini L, Cavallaro A, et al. (1991) Plasmapheresis in the therapy of hyperthyroidism associated with leukopenia. *Haematologica* 76 Suppl 1: 72-74.
19. Braithwaite SS, Brooks MH, Collins S, Bermes EW (1986) Plasmapheresis: an adjunct to medical management of severe hyperthyroidism. *J Clin Apher* 3: 119-123.
20. Glinoe D, Etienne-Decerf J, Schrooyen M, Sand G, Hoyoux P, et al. (1986) Beneficial effects of intensive plasma exchange followed by immunosuppressive therapy in severe Graves' ophthalmopathy. *Acta Endocrinol (Copenh)* 111: 30-8.
21. Bartalena L, Marcocci C, Pinchera A (1997) Treating severe Graves' ophthalmopathy. *Baillieres Clin Endocrinol Metab* 11: 521-536.
22. Ezer A, Caliskan K, Parlakgumus A, Belli S, Kozanoglu I, et al. (2009) Preoperative therapeutic plasma exchange in patients with thyrotoxicosis. *J Clin Apher* 24: 111-114.
23. Binimelis J, Bassas L, Marruecos L, Rodriguez J, Domingo ML, et al. (1987) Massive thyroxine intoxication: evaluation of plasma extraction. See comment in PubMed Commons below *Intensive Care Med* 13: 33-38.