

## Thrombotic Microangiopathy and Low ADAMTS 13

Zakaria Almuwaqqat\*, Saad Ali, Abduljalil Elfasi, Harvey Freidman and Afsin Oktay

Department of Internal Medicine, St. Francis Hospital, USA

\*Corresponding author: Zakaria Almuwaqqat, Internal Medicine Resident, Presence St. Francis Hospital, Internal Medicine, 333 Ridge ave, Evanston, IL 60202, USA, Tel: 2038247207; E-mail: [zalmuwaqqat@gmail.com](mailto:zalmuwaqqat@gmail.com)

Received date: Jul 11, 2015; Accepted date: Sep 01, 2015; Published date: Sep 03, 2015

Copyright: © 2015 Almuwaqqat Z, et al. This is an open-access article distributed under the terms of the Creative Commons Attribution License, which permits unrestricted use, distribution, and reproduction in any medium, provided the original author and source are credited.

### Abstract

**Background:** Thrombotic Microangiopathy (TMA) is a multi-organ dysfunction syndrome characterized by microvascular thrombosis, thrombocytopenia and hemolytic anemia with diverse etiologies ranging from primary Thrombotic thrombocytopenic purpura (TTP) and Hemolytic uremic syndrome (HUS) to secondary phenomena to medications, severe uncontrolled hypertension and autoimmune disorders i.e Scleroderma renal crises, catastrophic antiphospholipid syndrome and pre-eclampsia, prompt diagnosis, identification of potential etiologies and treatment are essential steps for reducing morbidity and mortality.

**Case Report:** We describe a case of a 34-year-old man who presented with features of advanced renal impairment, severe uncontrolled hypertension and thrombotic microangiopathy, overall clinical picture was most consistent with malignant hypertension and hypertensive nephrosclerosis secondary to long standing uncontrolled hypertension, however a serum test ordered measuring the activity of ADAMTS 13 (a disintegrin and metalloproteinase with a thrombospondin type 1 motif, member 13) resulted one week later was consistent with reduced enzyme activity, challenging the first diagnosis.

**Conclusions:** Clinical correlation and high index of suspicion are essential in the diagnosis and management of thrombotic microangiopathy, The reduction in ADAMTS -13 activity or antigen level has been thought to be a primary cause of thrombotic microangiopathies i.e TTP and HUS, however recent studies have shown a negative correlation between ADAMTS-13 activity and elevated blood pressure (BP) in malignant hypertension.

**Keywords:** ADAMTS; Malignant hypertension; VwF protease; TTP; HUS

### Introduction

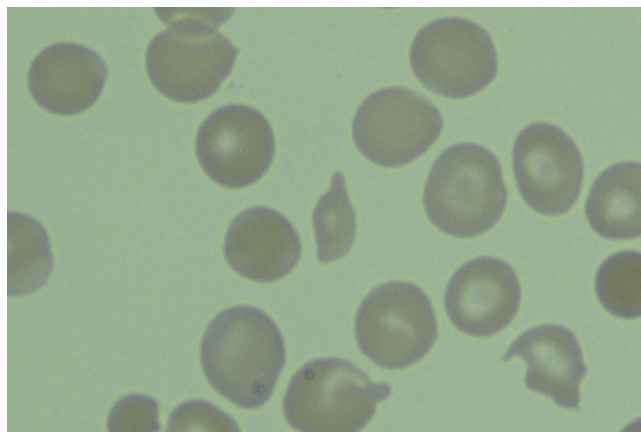
Thrombotic Microangiopathy (TMA) due to presumed Thrombotic Thrombocytopenic purpura (TTP) was first described by Dr. Moschcowitz in New York City in 1925 in a 16-year-old girl who had anemia, petechial purpura, microscopic hematuria, and, at autopsy, disseminated microvascular thrombi [1], TMAs secondary to other etiologies share similar features with TTP and diagnosis can be challenging sometimes given the fact that TTP is a rare but life threatening disease that requires urgent plasmapheresis, this case highlights the role of ADAMTS-13 (a disintegrin and metalloprotease with thrombospondin motifs) in the pathogenesis of severe uncontrolled hypertension and its utility in the diagnosis of TMAs.

### Case Report

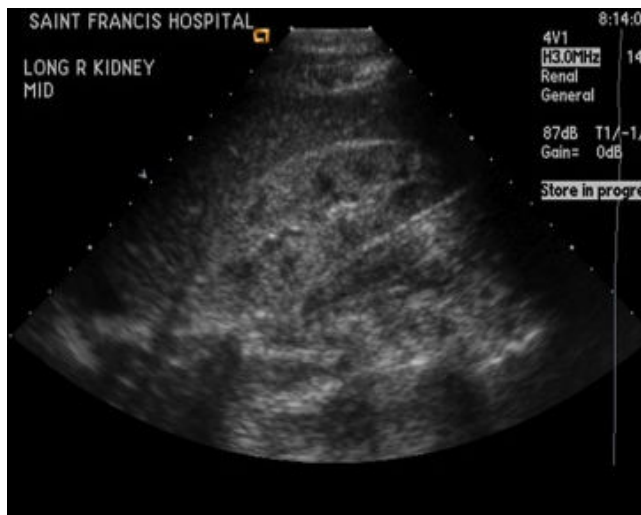
A 34 year-old Haitian native male presented to the Emergency department with several weeks symptoms of headache, nausea, vomiting and blurry vision as well as worsening generalized weakness and reports of personal and strong family history of hypertension in his first degree relatives, Blood pressure on presentation was 274/169 mm Hg, physical examination revealed an intact mental status and non-focal neurological exam, absence of meningeal sign, dilated fundus exam revealed optic disc edema, lungs were clear, cardiovascular exam revealing regular normal heart sounds S1/S2 (normal) with S4 (+), his abdomen was Soft, non-tender, his lower

extremities were warm without pretibial edema. Laboratory tests showed serum creatinine of 24.5 mg/dl (0.4- 1.4 mg/dl), BUN 138 mg/dl (10-25 mg/dl), hemoglobin 10.5 g/dl, WBC 8.5, platelet count of 80K, LDH 661 (international Unit per liter) IU/L, haptoglobin <30 mg/dl (30-200), peripheral smear showing numerous schistocytes, negative ANA (Antinuclear antibody) screen, negative scleroderma screen, normal complement C3 and C4, urine analysis with +1 protein, no RBC or WBC casts, X ray chest, CT (computerized tomography) head - normal, Echo: concentric LVH, LVEF (Left ventricular ejection fraction) 72% (Figure 1). Renal ultrasound (US): bilateral small kidneys (8 cm) with decreased cortico-medullary differentiation consistent with chronic renal disease. Patient was admitted to the intensive care unit with the diagnosis of severe uncontrolled Hypertension (HTN) and chronic kidney disease (CKD) (Figure 2). Blood pressure (BP) was controlled with intravenous (IV) labetalol infusion to achieve 25% reduction in Mean BP (MAP) within the first 24 hours, hemodialysis catheter insertion was complicated by bleeding requiring Desompressin (DDAVP) (1-desamino-8-D-arginine vasopressin) IV 0.3 µg/kg once and one unit of single donor platelet transfusion and one unit of packed RBCs on the second day of hospitalization. Given that TMA accompanied by renal failure and severe uncontrolled hypertension with evidence of chronic renal disease on renal ultrasonography diagnosis of stage 5 CKD (chronic kidney disease) with malignant hypertension was the primary diagnosis, biopsy was relatively contraindicated given the uncontrolled hypertension and low diagnostic yield with the findings of small sclerotic kidneys on renal ultrasound, mildly reduced ADAMTS-13 activity (65%) (Normal 68%-169%) (Cleavage of VWF estimated using

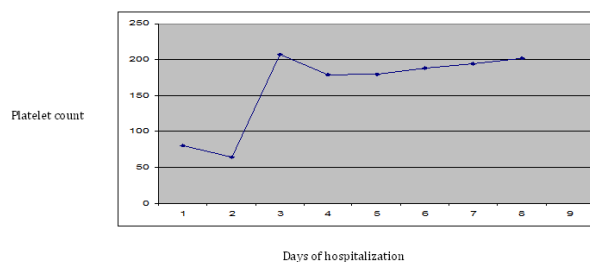
enzyme-linked immunosorbent assay) [ELISA] resulted one week after presentation raised the suspicion of HUS/TTP and need for plasmapheresis was debated. However, given that, peripheral smear schistocytes, hemolysis and thrombocytopenia resolved with control of Blood Pressure and lack of negative response to platelet transfusion as well as clinical improvement with hemodialysis, plasmapheresis wasn't indicated. Patient was discharged home with marked clinical improvement after 10 days on regular hemodialysis with normal platelet level and mild anemia (Figure 3).



**Figure 1:** Peripheral blood smear with schistocytosis.



**Figure 2:** Renal Ultrasound showing small kidney with decrease corticomedullary differentiation consistent with chronic renal disease.



**Figure 3:** Platelet count response after platelet transfusion and control of hypertension.

## Discussion

Thrombotic Microangiopathy (TMA) is a multi-organ dysfunction syndrome characterized by microvascular thrombosis, thrombocytopenia and hemolytic anemia secondary to diverse etiologies ranging from primary Thrombotic thrombocytopenic purpura (TTP) and Hemolytic uremic syndrome (HUS) to secondary phenomena to medications, severe uncontrolled hypertension and autoimmune disorders i.e Scleroderma renal crises, catastrophic antiphospholipid syndrome and pre-eclampsia. ADAMTS-13 (Von Willberand Factor Protease) is an enzyme responsible for degrading vWF multimers. ADAMTS-13 Assay consists of two steps, the first step consists of proteolyzing a substrate by ADAMTS-13 and the second step consists of quantifying the digestion products or the residual VWF remaining after proteolysis [2].

Severe deficiency or inhibition of this enzyme can be associated with congenital thrombotic thrombocytopenic purpura (TTP) and acquired TTP respectively [3]. Studies have shown that ADAMTS13 activity can be decreased in patients with malignant hypertension compared with normotensive control subjects and that it is associated with TMA severity. Van Der Born and his colleagues studied 20 patients with malignant, 20 patients with severe hypertension, and 20 matched normotensive individuals served as control subjects. VWF, active VWF, and free hemoglobin were assessed as a potential predictors of ADAMTS13 activity [4], study had found that patients with malignant hypertension had lower ADAMTS13 activity compared with control subjects, ADAMTS13 activity was also negatively correlated with lactic dehydrogenase levels and was associated with platelet count and the presence of schistocytes [4], however a severe reduction in ADAMTS13 activity was not demonstrated in malignant hypertension. The study findings of the association between ADAMTS13 and renal dysfunction didn't prove causality in the study and ADAMTS13 represented a marker for the degree of endothelial damage rather than being causally related to the TMA and renal insufficiency of malignant hypertension [4]. Recent studies have investigated the utility of in-house ADAMTS assays [5], however to avoid the unnecessary use of plasmapheresis some institutions have used clinical prediction score method based on (platelet count, d-dimer, creatinine, reticulocyte count, indirect bilirubin) [6], results of this score were validated in a recent cohort [7-10].

## Conclusion

The case illustrates the importance of performing comprehensive clinical evaluation in identifying the etiology of TMA to identify patients who need urgent plasmapheresis, ADAMTS-13 activity assay although useful can be time-consuming, and non-specific [2], severe uncontrolled hypertension can affect ADAMTS -13 level, further studies to investigate the pathogenesis of ADAMTS-13 reduction associated with hypertension.

## References

1. Moschcowitz E (1952) An acute febrile pleiochromic anemia with hyaline thrombosis of the terminal arterioles and capillaries: an undescribed disease. *Am J Med* 13: 567-569.
2. Veyradier A, Girma JP (2004) Assays of ADAMTS-13 activity. *Semin Hematol* 41: 41-47.
3. van den Born BJ, Honnebler UP, Koopmans RP, van Montfrans GA (2005) Microangiopathic hemolysis and renal failure in malignant hypertension. *Hypertension* 45: 246-251.
4. van den Born BJ, van der Hoeven NV, Groot E, Lenting PJ, Meijers JC, et al. (2008) Association between thrombotic microangiopathy and reduced ADAMTS13 activity in malignant hypertension. *Hypertension* 51: 862-866.
5. Barrows BD, Teruya J (2014) Use of the ADAMTS13 activity assay improved the accuracy and efficiency of the diagnosis and treatment of suspected acquired thrombotic thrombocytopenic purpura. *Arch Pathol Lab Med* 138: 546-549.
6. Bentley MJ, Wilson AR, Rodgers GM (2013) Performance of a clinical prediction score for thrombotic thrombocytopenic purpura in an independent cohort. *Vox Sang* 105: 313-318.
7. Shibagaki Y, Fujita T (2005) Thrombotic microangiopathy in malignant hypertension and hemolytic uremic syndrome (HUS)/ thrombotic thrombocytopenic purpura (TTP): can we differentiate one from the other? *Hypertens Res* 28: 89-95.
8. Furlan M, Robles R, Galbusera M, Remuzzi G, Kyrle PA, et al. (1998) von Willebrand factor-cleaving protease in thrombotic thrombocytopenic purpura and the hemolytic-uremic syndrome. *N Engl J Med* 339: 1578-1584.
9. Zhang B, Xing C, Yu X, Sun B, Zhao X, et al. (2008) Renal thrombotic microangiopathies induced by severe hypertension. *Hypertens Res* 31: 479-483.
10. Shavit L, Reinus C, Slotki I (2010) Severe renal failure and microangiopathic hemolysis induced by malignant hypertension--case series and review of literature. *Clin Nephrol* 73: 147-152.