

Thymic Hyperplasia in Graves' Disease

Salam Kadhem and Georges C Elhomsy*

Department of Medicine, Kansas University School of Medicine-Wichita, 1010 N. Kansas St, Wichita, KS, 67214, USA

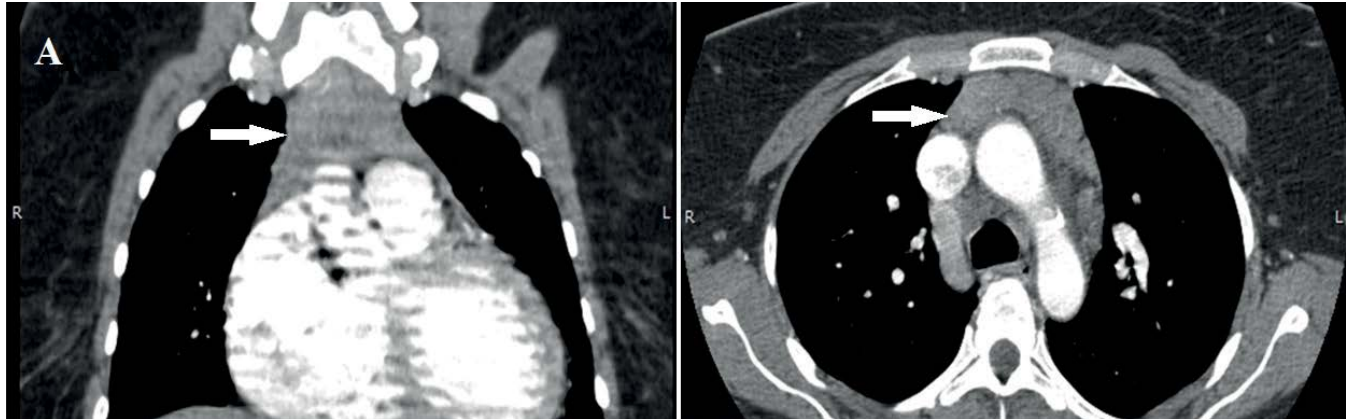


Figure 1: Thymic hyperplasia in Grave's disease.

A 45-year-old woman with Graves' disease, and a history of Coronary artery disease presented with chest pain, her physical exam revealed tachycardia, tremor and goiter, her electrocardiogram was unremarkable, laboratory work up showed undetectable TSH, Elevated Free T3, 19.5 pg/ml (normal value 2.3-4.2 pg/ml) and elevated Free T4, 6 ng/ml (normal value 0.9-1.8 ng/ml), a chest CT-Angiogram ruled out pulmonary emboli but revealed the presence of anterior superior homogenous mediastinal mass that measures 5.2 by 1.5 cm, this

finding was most consistent with thymic hyperplasia (Panel A). Thymic hyperplasia occurs in many autoimmune diseases such as Myasthenia gravis, systemic lupus erythematosus and Graves' disease. Although the pathological process that leads to thymic hyperplasia in patient with Graves' disease it not fully understood, the evidence showed that treatment of the hyperthyroidism leads to the resolution of the thymic hyperplasia, and for that further work up is usually considered unnecessary.

*Corresponding author: Georges C Elhomsy, Department of Medicine, Kansas University School of Medicine-Wichita, 1010 N. Kansas St, Wichita, KS, 67214, USA, Tel: 316-293-2650; Fax: 316-293-1878; E-mail: georgeselhomsy@yahoo.com

Received November 02, 2015; Accepted November 05, 2015; Published November 09, 2015

Citation: Kadhem S, Elhomsy GC (2015) Thymic Hyperplasia in Graves' Disease. Endocrinol Metab Syndr 4: i013. doi:[10.4172/2161-1017.1000i013](https://doi.org/10.4172/2161-1017.1000i013)

Copyright: © 2015 Kadhem S, et al. This is an open-access article distributed under the terms of the Creative Commons Attribution License, which permits unrestricted use, distribution, and reproduction in any medium, provided the original author and source are credited.