

Topical Keratolytics for a Case of Porokeratotic Eccrine Ostial and Dermal Duct Nevus

Ashish Arshanapalli^{1*}, Navid Ezra¹, Mouhammad Aouthmany¹, Stefanie Hirano-Ali², Jeffrey B Travers^{1,3} and Nico Mousdicas^{1,3}

¹Department of Dermatology, Indiana University School of Medicine, Indianapolis, IN, USA

²Department of Pathology and Laboratory Medicine, Indiana University School of Medicine, Indianapolis, IN, USA

³Richard L. Roudebush VA Medical Center, Indianapolis, IN, USA

*Corresponding author: Ashish Arshanapalli, Department of Dermatology, Indiana University School of Medicine, 1605 N Delaware St Indianapolis, IN 46202, USA, Tel: 219-308-8704; Email: aarshanapa@gmail.com

Received date: December 20, 2015; Accepted date: February 09, 2016; Published date: February 12, 2016

Copyright: © 2016 Arshanapalli A, et al. This is an open-access article distributed under the terms of the Creative Commons Attribution License, which permits unrestricted use, distribution, and reproduction in any medium, provided the original author and source are credited.

Abstract

Porokeratotic Eccrine Ostial and Dermal Duct Nevus (PEODDN) is a rare disorder of keratinization characterized by the presence of cornoid lamellae and association with eccrine sweat ducts. These lesions are usually benign and asymptomatic, so treatment is often for cosmetic purposes. Current therapies for PEODDN are either insufficient or impractical. We present a case of PEODDN treated with topical tretinoin 0.05% cream and 5-fluorouracil 5% cream with the hopes of providing an efficacious, financially relevant, and well-tolerated treatment regime for PEODDN.

The combination of topical tretinoin and 5-fluorouracil did not provide substantial improvement in the lesions of a patient treated with this therapy for 6 weeks, and further studies are needed to identify an efficacious treatment for PEODDN that is both well-tolerated and economically feasible for patients with this condition.

Keywords: Porokeratotic eccrine ostial; Dermal duct nevus; Topical keratolytics; Hyperkeratosis; 5-fluorouracil; Tretinoin; Cornoid lamellae

Introduction

Porokeratotic eccrine ostial and dermal duct nevus (PEODDN) is a rare disorder of keratinization that was first named by Abell and Read in 1980 [1]. PEODDN usually presents at birth as comedo-like punctate pits that usually affect the hands and feet but can be widespread and follow Blaschko lines [2]. PEODDN may become more verrucous appearing with time, and lesions are usually asymptomatic although mild pruritus has been reported [2]. Similar to other forms of porokeratosis, PEODDN is characterized histologically by the presence of cornoid lamellae, thin columns of parakeratotic cells with a diminished underlying granular zone, and deeper vacuolar and dyskeratotic changes. However, dissimilar to other forms of porokeratosis, this condition appears to be congenital and occurs exclusively in association with acrosyngia, the intraepidermal portions of eccrine sweat ducts [1]. Current treatments for PEODDN are inadequate and include therapies aimed at reducing the thickness of affected skin. We report a case of PEODDN treated with a six week combination of tretinoin 0.05% cream and 5-fluorouracil 5% cream daily, which did not show improvement in this lesion.

Case Report

A 70 year old gentleman presented to dermatology clinic for evaluation of asymptomatic, unchanging lesions present since childhood. In the past, he has used topical betamethasone ointment on the lesions with no improvement. Physical exam revealed slightly hyperkeratotic 1-2 mm papules grouped on the left chest and following a linear pattern down the left arm down to the wrist (Figure 1) and a

similar group of papules on the left sole of the foot. A biopsy was performed, and the diagnosis of PEODDN was confirmed (Figure 2). The patient elected for therapy understanding that treatment may be ineffective or only partially effective.

Given the positive reports in the treatment of linear epidermal nevus, [3] he was started on a regimen of tretinoin cream 0.05% every morning and 5-fluorouracil 5% every night and scheduled for follow-up in 6 weeks.

Results

The patient returned to clinic after 6 weeks of therapy and did not experience notable changes in his lesions despite adherence to his treatment regimen (Figure 3). He is still electing for therapy and will try other combinations of keratolytics in the future.

Discussion

Since its initial description as a “comedo naevus of the palm” in 1979, porokeratotic eccrine ostial and dermal duct nevus has proven to be a rare entity [4]. A wide variety of phenotypic variations have been described in the literature ranging from hyperkeratotic pits with comedo-like keratin plugs to plaques to verrucoid lesions [2]. Patients are usually asymptomatic, but occasionally patients complain of pruritus, hyperhidrosis, or anhidrosis [6]. The distribution can also be highly variable and lesions have been reported as solitary, linear, following Blaschko lines, and bilateral. In the majority of cases, cutaneous findings are present since birth or childhood, but late-onset, adult presentations have been described in the literature [5]. The reported blaschkoid distribution of PEODDN suggests a genetic abnormality with possible somatic mosaicism occurring during embryogenesis [7], but interestingly, only one case of familial PEODDN has been reported, suggesting a complex mode of

inheritance, if present [2] Co-manifestations of PEODDN with other rare keratinization disorders such as porokeratotic eccrine duct and hair follicle nevus (PEHFN) and nevus comedonicus may suggest similar pathoetiology, but the pathogenic mechanism is not known [2,8].

In the case presented, we offer a novel treatment regimen consisting of two well-tolerated, inexpensive topical therapies that both reduce hyperkeratosis by different mechanisms. 5-fluorouracil is an anti-metabolite that inhibits thymidylate synthetase causing death in rapidly dividing cells and can effectively reduce the accumulation of keratinocytes [14]. Topical retinoids such as tretinoin 0.05% cream also reduce keratinization but do so by altering gene expression and regulating keratinocyte growth and differentiation [15]. By preventing accumulation and plugging of keratinocytes by these two mechanisms, we hoped to remove the hyperkeratotic characteristics of the nevi, allowing for a better cosmetic appearance. Moreover, this combination has been reported to improve epidermal nevi [3].

While the combination of tretinoin 0.05% cream and 5-fluorouracil 5% cream did not prove to be efficacious in this specific case, we believe that this dual approach to inhibiting the hyperkeratotic features of this condition is well-warranted to be documented in the literature.

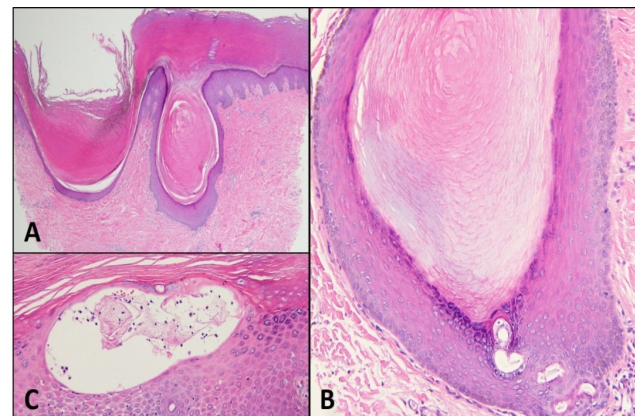


Figure 2: Dermopathology. The punch biopsy specimen demonstrates comedo-like structures with plugs of hyperkeratosis and focal parakeratosis (2a). The hyperkeratotic projections are extending from the dilated eccrine ducts (2b). Dilatation of the acrosyringium results in formation of miliaria-like collections of sweat within the epidermis (2c).

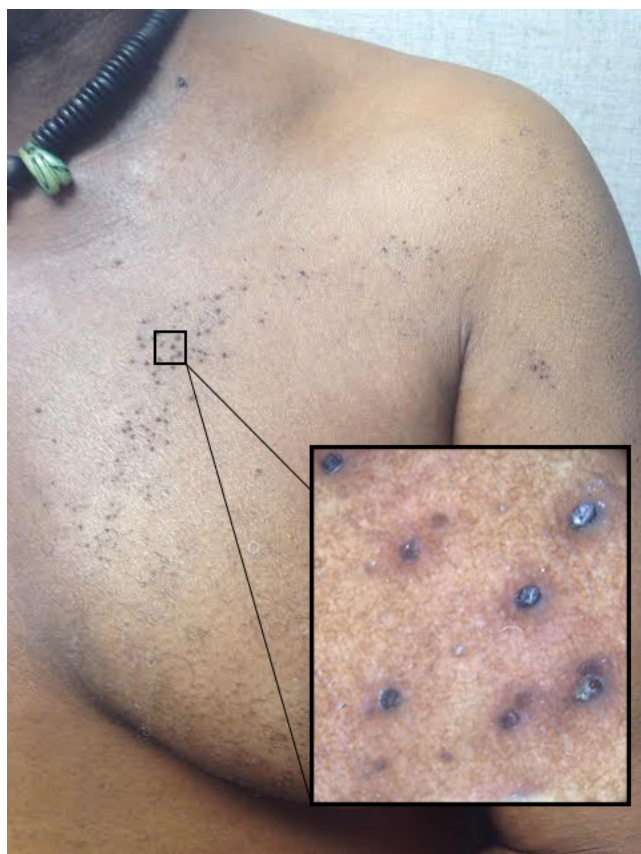

Figure 1: Clinical appearance at presentation. See hyperkeratotic papules grouped on the patient's left chest and shoulder and traveling down his left arm in a linear fashion. On dermoscopy, the comedo-like punctate pits associated with this lesion are clearly evident.

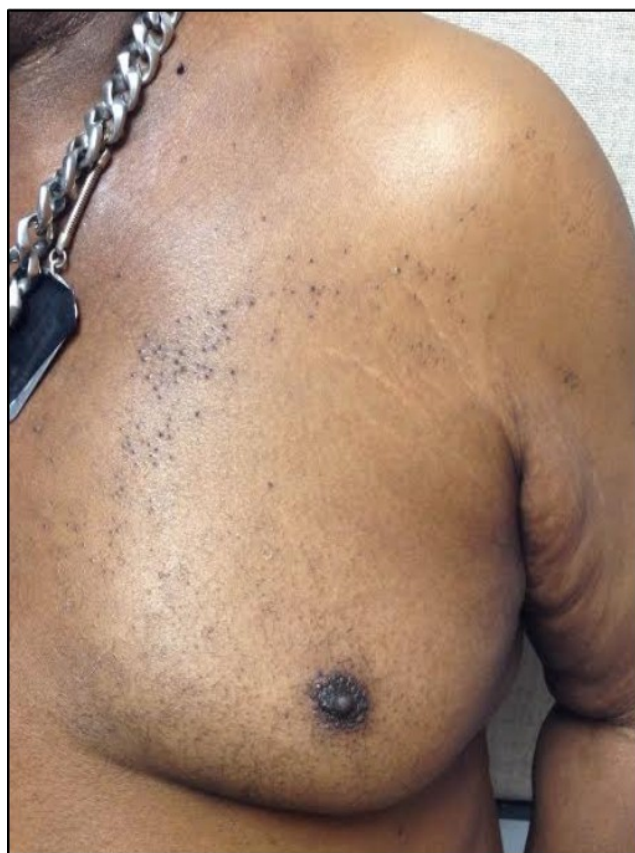


Figure 3: Clinical appearance after 6 weeks of therapy. Patient did not show significant interval change in appearance of hyperkeratotic papules.

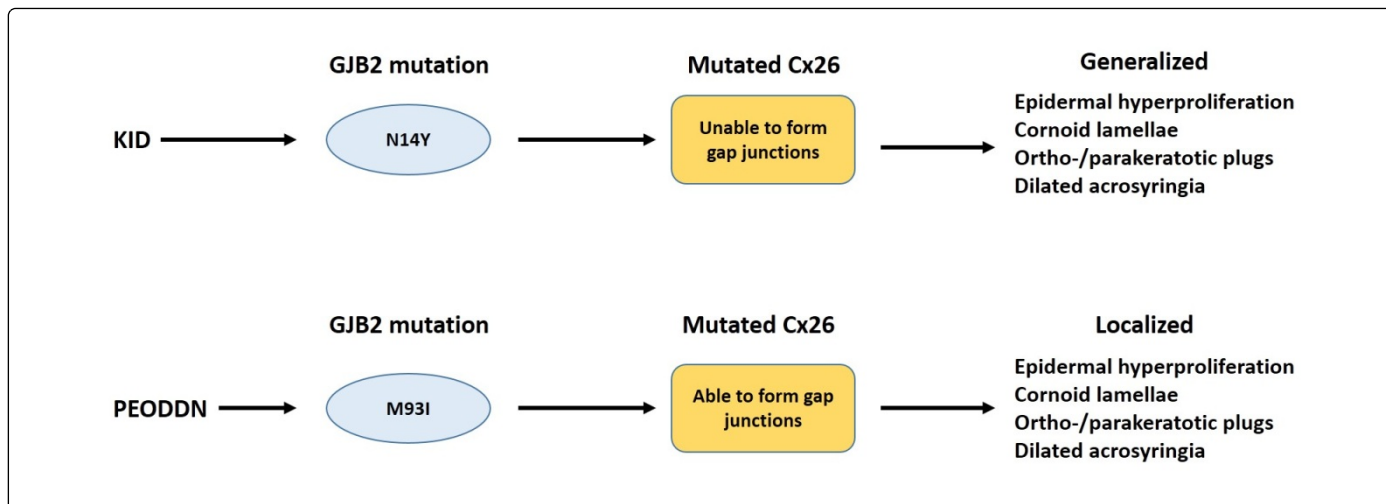


Figure 4: Proposed genetic relationship between keratosis-ichthyosis-deafness (KID) syndrome and perieccrine ostial and dermal duct nevus (PEODDN). Easton et al. hypothesize that specific mutations in the GJB2 gene have different effects on Cx26 proteins leading to phenotypic variation, especially in extent of involvement. N14Y, mutation with the amino acid tyrosine substituted for asparagine at position 14; M93I, mutation with the amino acid isoleucine substituted for methionine at position 93; Cx26, connexin26 protein.

The need for a safe, efficacious, and economically feasible treatment modality for patients with this disorder should continue to drive similar experiments until such a therapy is discovered.

References

1. Abell E, Read SI (1980) Porokeratotic eccrine ostial and dermal duct naevus. *Br J Dermatol* 103: 435-441.
2. Masferrer E, Vicente MA, Bassas-Vila J, Rovira C, Gonzalez-Ensenat MA (2010) Porokeratotic eccrine ostial and dermal duct naevus: report of 10 cases. *J Eur Acad Dermatol Venereol* 24: 847-851.
3. Kim JJ, Chang MW, Shwayder T (2000) Topical tretinoin and 5-fluorouracil in the treatment of linear verrucous epidermal nevus. *J Am Acad Dermatol* 43: 129-132.
4. Marsden RA, Fleming K, Dawber RP (1979) Comedo naevus of the palm--a sweat duct naevus? *Br J Dermatol* 101: 717-722.
5. Stoof TJ, Starink TM, Nieboer C (1989) Porokeratotic eccrine ostial and dermal duct nevus. Report of a case of adult onset. *J Am Acad Dermatol* 20: 924-927.
6. Wang NS, Meola T, Orlow SJ, Kamino H (2009) Porokeratotic eccrine ostial and dermal duct nevus: a report of 2 cases and review of the literature. *Am J Dermatopathol* 31: 582-586.
7. Cambiaghi S, Gianotti R, Caputo R (2007) Widespread porokeratotic eccrine ostial and dermal duct nevus along Blaschko lines. *Pediatr Dermatol* 24: 162-167.
8. Goddard DS, Rogers M, Frieden IJ, Krol AL, White CR Jr, et al. Widespread porokeratotic axillary ostial nevus: clinical features and proposal of a new name unifying porokeratotic eccrine ostial and dermal duct nevus and porokeratotic eccrine and hair follicle nevus. *J Am Acad Dermatol* 61: e1061-1014.
9. Easton JA, Donnelly S, Kamps MA, Steijlen PM, Martin PE, et al. (2012) Porokeratotic eccrine nevus may be caused by somatic connexin26 mutations. *J Invest Dermatol* 132: 2184-2191.
10. Coras B, Vogt T, Roesch A, Landthaler M, Hohenleutner U (2007) Bowen's disease on porokeratotic eccrine ostial and dermal duct nevus. *Dermatol Surg* 33: 496-499.
11. Nassiri N, Hansen J (2009) Diffuse squamous cell carcinoma in porokeratotic eccrine ostial and dermal duct nevus. *Plast Reconstr Surg* 123: 87e-88e.
12. Kim WJ, Choi SR, Lee HJ, Kim DH, Yoon MS (2011) Porokeratotic eccrine ostial and dermal duct nevus showing partial remission by topical photodynamic therapy. *Ann Dermatol* 23: S322-325.
13. Jain S, Sardana K, Garg VK (2013) Ultrapulse carbon dioxide laser treatment of porokeratotic eccrine ostial and dermal duct nevus. *Pediatr Dermatol* 30: 264-266.
14. Longley DB, Harkin DP, Johnston PG (2003) 5-fluorouracil: mechanisms of action and clinical strategies. *Nat Rev Cancer* 3: 330-338.
15. Akhavan A, Bershady S (2003) Topical acne drugs: review of clinical properties, systemic exposure, and safety. *Am J Clin Dermatol* 4: 473-492.