

# Toxicological Evaluations of the Crude Extracts and Fractions of *Moringa stenopetala* Leaves in Liver and Kidney of Rats

Geleta B<sup>1,2\*</sup>, Makonnen E<sup>2</sup> and Debella A<sup>1</sup><sup>1</sup>Directorate of Traditional and Modern Medicine Research, Ethiopian Public Health Institute, P.O. Box 1242, Addis Ababa, Ethiopia<sup>2</sup>Department of Pharmacology, School of Medicine, College of Health Sciences, Addis Ababa University, P.O. Box 9080, Addis Ababa, Ethiopia**\*Corresponding author:** Bekesho Geleta, Directorate of Traditional and Modern Medicine Research, Ethiopian Public Health Institute, P.O. Box 1242, Addis Ababa, Ethiopia, Tel: +251911091969; E-mail: [bekeshog@gmail.com](mailto:bekeshog@gmail.com)**Received date:** Nov 20, 2015; **Accepted date:** Dec 14, 2015; **Published date:** Dec 20, 2015**Copyright:** © 2015 Geleta B et al. This is an open-access article distributed under the terms of the Creative Commons Attribution License, which permits unrestricted use, distribution, and reproduction in any medium, provided the original author and source are credited.

## Abstract

**Background:** *Moringa stenopetala* is a medicinal plant that has been used in Ethiopian traditional medicine as a remedy for treatment of hypertension, diabetes, malaria and stomach pain.

**Objective:** The aim of this study was to assess the safety of the extracts and fractions of *Moringa stenopetala* leaves in liver and kidney of female Wistar rats.

**Methods:** For acute toxicity study, the female Wistar rats were randomly divided into control and treatment groups that received distilled water and oral administration of single dose of 5000 mg/kg (n=5) extract, respectively and followed for 14 days. For repeated daily administration of extract, the female Wistar rats were randomly divided into control and treatment groups (n=6). Treatment groups were given daily extracts (250, 500, and 1000 mg/kg) orally. Whereas, normal control received distilled water *ad libitum* for 15 days. On the 16th day the blood was sampled to evaluate the effect on liver and kidney using clinical chemistry analyzer.

**Results:** The acute toxicity study found no signs of toxicity; hence LD<sub>50</sub> was greater than 5000 mg/kg. The biochemical test revealed that extracts produced a rise in liver in a dose dependent manner but no effect on kidney function indicators compared with normal control.

**Conclusion:** These findings revealed that the extracts of *Moringa stenopetala* are toxic to liver but not to kidney.

**Keywords:** Toxicity; *Moringa stenopetala*; Liver; Kidney

## Abbreviations:

ALT: Alanine Transaminase; AST: Aspartate Transaminase; ALP: Alkaline Phosphatase; LD: Lactate Dehydrogenase; GGT: Gamma-Glutamyl Transpeptidase; BUN: Blood Urea Nitrogen; EPHI: Ethiopian Public Health Institute; EtOH: Ethanol; AQ: Aqueous; EtAc: Ethyl Acetate; OECD: Organization for Economic and Co-operation and Development; D<sub>1</sub>: First day; D<sub>5</sub>: Fifth day; D<sub>7</sub>: Seventh day; D<sub>10</sub>: Tenth day; D<sub>14</sub>: Fourteenth day; D<sub>15</sub>: Fifteenth day; LD<sub>50</sub>: Lethal dose-50

## Introduction

Plants provided effective sources of traditional medicines against many ailments since ancient times. Peoples of all continents, especially in Africa and Asia, with its diverse culture and rich plant flora, used folklore medicine for their health needs [1]. Medicinal plants contain various pharmacologically active compounds which have useful therapeutic applications [2] and many are utilized in the development of the drug industry [3]. About thirty percent of the drugs sold worldwide contain compounds derived from plants [4].

Although there is increased acceptance and consumption of herbal remedies worldwide, care must be taken not to consume harmful plants or high doses of plant extracts that could have deleterious effects

on vital body organs either in short term or long term. Concerns by medical personnel indicate that herbal medicines may be harmful to vital organs such as liver and kidneys [5]. Toxic effects due to herbal medicine may manifest in a number of organs such as kidney, liver, stomach, nervous system and blood. The liver is a vital organ for maintaining of metabolic functions and detoxification from exogenous and endogenous substances like xenobiotics, drugs and viral infections [6,7].

When the liver is exposed to such substances, its protective mechanisms are overpowered due to cellular necrosis and increase in serum levels of biochemical parameters like ALP and AST [8,9]. Determination of efficacy and safety of herbal remedies is necessary as many people use them for self-medication [10,11]. For majority of herbal products in use, very little is known about their active and/or toxic constituents. Evaluating the prolonged effects of medicinal plant extracts used in humans is useful in assessing the potential toxic effects. This increases the confidence in their safety to humans, particularly for use in the development of pharmaceuticals. The provision of safe and effective herbal therapies could, thus, become a critical tool to increase access to health care [12].

*Moringa stenopetala* (Baker f.) Cudof is one of these medicinal plants widely used for treatment of variety of diseases including hypertension. *M. stenopetala* (Baker f.) Cudof. belongs to the family Moringaceae represented only by a single genus *Moringa*. The genus is

represented by 14 species to which *M. stenopetala* (Baker f.) Cudof. belongs. It is a branched tree that grows 6 to 10 m tall, thick at base bark with white to pale gray or silvery coloration [13]. It grows abundantly in south western Ethiopia at an altitude range of 1000 to 1800 m, where the leaves are eaten as vegetable. The species is known by different vernacular names such as “Shiferaw” in Amharic, “Aleko” in Wollaytegna and Gamugna and “Cabbage tree” in English [14]. The indigenous knowledge and use of *Moringa* is referenced in more than 80 countries and it’s known in over 200 local languages.

The history of *Moringa* dates back to 150 B.C. The family Moringaceae is a monotypic family of single genera with around 33 species of which 4 is accepted, 4 are synonym and 25 are not investigated. Out of these, 13 species, native of old world tropics are documented [15]. *M. stenopetala* (Baker f.) Cudof. is among various types of *Moringa* species, which is native to Ethiopia, Northern Kenya and Eastern Somali and is the most economically important species after *Moringa oleifera* [16]. *M. stenopetala* (Baker f.) Cudof. is a multipurpose plant [13]. It has been reported that, *M. stenopetala* (Baker f.) Cudof. has hypotensive [17], antihyperglycemic and hypoglycemic [18-22], antileishmanial and antifertility [14], treatment of stomach pain, anti-spasmodic and to expel retained placenta following birth [23], antimicrobial activity [24] and also has a nutritional value [13]. The *in vitro* study demonstrated the beneficial biochemical effects of *M. stenopetala* (Baker f.) Cudof. by inhibiting intestinal  $\alpha$ -glucosidase, pancreatic cholesterol esterase and pancreatic lipase activities [22]. The objective of the present study is, therefore, to investigate the safety of extracts and fractions of *M. stenopetala* (Baker f.) Cudof. leaves in rats.

## Materials and Methods

### Drugs and chemicals

Ethyl Acetate (lot no: 8114/4, Park Scientific Limited, Northampton, UK), Absolute Ethanol (lot no: E35070/2, WINLAB, UK) and Petroleum Ether (lot no: V2B668282B, Scientific limited, UK) were used in the study. All the drugs, chemicals and reagents used complied with the required standard and were of analytical grade.

### Instruments and apparatus

Lyophilizer/ Freeze dry system (Labconco, 12 L Console Freeze Dry 230v-60 (7754040), Freeze Dry System, USA), Centrifuge (Rotant 98, Hettich, Zentrifugen, UK), Clinical chemistry analyzer (Cobas-e-411, HITACHI, ROCHE, Germany).

### Plant materials

The fresh *M. stenopetala* (Baker f.) Cudof. leaves were collected from Southern Ethiopia around Arbaminch, about 500 km far from Addis Ababa on September 2014. The plant material was authenticated by a taxonomist in the EPHI and a voucher number AL-001 was deposited in the herbarium for future reference.

### Experimental animals

The experiments were performed on adult, healthy female Wistar rats (*Rattus norvegicus*) weighing 150-200 g bred and obtained from the EPHI. All the animals used for this study were kept in standard animal cages and maintained under laboratory conditions of temperature ( $22 \pm 30^\circ\text{C}$ ), relative humidity (40-70%) and 12 hour

day-12 hour night and had free access to food (standard pellet diet) and water *ad libitum*. The animals were treated humanely throughout the study period and were kept in a well-controlled area according to the guideline for use and care of animals [25].

### Plant material preparation and extraction

Fresh *M. stenopetala* (Baker f.) Cudof. leaves were garbled, chopped, dried under shade (at room temperature), grinded to powder using mortar and pestle and stored in cool and dry place. Weighed amounts of 1.208 Kg and 2.130 Kg powdered leaves were kept in Erlenmeyer flasks and macerated with water (distilled and deionized) and 70% ethanol at room temperature under a rotator shaker until exhaustion for 4 and 72 hours, respectively. The 70% EtOH extract was filtered using cotton gauze and then with Whatman filter paper No.1. The filtrate was concentrated under reduced pressure using Rota vapor. The semidried residue was kept on a water bath at  $400^\circ\text{C}$  overnight and then with a Lyophilizer to completely remove the solvent residue. The AQ crude extract was filtered using a Whatman filter paper No.1, kept in refrigerator overnight to freeze and lyophilized to remove the water. The total yield of the AQ and 70% EtOH extract were calculated 17.1% and 4.9% (w/w), respectively. About 178.95 g of dried AQ crude extract were defatted by petroleum ether and partitioned with EtAc, the solvent was removed using Rota vapor and Lyophilizer to obtain EtAc (18.6% w/w yield) and AQ residue (35% w/w yield), respectively. The dried extracts were kept in a refrigerator until used for the experiment.

### Evaluation of effects on liver and kidney

Female Wistar rats were randomly divided into groups with 6 animals (n=6). Normal control rats (Group 1) received distilled water *ad libitum* and treatment rats (Group 4-13) received different extracts (250, 500, 1000 mg/kg/day) for 15 days. During the experiment, the animals were observed for detection of clinical signs of toxicity.

On the 16th day, the blood was collected in vacutainer tube by cardiac puncture from night fasted cervical dislocated rats. The serum was separated after centrifugation at 3000 rpm for 10 minutes. The liver function indicators (ALT, AST, ALP, and GGT) and kidney function indicators ((BUN and creatinine) were assayed using methods described by the manufacturer (Roche diagnostics, Germany) using COBA-e-411 Clinical chemistry analyzer instrument.

### Acute toxicity study

The extracts of *M. stenopetala* (Baker f.) Cudof. leaves (AQ crude, 70% EtOH crude, EtAc fraction and AQ residue of AQ crude extracts) were evaluated for possible toxic effect in female Wistar rats at a dose of 5000 mg/kg body weight according to OECD guidelines No. 425 [26].

On the basis of oral reports of high consumption of the leaves for diet mixed with cultural foods, the chosen dose of extract was highest (5000 mg/kg body weight). The animals were deprived of food for 18 hours with free access to water. Immediately after administration of the extract, the animals were carefully observed continuously for the first 4 hours for any overt signs of toxicity and death and then for the next 24 hours. Thereafter, they were kept under close observation up to 14 days to monitor the presence of any signs of morbidity or mortality. The weight of each animal was recorded at the 1st, 7th, and 14th day of administration to verify any unexpected weight change that might have occurred. During the experiment, the animals were observed for detection of clinical signs of toxicity. Finally, after cervical dislocation,

the rats were dissected at the 14th day to observe gross pathology of the vital organs such as liver, kidney, spleen and pancreas.

### Statistical analysis

Data were analyzed using the SPSS version 16 software package for ANOVA and  $p < 0.05$  was considered as the level of significance.

### Results and Discussion

This study investigated the safety of different extracts and fractions of *M. stenopetala* (Baker f.) Cudof. leaves in rats through physical and gross pathological observation as well as biochemical assessment of liver and kidney in rats.

#### Effect on body weight

All groups showed an increase in weight throughout the experiment. All groups did not showed a significant difference in percent weight gain on D5 and D10 except the group that took 500 mg/kg/day AQ residue of AQ extract ( $P < 0.05$ ), whereas, in D15 the percent weight gain is high in groups that took 500 mg/kg/day

followed by 250 mg/kg/day and 1000 mg/kg/day of extracts in similar manner in succession. All treatment groups that administered highest dose (1000 mg/kg/day) of extracts showed a significant difference ( $P < 0.001$ ) in percent weight gain in D15 of the study compared with normal control (Graph 1).

All groups of rats in this study showed increase in body weights which is in agreement with the study done on sub-acute administration of AQ crude extract of *M. stenopetala* (Baker f.) Cudof. leaves in mice [27]. However, the percentage of body weight gain was reduced in the highest doses of all extracts (1000 mg/kg/day). This reduction was significant compared to normal control in the D15 of the experiment. This finding is in line with that of the previous study on sub-acute administration of AQ crude extracts of *M. oleifera* in rats [28-30].

#### Effect on liver enzymes and kidney metabolites

The extracts and fractions increased ALT, AST, ALP and GGT levels in a dose dependent manner compared with normal control. All treatment groups did not show significant difference in creatinine compared with normal control (Tables 1 and 2).

Substance administered	Dose (mg/kg)	Liver parameters			
		ALP(U/L)	ALT (U/L)	AST (U/L)	GGT (U/L)
AQ crude	250	168.03 ± 10.79	62.88 ± 3.65	162.57 ± 10.85	2.80 ± 0.21
	500	211.57 ± 10.85	77.87 ± 6.01	238.58 ± 42.96	3.06 ± 0.43
	1000	239.33 ± 8.43	80.50 ± 0.99	246.78 ± 14.08	3.58 ± 0.15
70% EtOH crude	250	179.18 ± 7.92	63.75 ± 3.55	176.15 ± 12.81	2.55 ± 0.18
	500	219.57 ± 15.24	64.10 ± 2.39	193.73 ± 27.64	2.71 ± 0.35
	1000	227.08 ± 15.62	66.67 ± 1.54	214.15 ± 9.84	3.31 ± 0.18
EtAc fraction of AQ crude	250	195.47 ± 11.59	65.03 ± 3.25	199.47 ± 35.39	2.8500 ± 0.56
	500	204.93 ± 25.91	65.93 ± 2.38	244.32 ± 20.88	3.5500 ± 0.49
	1000	222.02 ± 11.19	68.13 ± 1.17	251.33 ± 7.37	4.3000 ± 0.61
AQ residue of AQ crude	250	193.23 ± 13.29	57.18 ± 2.02	188.57 ± 19.75	3.1333 ± 0.17
	500	215.67 ± 4.11	64.20 ± 0.91	196.73 ± 5.55	3.5333 ± 0.39
	1000	237.53 ± 18.38	65.23 ± 3.02	200.27 ± 25.00	3.7500 ± 0.29
Distill. water	<i>ad libitum</i>	174.47 ± 8.64	66.63 ± 3.54	194.75 ± 18.18	3.9667 ± 1.16

**Table 1:** Effect of crude extracts and fractions of *M. stenopetala* on liver of rats (Results are expressed as mean ± SEM (n = 6), \* = Compared to normal control; 1 =  $P < 0.05$ ; 2 =  $P < 0.01$ ; 3 =  $P < 0.001$ )

#### Effect on liver enzymes

The liver is vulnerable to various environmental toxicants which may cause structural and functional abnormalities. If there is mild inflammation and tissue damage to these organs, the permeability of the cell membrane will increase and release cytoplasmic enzymes such as LD, ALP, and AST, while necrosis will release mitochondrial ALT as well as AST leaking into the blood and increase in levels. Testing of AST and ALT are used for hepatocellular (damage to liver cells and liver disease) evaluation while ALP is used for hepatobiliary (cholestasis or hyperbilirubinemia) evaluation which is used to

determine potential target organs toxicity and associated time courses of the damage without the need of biopsy or necropsy samples [31-33].

From the present work all treatment groups elicited an increase in AST, ALT, ALP and GGT in a dose dependent manner though not significant. The largest serum ALP, AST, ALP and GGT was observed for groups that took the maximum dose (1000 mg/kg/day) of AQ crude extract. The results are in line with those of the studies done on extract of *M. stenopetala* (Baker f.) Cudof. leaves in HEPG2 cells *in vitro* [34], sub-chronic administration of 70% EtOH crude extract of *M. stenopetala* (Baker f.) Cudof. leaves in mice [20], sub-acute

administration of AQ crude extract of *M. stenopetala* (Baker f.) Cudof. leaves in mice [27] and seven days administration of EtOH extract of *M. oleifera* leaves in rats [35].

The liver and kidney are major organs of early screening efforts in the preclinical research and a major target organ in the repeated-dose nonclinical safety studies used to support clinical trials [29-30].

### Effect on kidney metabolites

Toxic agents may affect kidneys and impair their physiological functions. The effect on kidney can be investigated by cross checking the normally expected function, such as in excreting waste product like BUN and creatinine [36].

In this study renal toxicity was assessed by measuring BUN and creatinine and the results showed that there was no significant increase in the plasma level of BUN and creatinine in comparison with normal control which indicated nontoxic effect of the extract on the kidney. This finding is in agreement with those of the studies done on sub-chronic administration of 70% EtOH crude extract of *M. stenopetala* (Baker f.) Cudof. leaves in mice [20], sub-acute administration of AQ crude extract of *M. stenopetala* (Baker f.) Cudof. leaves in mice [27] and sub-acute administration of AQ crude extract of *M. oleifera* leaves in rats [28].

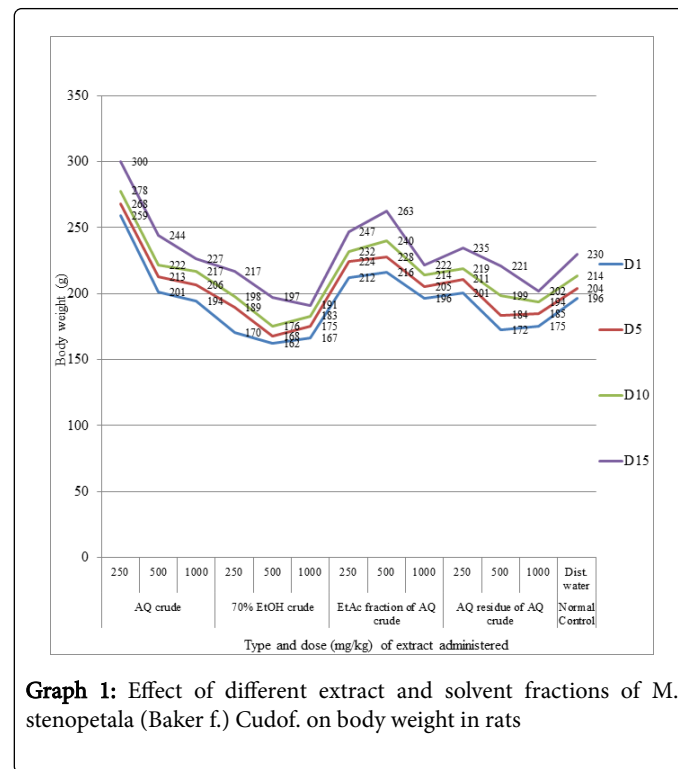
Substance administered	Dose (mg/kg)	Kidney parameters	
		Creatinine (mg/dl)	BUN (mg/dl)
AQ crude	250	0.39 ± 0.02*2	19.60 ± 1.01*3
	500	0.34 ± 0.01	22.03 ± 1.44*3
	1000	0.32 ± 0.00	23.33 ± 0.42*2
70% EtOH crude	250	0.30 ± 0.01	24.00 ± 0.81*1
	500	0.32 ± 0.01	22.55 ± 1.76*2
	1000	0.34 ± 0.02	21.15 ± 0.73*3
EtAc fraction of AQ crude	250	0.39 ± 0.01	21.81 ± 1.39*3
	500	0.35 ± 0.01	18.56 ± 0.73*3
	1000	0.32 ± 0.00	24.48 ± 0.44*1
AQ residue of AQ crude	250	0.40 ± 0.01	17.83 ± 0.89*3
	500	0.30 ± 0.01	18.06 ± 1.21*3
	1000	0.34 ± 0.01	22.33 ± 0.80*3
Distill. water	ad libitum	0.33 ± 0.00	29.80 ± 0.92

**Table 2:** Effect of crude extracts and fractions of *M. stenopetala* on kidney of rats (Results are expressed as mean ± SEM (n = 6), \* = Compared to normal control; 1 = P < 0.05; 2 = P < 0.01; 3 = P < 0.001)

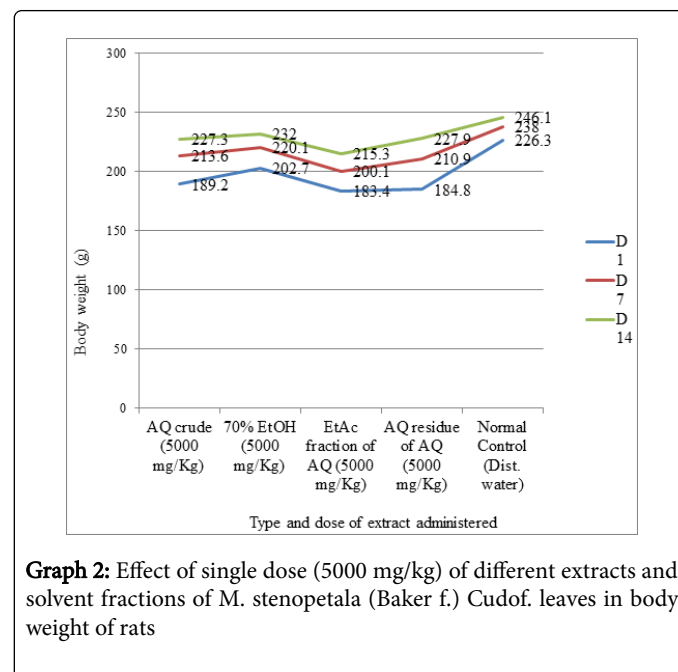
### Acute oral toxicity

The acute toxicity study indicated that the extract did not show any signs of toxicity with close follow up for 4 hours and cause no mortality within 24 hours and 14 days at a dose of 5000 mg/kg body weight. After 14 days of observation of the experimental rats, no body weight reduction as well as over increase was observed. Gross physical and behavioral observation also revealed no visible signs of toxicity.

Additionally, there was no gross pathological alteration (color, size and texture) of the vital organs. Therefore, the LD50 of these extracts was greater than 5000 mg/kg (Graph 2).



**Graph 1:** Effect of different extract and solvent fractions of *M. stenopetala* (Baker f.) Cudof. on body weight in rats



**Graph 2:** Effect of single dose (5000 mg/kg) of different extracts and solvent fractions of *M. stenopetala* (Baker f.) Cudof. leaves in body weight of rats

Aside from being highly revered for its medicinal value, *M. stenopetala* (Baker f.) Cudof. has also served the community as a source of food for centuries. With this prior information of safety, limit test was found to be the appropriate test for assessing the acute toxicity profile with high dose (5000 mg/kg body weight) as per the OECD guideline [26].



The acute toxicity study of oral administration of the limit dose of 5000 mg/kg of the AQ crude extract and its solvent fractions (EtAc fraction and AQ residue) and 70% EtOH crude extract of *M. stenopetala* (Baker f.) Cudof. leaves indicated that there was no mortality observed in all test animals during the course of the study period. Furthermore, no overt behavioral and physical signs of toxicity were discerned at this dose. The observation that there was no sign of morbidity as well as mortality at this high dose, it would in fact allow making suggestions that the oral LD50 of the extract could be greater than 5000 mg/kg.

All experimental groups showed an increase in body weight and a reasonable percent weight gain in D7 and D14 of the experiment compared with normal control. This finding is in line with the study done on 70% EtOH extract of *M. stenopetala* (Baker f.) Cudof. leaves at 5000 mg/kg in mice [18], n-butanol fraction of 70% EtOH extract *M. stenopetala* (Baker f.) Cudof. leaves at 5000 mg/kg in mice [19] and AQ extract of *M. oleifera* leaves at 2000 mg/kg in rats [28]. Therefore, the outcome of the acute toxicity test could support the plant for folkloric medicinal use by the community.

## Conclusion

Findings in the acute toxicity test suggest that the aqueous leaf extract of *M. stenopetala* are practically non-toxic to the female Wistar rats when administered orally. Whereas, the repeated oral daily administration has revealed potential damage to liver in a dose dependent manner but not to the kidney. Further studies, however, need to be done to confirm this.

## Acknowledgement

The authors are grateful for the financial support provided by Graduate Studies of Addis Ababa University and Ministry of Finance and Economic Development (project number OBN6.34/2007) through EPHI. The staffs of the Traditional and Modern Medicine Research Directorate and finance, plan and monitoring are hereby sincerely appreciated for their relentless assistance and much noted contribution during the study.

## References

1. Ouedraogo Y, Guissou IP, Nacoulma OG (2007) Biological and toxicology study of aqueous root extract from *Mitragyna inermis* (Willd) Oltke) Rubiaceae. *Int J Pharmacol* 3: 80-85.
2. Azaizh H, Fulder S, Khalil K, Said O (2003) Ethnobotanical knowledge of local Arab practitioners in the Middle Eastern region. *J Fitoterapia* 74: 98-108.
3. Baker JT, Carte B (1995) Natural product drug discovery and development: New perspectives on international collaboration. *J Nat Prod* 58: 1325-1357.
4. WHO (2003) Guideline on Good Agriculture and Collection Practice (GACP) for Medicinal Plants D.I. Geneva.
5. Ogbe RJ, Yahaya AA, Anefu E (2012) Aqueous Ethanolic Extract of *Mangifera indica* Stem Bark Effect on the Biochemical and Hematological Parameters of Albino Rats. *Archives of Applied Science Research* 4: 1618-1622.
6. Abdel-Daim MM, Abuzead SM, Halawa SM (2013) Protective role of *Spirulina platensis* against acute deltamethrin-induced toxicity in rats. *PLoS One* 8: e72991.
7. Abdel-Daim MM, Abd Eldaim MA, Hassan AG (2015) *Trigonella foenum-graecum* ameliorates acrylamide-induced toxicity in rats: Roles of oxidative stress, proinflammatory cytokines, and DNA damage. *Biochem Cell Biol* 93: 192-198.
8. Al-Sayed E, Martiskainen O, Seif el-Din SH, Sabra ANA, Hammam OA, et al. (2014) Hepatoprotective and Antioxidant Effect of *Bauhinia Hookeri* Extract against Carbon Tetrachloride-Induced Hepatotoxicity in Mice and Characterization of Its Bioactive Compounds by HPLC-PDA-ESI-MS/MS. *BioMed Research International* 2014: 1-9.
9. Azab S, Abdel-Daim M, Eldahshan O (2013) Phytochemical, cytotoxic, hepatoprotective and antioxidant properties of *Delonix regia* leaves extract. *Medicinal Chemistry Research* 22: 4269-4277.
10. Eldahshan OA, Abdel-Daim MM (2015) Phytochemical study, cytotoxic, analgesic, antipyretic and anti-inflammatory activities of *Strychnos nuxvomica*. *Cytotechnology* 67: 831-44.
11. Al-Sayed E, Abdel-Daim MM (2014) Protective Role of *Cupressuflavone* from *Cupressus macrocarpa* against Carbon Tetrachloride-Induced Hepato-and Nephrotoxicity in Mice. *Planta medica* 80: 1665-1671.
12. WHO (2002) Traditional medicine strategy 2002-2005, Geneva.
13. Abuye C, Urga K, Knapp H, Selmar D, Omwega AM, et al. (2003) A compositional Study of *Moringa Stenopetala* leaves. *East African Med J* 80: 247-252.
14. Mekonnen Y, Gessesse A (1998) Documentation on the uses of *Moringa stenopetala* and its possible antileishmanial and antifertility effects. *Ethiop J Sci* 21: 287-295.
15. Arora DS, Onsare JG, Kaur H (2013) Bioprospecting of *Moringa* (Moringaceae): Microbiological Perspective. *J Pharmacogn Phytochem* 1: 193-215.
16. Olson ME (2001) Introduction to the *Moringa* family. In: *Fuglie LL (eds.), The Miracle Tree: Moringa oleifera: Natural Nutrition for the Tropics*. Church World Service, West Africa Regional Office, Dakar, Senegal 11-28.
17. Mengistu M, Abebe Y, Mekonnen Y, Tolessa T (2012) In vivo and in vitro hypotensive effect of aqueous extract of *Moringa stenopetala*. *Afri Health Sci* 12: 545-551.
18. Nardos A, Makonnen E, Debella A (2011) Effects of crude extracts and fractions of *Moringa stenopetala* (Baker f) *Cufodontis* leaves in normoglycemic and alloxan-induced diabetic mice. *Afri J of Phar and Pharmacol* 5: 2220-2225.
19. Toma A, Makonnen E, Debella A, Tesfaye B (2012) Antihyperglycemic Effect on Chronic Administration of Butanol Fraction of Ethanol Extract of *Moringa stenopetala* Leaves in Alloxan Induced Diabetic Mice. *Asian Pac J Trop Biomed* 2: S1606-S1610.
20. Sileshi T, Makonnen E, Debella A, Tesfaye B (2014) Antihyperglycemic and subchronic toxicity study of *Moringa stenopetala* leaves in mice. *J Coast Life Med* 2: 214-221.
21. Toma A, Makonnen E, Mekonnen Y, Debella A, Adisakwattana S (2015) Antidiabetic activities of aqueous ethanol and n-butanol fraction of *Moringa stenopetala* leaves in streptozotocin-induced diabetic rats. *BMC Comp Alt Med* 15: 242-249.
22. Toma A, Makonnen E, Mekonnen Y, Debella D, Adiskwaattana S (2014) Intestinal  $\alpha$ -glucosidase and some pancreatic enzymes inhibitory effect of hydroalcoholic extract of *Moringa stenopetala* leaves. *BMC Comp Alt Med* 14: 180-184.
23. Mekonnen Y (1999) Effects of ethanol extracts of *Moringa Stenopetala* leave on guinea pig and mouse smooth muscle. *Phytother Res* 13: 442-444.
24. Biffa D (2005) In vitro antimicrobial activities of bark and leaf extracts of *Moringa stenopetala* against mastitis causing bacterial pathogens. *Ethiop Pharm J* 23: 15-22.
25. National Research Council (2011) Guide for the care and use of laboratory animals (8th edn). Washington D.C, National Academy Press.
26. OECD (2008) Guidelines for the testing of new chemicals revised draft guideline 425; acute oral toxicity.
27. Ghebreselassie D, Mekonnen Y, Gebru G, Ergete W, Huruy K (2011) The effects of *Moringa stenopetala* on blood parameters and histopathology of liver and kidney in mice. *Ethiop J Health Dev* 25: 51-57.

28. Adedapo A, Mogbojuri OM, Emikpe BO (2009) Safety evaluations of the aqueous extract of the leaves of *Moringa oleifera* in rats. J Med Plants Res 3: 586-591.
29. Oduola T, Bello I, Adeosun G, Ademosun AW, Raheem G, et al. (2010) Hepatotoxicity and nephrotoxicity evaluation in Wistar albino rats exposed to *Morinda lucida* leaf extract. N Am J Med Sci 2: 230-233.
30. Coolborn AF, Bolatito B, Clement AF (2012) Study of acute and sub chronic toxicity of *Spathodea campanulata* P Beav leaf. Int Proc Chem Biol Environ Eng 41: 76-80.
31. Hor SY, Ahmad M, Farsi E, Yam MF, Hashim MA, et al. (2012) Safety assessment of methanol extract of red dragon fruit (*Hylocereus polyrhizus*): acute and subchronic toxicity studies. Regul Toxicol Pharmacol 63: 106-114.
32. Ashafa AO, Orekoya LO, Yakubu MT (2012) Toxicity profile of ethanolic extract of *Azadirachta indica* stem bark in male Wistar rats. Asian Pac J Trop Biomed 2: 811-817.
33. Shyamal S, Lath PG, Suja SR, Shine VJ, Anuja GI, et al. (2010) Hepatoprotective effect of three herbal extracts on Aflatoxin B1-intoxicated rat liver. Singapore Med J 51: 326-331.
34. Mekonnen N, Houghto NP, Timbrell J (2005) Toxicity of extracts of plant parts of *Moringa stenopetala* in HEPG2 cells in vitro. Phytother Res 19: 870-875.
35. Aja PM, Igwenyi IO, Okechukwu PC, Orji OU, Alum EU (2015) Evaluation of Anti-diabetic Effect and Liver Function Indices of Ethanol Extracts of *Moringa oleifera* and *Cajanus cajan* Leaves in Alloxan Induced Diabetic Albino Rats. Global Veterinaria 14: 439-447.
36. Nafiu M, Akanji M, Yakubu M (2011) Effect of aqueous extract of *Cochlospermum planchonii* rhizome on some kidney and liver functional indices of albino rats. Afr J Tradit Complement Altern Med 8: 22-26.