

## Transient Paraparesis from a Traumatic Lumbar Intrathecal Hemorrhage. A Case Report and Literature Review

Walsh KM<sup>1\*</sup>, Vedant V<sup>2</sup> and Schlenk RP<sup>1,2</sup>

<sup>1</sup>Department of Neurosurgery, Neurological Institute, Cleveland Clinic, Cleveland, Ohio, USA

<sup>2</sup>Center for Spine Health, Cleveland Clinic, Cleveland Ohio, USA

\*Corresponding author: Walsh KM, Department of Neurosurgery, Neurological Institute, Cleveland Clinic, Cleveland, Ohio, USA, Tel: 717-261-6740; Fax: 216-445-4527; E-mail: walshk4@ccf.org

Received date: November 05, 2015; Accepted date: January 06, 2016; Published date: January 08, 2016

Copyright: © 2016 Kevin, et al. This is an open-access article distributed under the terms of the Creative Commons Attribution License, which permits unrestricted use, distribution, and reproduction in any medium, provided the original author and source are credited.

### Abstract

**Background:** Intrathecal bleeding can be subdural, subarachnoid or intramedullary depending on its location. Intrathecal bleeding within the lumbar spine is seldom reported and no specific guidelines for its diagnosis and management exist. We present a case of transient paraparesis secondary to a post-traumatic lumbar intrathecal hemorrhage, which resolved spontaneously without surgical intervention.

**Case description:** The patient is a 66-year-old male with a PMH of chronic myelomonocytic leukemia (CMML) who underwent two lumbar punctures during the workup for newly diagnosed intracranial lesions. The patient shortly thereafter began to complain of acute onset lower extremity weakness. An MRI revealed a large ventral lumbar intrathecal hemorrhage, extending from T11 to the sacrum with canal compromise. The decision was made, after much discussion, to manage the patient conservatively without surgery. Over the course of his hospital stay, the patient's leg strength significantly improved, and as of his three-month follow up visit, his strength was nearly back to baseline.

**Conclusions:** Bleeding episodes in the spine are usually epidural and most case reports have shown that in the presence of neurological deficit or deterioration, surgical evacuation is the recommended treatment. However in patients with intrathecal hemorrhage, conservative management is a viable option, especially in high-risk surgical candidates.

**Keywords:** Transient paraparesis; Traumatic lumbar intrathecal hemorrhage

### Introduction

Intrathecal bleeding can be subdural, subarachnoid or intramedullary depending on its location and can result in mild to severe neurologic compromise and morbidity. The bleeding itself can be a hematoma or a hemorrhage, the differentiation more often discernable in subarachnoid bleeds. The pulsations and dilution of the Cerebrospinal Fluid (CSF) usually does not allow the blood to clot, thus presenting as a diffuse hemorrhage and not as an organized hematoma, however they are often misdiagnosed as epidural hematomas. Intrathecal bleeding within the lumbar spine is seldom reported and no specific guidelines for its diagnosis and management exist. According to literature review of spinal subarachnoid hemorrhages by Domenicucci et al., the overall mortality rate was 25.7%. In those followed for a long period of time, outcome was considered good in 93.5% in those with satisfactory neurological status as compared to 15.8% in those with severe neurological deficits on admission [1]. Most of the patients in the latter group were treated surgically, however the outcomes remained poor.

In our case, we present an episode of a transient paraparesis secondary to a post-traumatic lumbar intrathecal hemorrhage, which resolved spontaneously without surgical intervention, despite severe neurologic deficit.

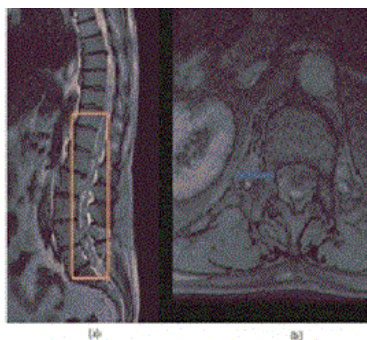
### Case Report

The patient is a 66-year-old male with a past medical history of hypertension, chronic kidney disease and chronic myelomonocytic leukemia (CMML) who had been taking azacitidine for 14 months prior to the current presentation and admission to our institution. He presented to the emergency department with two days of dizziness, nausea, vomiting, and generalized weakness, and was subsequently admitted to the hematology service. During his initial workup, he underwent a CT scan and an MRI scan of the brain without contrast, revealing multiple small hemorrhagic lesions in bilateral hemispheres and the cerebellum. Given his malignancy and chemotherapy treatment, the differential diagnosis included neoplastic, infectious, or other etiology related to his underlying thrombocytopenia.

The workup for the newly found intracranial lesions included two lumbar punctures that were performed while thrombocytopenic, but not coagulopathic (PLT count of 55k and 51k, INR of 1.0 and 1.0, PTT of 34.0 and 32.7 on the dates of lumbar punctures) to look for atypical cells. These procedures were performed under fluoroscopy by a radiology resident under the supervision of a trained neuroradiologist. The patient was transfused platelets prior to the first procedure but there was no record of transfusion prior to the second.

Approximately 24 hours after the last lumbar puncture, the patient began to complain of acute onset lower extremity weakness. On examination, the patient had asymmetric lower extremity weakness, diminished bilateral lower extremity deep tendon reflexes, preserved

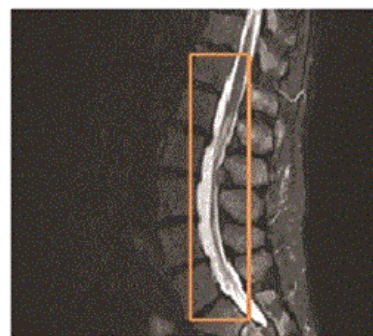bilateral lower extremity sensation to light touch, preserved rectal tone and perineal sensation. His strength on the left side was 1/5 proximally, with 3/5 strength in plantar flexion. His strength on the right was 2/5 proximally and 4+/5 in plantar- and dorsiflexion. An MRI of the neuro-axis was performed emergently, revealing a large ventral lumbar intrathecal hemorrhage, extending from T11 to the sacrum with canal compromise (Figure 1).



**Figure 1:** Midsagittal (a) and axial (b) T2-weighted magnetic resonance images of the thoracolumbar spine, showing a large ventrally located subarachnoid hemorrhage extending from the lower edge of the T11 vertebral body to the upper sacrum (seen within the rectangle). The axial image is at the level of the pedicles of L1, and shows an easily visible hypo-intense signal, which delineates the dura within the spinal canal (arrow). Also seen is a mixed-intensity, heterogeneous signal within the dura, intermingled with nerve roots, and displacing them dorsally.

After extensive discussion between the patient, family, staff hematologist and spine surgeon, the decision was made to manage the patient conservatively without surgery. The decision to forego surgery was based on the patient's chronic thrombocytopenia, immunosuppression, chronic kidney disease, poor overall oncological prognosis and short life expectancy of a few months. It was decided that the overall risks outweighed the potential benefit of surgical intervention. The uncertainty of the prognosis of neurological recovery with management option after intrathecal hemorrhage posed challenges in the clinical decision making process and also in discussions with the patient and family.

Over the course of the next 8 days, the patient had steady improvement in his lower extremity function. By the time he was discharged, he was able to ambulate with a walker and his leg strength was approximately 4/5 bilaterally. He was discharged to home with therapy. At his 6-week office visit after discharge, the patient was found to have full strength in both legs, was able to ambulate with some mild difficulty, but was improving. An interval MRI of his lumbar spine was performed 2 months after the initial MRI, which revealed interval subtotal resolution of the intrathecal hemorrhage (Figure 2).



**Figure 2:** Midsagittal STIR image of the thoracolumbar spine taken approximately 2 months after the initial MRI, as seen in Figure 1. This image shows interval near-complete resolution of the subarachnoid hemorrhage, correlating to the patient's spontaneous and gradual improvement in his symptomatology.

He was last seen in clinic at approximately 14 weeks after his initial diagnosis. At this time, he was ambulating without assistance, was able to perform basic activities of daily living, and the patient reported that his leg strength is approximately 90% of normal and was improving gradually over time. On examination his power was 4+/5 in all muscle groups. He continues to receive therapy for his CMML, and is doing well.

## Discussion

In general, bleeding episodes in the spine are usually epidural but can occasionally be subdural or subarachnoid. They are usually associated with bleeding disorders, coagulopathy, thromboprophylaxis, arteriovenous malformation, spinal artery malformation, lumbar puncture or trauma, neoplasia, autoimmune disease (i.e., Behcet Syndrome) or, very rarely, idiopathic. The most frequent cause is coagulopathy with or without trauma, especially after lumbar puncture [1]. Komiyama, et al. postulated two types of spontaneous spinal subarachnoid hematoma, ventral and dorsal, with each having its own distinct clinical picture and prognosis. Ventral hemorrhages may present with acute back pain without neurological deficit, can have a benign prognosis, and surgical treatment is usually not necessary [2].

In our case, there were a few factors that likely contributed to the hemorrhage. First, the patient was thrombocytopenic at the time of both lumbar punctures, but only received a platelet transfusion prior to the first procedure. Secondly, the procedures were performed by a resident, and despite the supervision of the attending neuroradiologist, the procedures could have been more traumatic than if performed by someone with more experience. The intrathecal hemorrhage was predominantly ventrally located, suggesting that the lumbar puncture needle may have been inserted deep enough to injure the ventral venous plexus, which would contribute to extensive hemorrhage, especially in the context of prolonged thrombocytopenia. The hemorrhage extended cranially to the level of the conus medullaris, however the hemorrhage was admixed with CSF and predominantly located around the lumbar nerve roots. The patient presented with rapid onset of neurological deficit, but due to his significant medical comorbidities and poor overall oncologic prognosis, he did not undergo a surgical evacuation.

## Radiological findings

The gold standard for diagnosis of an intrathecal hemorrhage is Magnetic Resonance Imaging (MRI). Computed Tomography (CT) imaging, with or without myelography, can be utilized but image resolution and findings may be non-specific and non-diagnostic. Unless contraindicated, an early MRI should be done in patients with suspected spinal hemorrhages for an early diagnosis and management [3]. Differentiating between an epidural, subdural and a subarachnoid bleed can be difficult, is not well described in the literature and sometimes not possible radiologically. Occasionally there may be a mixed presentation, especially with subdural and subarachnoid hemorrhages presenting in the same patient at contiguous levels [4]. In sagittal or axial T2-weighted images, displacement of the hypointense dura can be used to differentiate between epidural or subdural location [5]. Epidural hematomas typically have a convex appearance and tend to be located dorsally with ventral dural displacement. It will also show a “curtain sign” if located ventrally due to the attachment of dura to the posterior longitudinal ligament by Hoffman’s ligament [6]. A subdural hematoma may have a semicircular appearance and tends to be more crescent shaped on axial images. An inverted “Mercedes-Benz Sign” has also been described as a typical finding in spinal subdural hematoma [7]. Shimada et al. recognized a black line on gradient echo T2-weighted MR imaging, representing edematous arachnoid between the abnormal signals and the cauda equina, thus helping in differentiation [3]. In patients with subarachnoid bleeding at the level of cauda equina, the blood in subarachnoid space will be diluted with CSF, defibrinated with normal pulsations, and admixed with the nerve roots giving a heterogenous appearance on MRI [8].

According to Domenicucci et al., MRI and CT are usually diagnostic when CSF or the contrast medium is detected surrounding the hematoma [1]. CT myelography may be needed in patients who cannot undergo MRI scan. A characteristic filling defect called “capping” is seen in subarachnoid bleeds especially those which are chronic [9,10].

## Management and prognosis

Komiyama et al. postulated that the ventral type of subarachnoid hemorrhage usually shows no neurological deficit, runs a benign course, and does not necessarily require surgical evacuation. However, the location of the hemorrhage does not seem to be the only factor in decision making [1,2,11]. Most case reports have shown that in the presence of neurological deficit or deterioration, surgical evacuation of the hematoma is the recommended mode of treatment of such disorder. Other treatment options include needle aspiration and conservative treatment [2,8,12-17]. Recovery of neurological function is most likely if surgery occurs within 8 hours from the onset of symptoms, and those patients with lumbosacral hemorrhages (L2-S1) had better recovery than those whose hemorrhages compressed the spinal cord itself (between C1 and L1) [18]. Prognosis also depends on preoperative neurological status, duration between onset of symptoms and surgery, and the rapidity of symptom progression [19]. In the review by Domenicucci et al., patients presenting in satisfactory general and neurological conditions were treated conservatively and had a rapid and complete recovery. Long-term outcome in patients who underwent surgery depends on the preoperative neurologic status [1].

In summary, spinal intrathecal hemorrhages are rare and have a variable prognosis depending on presentation, location, and severity of

the associated neurological injury. Although diagnosis can be difficult, MRI is the gold standard and the distinct imaging characteristics of intrathecal hemorrhages are important to know as they could drastically impact the management of the patient. As was described in previous studies, these hemorrhages can be successfully treated conservatively in the proper setting [1]. Despite our patient’s rapid neurologic decline and expansive hemorrhage, conservative management was elected and ultimately resulted in a good outcome. This contrasts with previous reports indicating that poor neurologic status on presentation correlates with poor long-term outcome, despite surgical intervention in many cases. It also suggests that conservative management of these lumbar intrathecal hemorrhages should be given serious consideration before more aggressive treatment options, even potentially in the presence of neurological deficits.

## References

1. Domenicucci M, Ramieri A, Paolini S, Russo N, Occhiogrosso G, et al. (2005) Spinal subarachnoid hematomas: our experience and literature review. *Acta Neurochir (Wien)* 147: 741-750.
2. Komiyama M, Yasui T, Sumimoto T, Fu Y (1997) Spontaneous spinal subarachnoid hematoma of unknown pathogenesis: case reports. *Neurosurgery* 41: 691-694.
3. Shimada Y, Sato K, Abe E, Miyakoshi N, Tsutsumi Y (1996) Spinal subdural hematoma. *Skeletal Radiol* 25: 477-480.
4. Kakitsubata Y, Theodorou SJ, Theodorou DJ, Miyata Y, Ito Y, et al. (2010) Spontaneous spinal subarachnoid hemorrhage associated with subdural hematoma at different spinal levels. *Emerg Radiol* 17: 69-72.
5. Chang FC, Lirng JF, Luo CB, Yen YS, Guo WY, et al. (2005) Evaluation of clinical and MR findings for the prognosis of spinal epidural haematomas. *Clin Radiol* 60: 762-770.
6. Küker W, Thiex R, Friese S, Freudenstein D, Reinges MH (2000) Spinal subdural and epidural haematomas: diagnostic and therapeutic aspects in acute and subacute cases. *Acta Neurochir (Wien)* 142:777-785.
7. Johnson PJ, Hahn F, McConnell J, Graham EG, Leibrock LG (1991) The importance of MRI findings for the diagnosis of nontraumatic lumbar subacute subdural haematomas. *Acta Neurochir (Wien)* 113: 186-188.
8. Ruelle A, Zerbi D, Andrioli G (2001) Spinal subarachnoid bleeding of unknown etiology. Case reports. *J Neurosurg Sci* 45: 53-57.
9. Frager D, Zimmerman RD, Wisoff HS, Leeds NE (1982) Spinal subarachnoid hematoma. *AJNR Am J Neuroradiol* 3: 77-79.
10. Gambacorta D, Reale F, De Falco D (1987) Spontaneous chronic spinal subarachnoid hematoma. Report of a case and review of the literature. *Spine (Phila Pa 1976)* 12: 716-718.
11. Kang HS, Chung CK, Kim HJ (2000) Spontaneous spinal subdural hematoma with spontaneous resolution. *Spinal Cord* 38: 192-196.
12. Hiyama H, Shimizu T, Yato S, Kobayashi N, Ono Y, et al. (1990) Widespread spontaneous spinal subarachnoid hematoma. Case report. *Article in Japanese. Neurol Med Chir (Tokyo)* 30: 842-847.
13. Langmayr JJ, Ortler M, Dessel A, Twerdy K, Aichner F, et al. (1995) Management of spontaneous extramedullary spinal haematomas: results in eight patients after MRI diagnosis and surgical decompression. *J Neurol Neurosurg Psychiatry* 59: 442-447.
14. Owaki K, Nakazawa S, Yajima K, Sugiura K, Yabe Y (1975) [Spontaneous spinal subarachnoid hematoma--case report (author's transl)]. *No Shinkei Geka* 3: 593-597.
15. Plotkin R, Ronthal M, Froman C (1966) Spontaneous spinal subarachnoid haemorrhage. Report of 3 cases. *J Neurosurg* 25: 443-446.
16. Russell NA, Benoit BG (1983) Spinal subdural hematoma. A review. *Surg Neurol* 20: 133-137.
17. Swann KW, Ropper AH, New PF, Poletti CE (1984) Spontaneous spinal subarachnoid hemorrhage and subdural hematoma. Report of two cases. *J Neurosurg* 61: 975-980.

18. Vandermeulen EP, Van Aken H, Vermylen J (1994) Anticoagulants and spinal-epidural anesthesia. *Anesth Analg* 79: 1165-1177.
19. Sunada I, Akano Y, Kidosaki Y, Shimokawa N, Yamamoto S (1995) Spontaneous spinal subarachnoid hematoma-case report. *Surg Neurol* 44: 133-136.