

Traumatic Bucket-Handle Tears of Both Menisci with Anterior Cruciate Ligament Injury on the Same Knee - A Case Report

Lin-Min Yang¹, Lin-Hsue Yang^{2*}

¹Orthopedic department, Cheng Ching General Hospital, Taichung, Taiwan

²Department of Surgery, Far Eastern Memorial Hospital, New Taipei City, Taiwan

Abstract

Bucket handle meniscal tears could be degenerative or traumatic. Most traumatic bucket handle tear of the meniscus is unilateral, either medial or lateral, and often associated with various degree injury of anterior cruciate ligament (ACL). However, traumatic bucket handle tear of both medial and lateral menisci on the same knee is very rare, and only cases were reported. We reported a case of traumatic bucket handle meniscal tears of both menisci with ACL partial tear on the same knee. Arthroscopic partial meniscectomy for both medial and lateral menisci was successfully performed.

Keywords: Bucket-handle; Medial and lateral; Meniscal tear

Introduction

Both the medial and lateral meniscus is important in maintaining knee joint stability and sharing load transmission across the knee joint [1,2]. Therefore, both of them are vulnerable to injury in knee joint trauma. There are several types of meniscal tears - longitudinal, bucket-handle, horizontal, radial, depending on the mechanism of the injury. Among these, bucket handle tears account for about 10% of all meniscal injuries and tend to happen in high velocity accident [3]. Most of bucket handle meniscal tear is either medial or lateral alone, and the medial meniscal injury happens three times more frequently. It could be traumatic or degenerative. Traumatic bucket handle meniscal tears are often associated with various degree injury of anterior cruciate ligament (ACL) [3]. However, both medial and lateral meniscal injuries on the same knee is very rare and few cases reported in literature [4-8]. Here, we present a case of traumatic bucket handle tear of both menisci with ACL partial tear on the same knee after a jump from about 2 meter height, and successfully treated by arthroscopic medial and lateral partial meniscectomy.

Case Presentation

A 30 year-old male patient sustained his right knee severe pain due to a jump from 2 meter height about one week ago. When landing, both the knees were hyper-flexed to counteract to the gravitational force of fall. Soon after injury, he was sent to other hospital where the radiographic images of his right knee showed no any sign of fracture. Only symptomatic treatment was given. However, the knee pain, swelling and locking sensation still persisted. Then, the patient came to our hospital for further investigation. On physical examination, the knee was locked in about 30 degrees of flexion and could not be extended nor flexed due to pain. Local tenderness over the joint line of medial and lateral collateral ligaments and grade one of anterior drawer test were noted. When trying to reduce the flexion deformity by pressing down on the patient's right knee, there was a mechanical obstruction which prohibited the complete extension of the knee. Mc Murray test for meniscal tear could not be performed due to relatively limited range of motion and pain. The magnetic resonance images (MRI) was arranged and showed a reduction of both medial and lateral menisci volume. Both the meniscal bucket handle tears commenced from posteriorly, extended anteriorly and prolapsed into the intercondylar notch (Figure 1). The ACL was edematous change and tear. In sagittal images, the displaced fragment of the medial meniscus presented as the so-called "double PCL-sign" [9,10]. On coronal images

with all four structures (two bucket-handle meniscus fragments, ACL and PCL) appeared in the inter-condylar notch to produce "quadruple cruciate sign" [5] (Figures 2 and 3), whereas the lateral meniscus was found to produce the "flipped meniscus sign" [11,12] (Figure 4) Mild intra-articular effusion with underlying tibia medial condylar bony edema was also present.

Under the impression of traumatic bucket handle tear of both medial and lateral menisci and ACL tear, the patient was submitted to arthroscopic surgery. On arthroscopic examination of both the medial and lateral compartments, incarceration of the medial and lateral compartment full length bucket-handle meniscal tears into the intercondylar notch was observed. Mild knee joint intra-articular effusion and the ACL partial tear with mild laxity were also noted. Since repair of such full length of medial and lateral meniscal of bucket-handle tears needed sophisticated skills beyond our reach, we

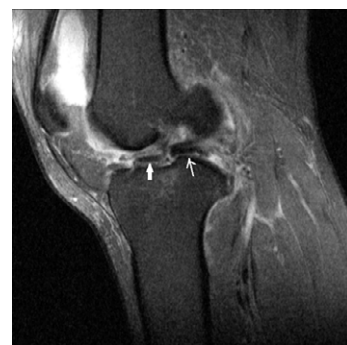

Figure 1: Sagittal T2-weighted MR image through the intercondylar notch shows displaced bucket-handle fragments of both medial (thin white arrow) and lateral (thick white arrow) meniscal tears like two consecutive silkworms

***Corresponding author:** Lin-Hsue Yang, Department of Surgery, Far Eastern Memorial Hospital, Banciao Dist., New Taipei City 220, Taiwan, Tel. +886-2-8966-7000, email : linbinn2000@yahoo.com.tw

Received April 18, 2015; **Accepted** August 01, 2015; **Published** August 08, 2015

Citation: Yang L, Yang L (2015) Traumatic Bucket-Handle Tears of Both Menisci with Anterior Cruciate Ligament Injury on the Same Knee - A Case Report. J Trauma Treat S2: 016. doi:10.4172/2167-1222.S2-016

Copyright: © 2015 Yang L, et al. This is an open-access article distributed under the terms of the Creative Commons Attribution License, which permits unrestricted use, distribution, and reproduction in any medium, provided the original author and source are credited.

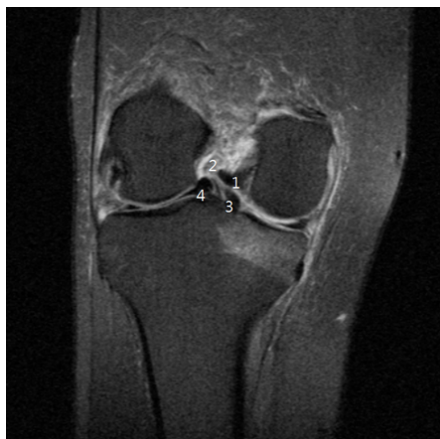

Figure 2: T2-weighted coronal MR image shows four structures in the intercondylar notch to produce the “quadruple cruciate sign”: (1) normal PCL; (2) increased signal ACL due to edematous change and partial tear; (3) displaced bucket-handle fragment from medial meniscal tear; (4) displaced bucket-handle fragment from lateral meniscal tear. Bone contusion in the medial tibial plateau is also noted.

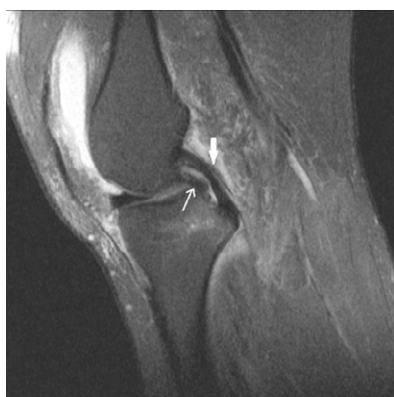

Figure 3: Sagittal T2-weighted MR image through the inter-condylar notch shows the double-posterior cruciate ligament (PCL) sign, which is characterized by the presence of a the displaced bucket-handle fragment of the medial meniscus (thin white arrow) lying parallel and anterior to the PCL (thick white arrow). Moderate joint effusion due to hemarthrosis is noted.

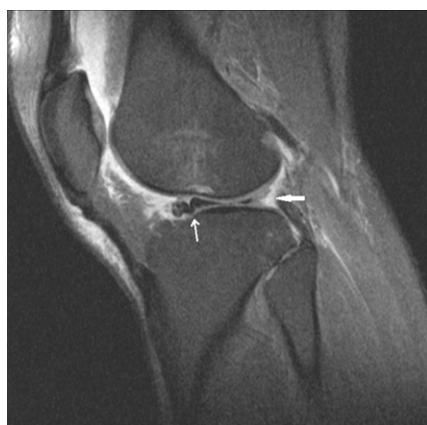

Figure 4: Sagittal T2-weighted MR image through the lateral compartment shows the bucket-handle fragment of the lateral meniscal tear (thin white arrow), posterior to the anterior horn, producing the flipped meniscus sign. Absence of the posterior horn was also noted (thick white arrow).

could not but choose an inferior treatment modality to excise both the medial and lateral menisci of bucket-handle tears (Figures 5-7). After operation, the patient was instructed to avoid vigorous sport and heavy labor work, in order to delay the occurrence of early knee osteoarthritis. One month later, the knee got full range of motion. Two months later, the patient reported no pain on his right knee. At our patient's follow-up examination twelve months after injury, his right knee was painless and stable with a full range of motion. The patient was suggested for regularly follow-up once a year.

Discussion

Bucket handle meniscal tears could be degenerative or traumatic. In degenerative cases, it is due to numerous repetitive minimal-trauma to menisci, which lead to degeneration changes and bucket handle tear [13]. The ACL could be intact or not. Traumatic bucket handle meniscal tears often accompanied by various degree injuries of ACL. The medial meniscus was injured three times more often than the lateral meniscus due to greater stress transmitted through the medial compartment [14]. Most of them were found in athletes, especially in soccer players.

Most patients with traumatic bucket handle tears of menisci complained of knee pain, local swelling and joint lockage. However, none of them is specific and pathognomonic for bucket handle meniscal

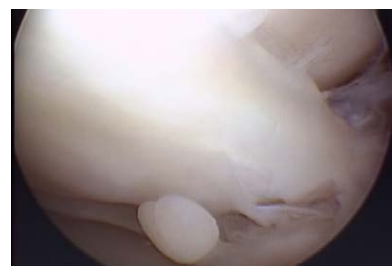


Figure 5: The bucket handle tear of medial meniscus was noted arthroscopy.

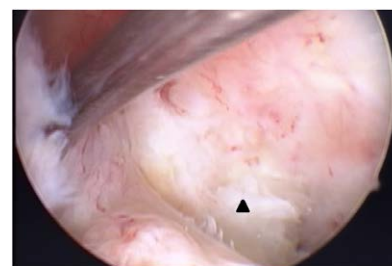

Figure 6: ACL partial tear was noted during arthroscopy. Remnant of bucket handle tear of medial meniscus after menisectomy was removed later (black triangle).

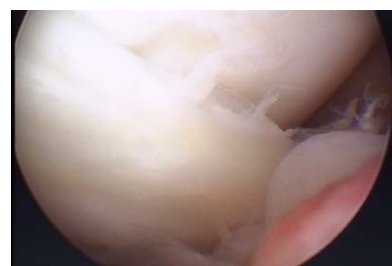

Figure 7: The bucket handle tear of lateral meniscus was noted arthroscopy.

tears [3]. However, traumatic bucket handle tears of both medial and lateral menisci on the same knee are very rare. Brammer et al. reported the first case of traumatic “bucket handle” tear on both menisci with ACL rupture on the same knee in 1999 [7]. As the MRI was carried out 22 months after trauma, it could not be determined if the injuries occurred at the same time. In 2007, Tecklenburg et al. reported a case documented by a video with bucket-handle tears of both medial and lateral menisci and acute ACL rupture of a professional ski racer, who sustained his right knee injury after landing from a jump in an alpine downhill race. As the case report presented by Tecklenburg et al., where the injured knee was forced into hyper-flexion with slightly rotated after landing at high velocity [8], in the present study, we could conclude that the injuries were traumatic and acute, as documented by MRI, performed one week after trauma. How both meniscal bucket-handle tear happened simultaneously is still unclear. However, all the reported cases seemed to happen when the injured knee was in hyper-flexion to counteract the great impact force transmitted across the knee joint.

MRI is by now most important in diagnosing a bucket-handle tear with high sensitivity and specificity estimated to be around 90% [15]. Several MRI signs have been described: fragments in the inter-condylar notch, quadruple cruciate sign [5], double PCL sign [9,10] and flipped meniscus sign [11,12]. Among all of them, the quadruple sign in the coronal image is most specific for both medial and lateral bucket handle tear by demonstrating all four structures (two bucket-handle meniscus fragments, ACL, PCL) in the inter-condylar notch [15-18]. While the sagittal image through the intercondylar notch in the reported case, two bucket-handle meniscus fragments appeared like two consecutive silkworms. We propose such “two silkworms sign” to describe the appearance of these two structures in the intercondylar notch should be another specific sign in identifying the presence of displaced medial and lateral bucket-handle tears. Despite the importance of MRI in making accurate diagnosis, arthroscopy remains the procedure of choice for both the final diagnosis and treatment.

Because of the important role of the meniscus in load transmission across the knee joint, it is better to perform meniscal repair instead of meniscectomy. If the repaired meniscus could heal, the functional outcome would be better and the chance of osteoarthritis would be much less [19,20]. In cases of failed meniscal repair, it could lead to early traumatic knee osteoarthritis. Arthroscopic resection should be reserved only when the fragment of bucket-handle tear is irreparable, irreducible or difficulty in successful repair. In such a limited space for arthroscopic procedure in the knee joint, successfully repairing a full length of both medial and lateral bucket-handle tears was extremely technical demanded. We had to perform partial meniscectomy for bucket handle tears of both menisci. In 2006, Shelbourne et al. reported favorable results, though not best, in digital radiographic evaluation of medial joint space narrowing after partial meniscectomy of bucket-handle medial meniscus tears in anterior cruciate ligament-intact knees after a long term follow-up of twelve years [21]. Although the functional outcome of the reported case in one year follow-up was good, osteoarthritis of the knee would happen in the future.

References

- Papageorgiou CD, Gil JE, Kanamori A, Fenwick JA, Woo SL, et al. (2001) The biomechanical interdependence between the anterior cruciate ligament replacement graft and the medial meniscus. *Am J Sports Med* 29: 226-231.
- Allen CR, Wong EK, Livesay GA, Sakane M, Fu FH, et al. (2000) Importance of the medial meniscus in the anterior cruciate ligament-deficient knee. *J Orthop Res* 18: 109-115.
- Shakespeare DT, Rigby HS (1983) The bucket-handle tear of the meniscus. A clinical and arthrographic study. *J Bone Joint Surg Br* 65: 383-387.
- Cetik O, Cirpar M, Eksioğlu F, Uslu M (2006) Simultaneous bucket handle tear of both medial and lateral menisci of a knee with chronic anterior cruciate ligament deficiency. *Knee Surg Sports Traumatol Arthrosc* 14: 356-359.
- Bugnone AN, Ramnath RR, Davis SB, Sedaros R (2005) The quadruple cruciate sign of simultaneous bicompartamental medial and lateral bucket-handle meniscal tears. *Skeletal Radiol* 34: 740-744.
- Dorsay TA, Helms CA (2003) Bucket-handle meniscal tears of the knee: sensitivity and specificity of MRI signs. *Skeletal Radiol* 32: 266-272.
- Brammer H, Sover E, Erickson S, Stone J (1999) Simultaneous identification of medial and lateral bucket handle tears: the Jack and Jill lesion. *AJR Am J Roentgenol* 173: 860-861.
- Tecklenburg K, Schoepf D, Hoser C, Fink C (2007) Anterior cruciate ligament injury with simultaneous locked bucket handle tears of both medial and lateral meniscus in a 19 year old female professional ski racer: a case report. *Knee Surg Sports Traumatol Arthrosc* 15: 1125-1129.
- Ryan RS, Marchinkow LO, Munk PL (2005) Radiology for the surgeon: Musculoskeletal case 35. Bucket-handle tear of medial meniscus—the double PCL sign. *Can J Surg* 48: 241-242.
- Weiss KL, Morehouse HT, Levy IM (1991) Sagittal MR images of the knee: a low-signal band parallel to the posterior cruciate ligament caused by a displaced bucket-handle tear. *AJR Am J Roentgenol* 156: 117-119.
- Haramati N, Staron RB, Rubin S, Shreck EH, Feldman F, et al. (1993) The flipped meniscus sign. *Skeletal Radiol* 22: 273-277.
- Stoller DW, Tirman PFJ, Bredella MA, Beltran S, Branstetter RM, et al. (2004) In: Stoller DW (ed) *Diagnostic imaging orthopaedics*, 1st edn. Amirsys, Salt Lake City 530-533.
- Meister K, Indelicato PA, Spanier S, Franklin J, Batts J (2004) Histology of the torn meniscus: a comparison of histologic differences in meniscal tissue between tears in anterior cruciate ligament-intact and anterior cruciate ligament-deficient knees. *Am J Sports Med* 32: 1479-1483.
- Baker BE, Peckham AC, Puppato F, Sanborn JC (1985) Review of meniscal injury and associated sports. *Am J Sports Med* 13: 1-4.
- Magee TH, Hinson GW (1998) MRI of meniscal bucket-handle tears. *Skeletal Radiol* 27: 495-499.
- Wright DH, De Smet AA, Norris M (1995) Bucket-handle tears of the medial and lateral menisci of the knee: value of MR imaging in detecting displaced fragments. *AJR Am J Roentgenol* 165: 621-625.
- Helms CA, Laorr A, Cannon WD Jr (1998) The absent bow tie sign in bucket-handle tears of the menisci in the knee. *AJR Am J Roentgenol* 170: 57-61.
- Ververidis AN, Verettas DA, Kazakos KJ, Tilkeridis CE, Chatzipapas CN (2006) Meniscal bucket handle tears: a retrospective study of arthroscopy and the relation to MRI. *Knee Surg Sports Traumatol Arthrosc* 14: 343-349.
- Shelbourne KD, Dersam MD (2004) Comparison of partial meniscectomy versus meniscus repair for bucket-handle lateral meniscus tears in anterior cruciate ligament reconstructed knees. *Arthroscopy* 20: 581-585.
- Baratz ME, Fu FH, Mengato R (1986) Meniscal tears: the effect of meniscectomy and of repair on intraarticular contact areas and stress in the human knee. A preliminary report. *Am J Sports Med* 14: 270-275.
- Shelbourne KD, Dickens JF (2006) Digital radiographic evaluation of medial joint space narrowing after partial meniscectomy of bucket-handle medial meniscus tears in anterior cruciate ligament-intact knees. *Am J Sports Med* 34: 1648-1655.