

# Treatment of Gummy Smile Appearance using the Modified Lip Repositioning Technique: A Pilot Study

Dannan A\* and Al-Sarraf I

Department of Periodontology, Syrian Private University, Damascus, Syria

\*Corresponding author: Aous Dannan, Department of Periodontology, Faculty of Dentistry, Syrian Private University, Damascus, Syria, Tel: +49-(0)2302-1795268; E-mail: aousdannan@yahoo.com

Received date: September 05, 2017; Accepted date: September 10, 2017; Published date: September 18, 2017

Copyright: © 2017 Dannan A, et al. This is an open-access article distributed under the terms of the Creative Commons Attribution License, which permits unrestricted use, distribution, and reproduction in any medium, provided the original author and source are credited.

## Abstract

Gummy smile is considered one of the esthetic problems that could face many people in the society. For a long time, lip repositioning technique was a classic surgical solution for correction of such cases.

The aim of this study was to test the short-term results of the modified technique of lip repositioning as a surgical solution for correction of gummy smile cases. Seven patients were included in the study. The modified lip repositioning technique previously described by Rao et al. was used to operate the patients and correct the gummy smile. Intra-oral measurements were recorded including the amount of the while-smiling gingival appearance before and one month after surgery. T-Test statistical analysis was done to compare the records.

The results showed a statistically significant decrease of gingival appearance one month post-surgery by 3.30 mm. The modified lip repositioning technique showed positive results in terms of correcting gummy smile cases. However, further longitudinal studies with larger sample size are still needed to distinguish any possible relapse due to this technique.

**Keywords:** Gummy smile; Lip repositioning; Pilot study; Gingivae

## Introduction

Smiling is one of the face expressions that arises due to several emotional aspects inside one's inner feelings. An attractive smile could be considered a basis to introduce a good and acceptable impression for others.

Many factors are considered to be related to a "beautiful smile", such as the position of upper lip line and the upper-to-lower lip junction [1].

Gummy smile (GS) is an oro-facial aesthetic disorder in which more than 3 mm of the keratinized gingiva is shown during normal smiling with a need to be corrected due to its disturbing appearance for some people [2].

Several factors could be contributed to GS; such as the change in teeth eruption directions, extreme dento-alveolar over-projection, and vertical overgrowth of upper jaw [3].

Conventional gingivectomy is a treatment choice for correction of some GS cases [4,5]. However, this technique is only indicated when short crowns are present. Here, the surgical cut is performed along the teeth neck lines and resulting in reducing the amount of appearing gingiva as well as lengthening the teeth to some extent.

Lip repositioning technique (LRT) introduces a suitable solution for GS. This surgical technique aims at preventing or limiting the upper back-retraction of muscles levator labii superioris [6]. However, patients with severe vertical maxillary excess cases are also not the ideal candidates for LRT and should be treated with orthognathic surgery [7].

The modified lip repositioning technique (MLRT) was firstly described by Rao et al. [8]. This technique is different from the conventional surgical lip repositioning as labial frenum is left untouched over here as it helps in maintain the midline for lip repositioning and reduces the morbidity associated with it.

This pilot study aimed at testing the short-term post-surgical results of MLRT as a surgical solution for GS cases.

## Materials and Methods

The sample of the study consisted of 7 patients (6 females and one male) who visited the Faculty of Dentistry at Syrian Private University (SPU) in Damascus, Syria. Those patients were seeking an esthetic treatment for GS.

The patients gave their oral consents to undergo surgical MLRT as a solution for the aesthetic problem. The probability of recurrence was also explained to the patients due to the lack of long-term observational studies.

The study protocol was approved by the authority of the Faculty of Dentistry at SPU.

Full documentation for every patient was done including photographic pictures and intra-oral measurements exhibiting the amount of gingival exposure in the maxilla during full-smiling situation from the free gingival line to the lower line of upper lip extending from the first upper right premolar to the first upper left premolar. All intra-oral measurements were done using gingival graduated probe (Williams).

Ten days before the surgery, all patients underwent professional teeth scaling and appropriate gingival treatment to guarantee inflammation-free conditions.

Regardless of the reason of GS for all patients, the surgical procedure was done as previously described by Rao et al. [8], as follows:

Local anesthesia (Lidocaine 2% with epinephrine 1:80,000) was administered locally at the vestibular mucosa from the maxillary right to left first molar. Bleeding points were induced at the mucogingival junction, which guided the first incision to be carried out. A partial thickness incision was made at the mucogingival junction from the mesial line angle of the right central incisor to the mesial line angle of the right first molar. A second partial thickness incision parallel to the first incision and 10–12 mm apical of the mucogingival junction was made in the labial mucosa. The incisions were connected at the central incisor region without involving the maxillary labial frenum and at the right first molar region creating a quadrilateral outline. The epithelium was then carefully dissected within this outline, leaving the underlying connective tissue exposed. The same procedure was carried out on the left side at the mucogingival. Care was taken to avoid damage to any minor salivary glands in the submucosa.

The parallel incision lines were approximated with interrupted stabilization sutures (silk 4/0). All postsurgical instructions were explained to patients and medications for 5 days were prescribed which included analgesic/anti edema (Brufen 400 mg twice daily for 5 days), antibiotic (Ogmentine 625 mg twice daily for 5 days), along with cold packs extra orally to decrease postsurgical swelling.

Patients were recalled after 10 days for suture removal and a followup. Re-evaluation and gingival measurements were further carried out after one month to see the stability of the results obtained.

Statistical analysis of the obtained data was achieved by means of a statistical software program (IBM SPSS Statistics 21). T-test for related samples was used to compare the measurements before and one month after surgery.

## Results

All participants (n=7) responded positively to the study and showed up one month later for the recall and reevaluation.

The results showed that the mean record of gingival appearance for all patients was  $5.92 \pm 0.46$  mm ranging between 5.25 mm and 6.62 mm before the surgery, and  $2.62 \pm 0.65$  mm ranging between 1.50 mm and 3.50 mm one month after the surgery (Mean  $\pm$  Standard Deviation) (Table 1).

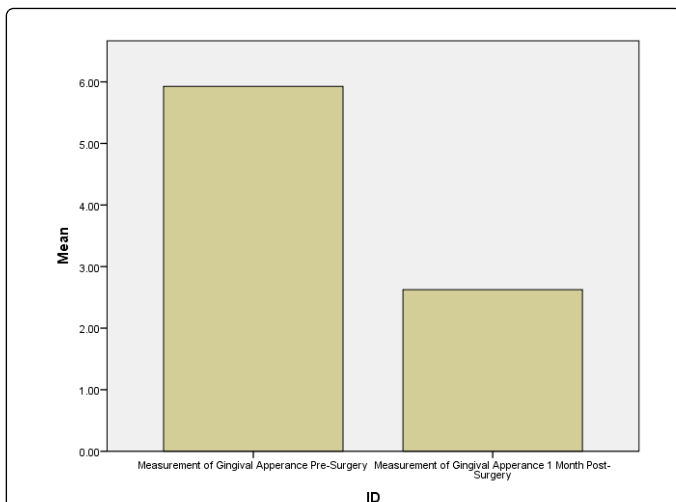
	Measurement of Gingival Appearance Pre-Surgery	Measurement of Gingival Appearance 1 Month Post-Surgery
Mean	5.9271	2.6243
Minimum	5.25	1.5
Maximum	6.62	3.5

**Table 1:** Mean records of gingival appearance before and after surgery.

The results of T-test statistical analysis to compare the means of gingival appearance before and one month after surgery showed a significant statistical difference ( $P < 0.05$ ) between the records mentioned on a confidence level of 95% (Mean=3.30,  $t=9.68$ /Sig=0.000 that is less than 0.05) (Table 2).

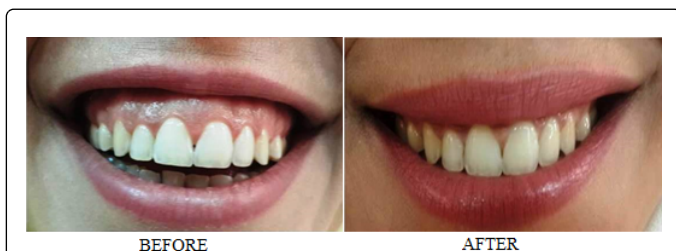Paired Samples Statistics								
		Mean	N	Standard Deviation	Standard Error Mean			
Pair 1	Measurement of Gingival Appearance Pre-Surgery	5.9271	7	0.46532	0.17587			
	Measurement of Gingival Appearance 1 Month Post-Surgery	2.6243	7	0.65686	0.24827			
Paired Differences							t	Sig. (2-tailed)
		Mean	Std. Deviation	Std. Error Mean	95% Confidence Interval of the Difference			
					Lower	Upper		
Pair 1	Measurement of Gingival Appearance Pre-Surgery - Measurement of Gingival Appearance 1 Month Post-Surgery	3.30286	0.90196	0.34091	2.46869	4.13703	9.688	0

**Table 2:** The results of T-test showing a significant statistical difference between means.

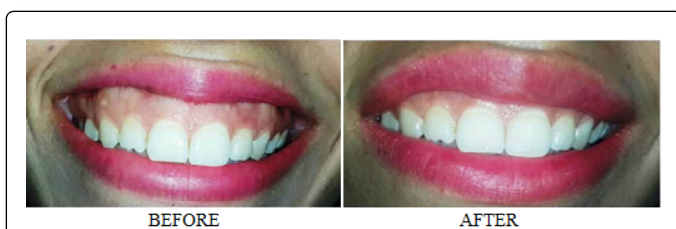

**Figure 1:** Amount of gingival appearance before and one month after surgery.

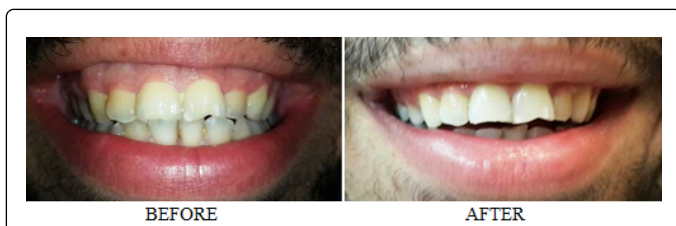The results indicated a significant decrease of gingival appearance of about 3.30 mm (Figure 1). Figures 2 to Figure 8 demonstrate the all cases of patients before and one-month after surgery.



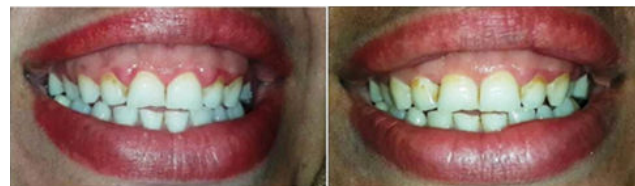**Figure 2:** The first patient; before and one-month after surgery.



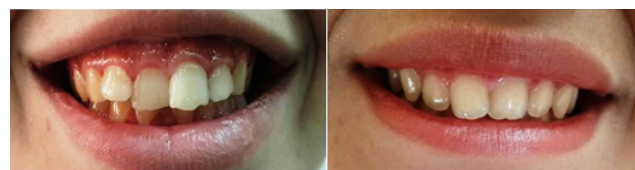**Figure 3:** The second patient before and one-month after surgery.



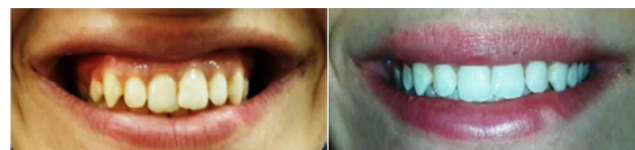
**Figure 4:** The third patient before and one-month after surgery.



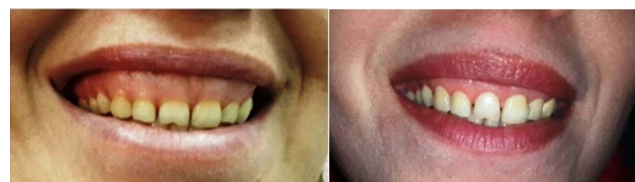**Figure 5:** The fourth patient before and one-month after surgery.



**Figure 6:** The fifth patient before and one-month after surgery.



**Figure 7:** The sixth patient before and one-month after surgery.



**Figure 8:** The seventh patient before and one-month after surgery.

## Discussion

Gummy smile is an embarrassing issue for many people from a psychological and social point of view. Such people always seek any possible treatment to correct this esthetic problem.

The original technique for the procedure was firstly described as cosmetic surgery by Rubinstein and Kostianovsky [9] for correction of a gummy smile caused by hypermobile lip. This surgical procedure was designed to have fewer postoperative complications when compared to orthognathic surgery besides being shorter and less aggressive. This surgical procedure reported no complications but there were reports of relapse. Thus this technique was further improvised by Miskinyar [10] to correct the relapse. Miskinyar however did not report when or how much relapse had occurred in his patients' group. These patients were re-operated using a more aggressive approach which included

myectomy and a partial resection of the muscle- levator labii superioris along with nerve repositioning before muscle resection. This was thought to eliminate muscle regeneration thus making the results more permanent. The only post-operative complication reported by the author was a postoperative paraesthesia that lasted 2.5 months for one patient.

The aim of the current study was to test the modified lip repositioning technique as a surgical solution for correcting GS based on the fact that such surgeries usually limit the up-direction shuttling of the upper lip during smiling, and therefore enhancing the appearance of smile by covering much amount of gingival tissues.

The inclusion criteria that were considered for choosing the patients were only a need for correcting the GS feature, and an absence of periodontitis (defined as exploring more than 2 teeth with probing depth more than 4 mm).

The current pilot study was limited in one month for observation. However, no negative effects or relapse was recorded in all cases.

Case reports by Rosenblatt and Simon [7] used an elliptical-shaped incision at the mucogingival junction and the alveolar mucosa, to reflect a partial-thickness flap, and an arbitrary excision of 10 to 12 mm of epithelium. They reported good results in one case of 8-month follow-up. Similar surgical procedure has been reported by Humayun et al. [11] with one year follow-up providing good results.

The technique used in MLRT does not interfere with the frenum, and therefore assures a stability of the medial line and symmetry.

All patients in our study were satisfied with the results obtained and did not mention any features related to nerve damages (i.e., numbness).

## Conclusion

The current pilot study indicated the efficacy of MLRT as a surgical solution for GS. Although such results need to be confirmed in

longitudinal studies including bigger sample size, they were significantly showed a decrease in the gingival appearance during smiling, and that was positively reflected upon patients and therefore enhanced their self-confidence.

## References

1. Tjan AH, Miller GD (1984) Some esthetic factors in a smile. *J Prosthet Dent* 51: 24-8.
2. Garber DA, Salama MA (1996) The aesthetic smile: diagnosis and treatment. *Periodontol* 2000 11: 18-28.
3. Ioi H, Nakata S, Counts AL (2010) Influence of gingival display on smile aesthetics in Japanese. *Eur J Ortho* 32: 633-7.
4. Gonçalves KJ, Agnoletto GG, da Cunha LF, Storrer CM, Deliberador TM (2017) Periodontal plastic surgery for treatment of gummy smile with cosmetic restoration treatment. *South Br Dent J* 1: 50-5.
5. Oberoi G, Chaudhry S, Yadav S, Talwar S, Verma M (2017) Correction of gummy smile using digital smile designing in conjugation with crown lengthening by soft-tissue diode laser. *J Dent Laser* 11: 14.
6. Simon Z, Rosenblatt A, Dorfman W (2007) Eliminating a gummy smile with surgical lip repositioning. *J Cos Dent* 23: 102-109.
7. Rosenblatt A, Simon Z (2006) Lip repositioning for reduction of excessive gingival display: A clinical report. *Int J Periodontics Restorative Dent* 26: 433-7.
8. Rao AG, Koganti VP, Prabhakar AK, Soni S (2015) Modified lip repositioning: A surgical approach to treat the gummy smile. *J Ind Soc Periodont* 19: 356-359.
9. Rubinstein A, Kostianovsky A, Rubinstein A, Kostianovsky A (1973) Aesthetic surgery of the malformation of the smile. *Pren Med Argent* 60: 952.
10. Miskinyar S (1983) A new method for correcting a gummy smile. *Plas Rec Surg* 72: 397-400.
11. Humayun N, Kolhatkar S, Souiyas J, Bhola M (2010) Mucosal coronally positioned flap for the management of excessive gingival display in the presence of hypermobility of the upper lip and vertical maxillary excess: A case report. *J Periodontolo* 81: 1858-63.