

## Unusual Cause of Severe Aortic Stenosis: Familial Hypercholesterolemia: A Case Report

Dioum M<sup>1\*</sup>, Fall L<sup>2</sup>, Leye M<sup>1</sup>, Cisse F<sup>3</sup>, Diagne JP<sup>4</sup>, Ndao SCT<sup>5</sup>, Diao M<sup>5</sup>, Diop IB<sup>1</sup> and Kane A<sup>6</sup>

<sup>1</sup>Cardiology Department of Fann Hospital, Faculty of Medicine, University Cheikh Anta Diop of Dakar, Senegal

<sup>2</sup>Dermatology Department, the Order of Malta Hospital, Dakar (CHOM), Senegal

<sup>3</sup>Laboratory of Medical Biochemistry, Faculty of Medicine, Senegal

<sup>4</sup>Ophthalmic Department of Abass NDAO Hospital, Faculty of Medicine, University Cheikh Anta Diop of Dakar, Senegal

<sup>5</sup>Cardiology Department, Aristide Le Dantec Hospital, Faculty of Medicine, University Cheikh Anta Diop of Dakar, Senegal

<sup>6</sup>Faculty of Medicine, University Cheikh Anta Diop of Dakar, Senegal

\*Corresponding author: Dioum M, Cardiology Clinic of CHU Fann, Cheikh Anta Diop University Hôpital, FANN - BP 5534, Dakar, Fann, Senegal, Tel: 221-77-655-18-83; E-mail: [momar.dioum@yahoo.fr](mailto:momar.dioum@yahoo.fr)

Received date: October 06, 2016; Accepted date: November 16, 2016; Published date: December 20, 2016

Copyright: © 2016 Dioum M, et al. This is an open access article distributed under the terms of the Creative Commons Attribution License, which permits unrestricted use, distribution, and reproduction in any medium, provided the original author and source are credited.

### Abstract

The main etiology of aortic stenosis in Africa is rheumatic fever in middle-age adults. We report the case of an aortic stenosis probably due to familial dyslipidemia. A patient of 24 years, male, was referred by his dermatologist for investigation of exertional dyspnea. Physical examination revealed regular heart sounds with a systolic murmur 4/6 at the aortic valve area and abolition of B2. There was no sign of heart failure. Lipid dosage showed high LDL and total cholesterol levels, 5.42 g/L and 6.23 g/L respectively. Triglyceride and HDL cholesterol levels were normal: 0.70 g/L and 0.62 g/L. Echocardiography found severe aortic stenosis with an aortic valve area of 0.6 cm<sup>2</sup>; a mean gradient of 68 mmHg and a maximum aortic jet velocity of 5.32 m/s. Coronary angiogram showed slight atheroma but angiographically normal coronary arteries. Dermatological examination showed tuberous xanthomas in pressure areas such as the elbows, knees, and buttocks. Ophthalmologic examination found corneal arcus in both eyes. The patient's current treatment associated a lipid-lowering diet, statin and diuretics. Although rheumatic heart disease is common in middle-aged adults, aortic stenosis of "atherosclerotic" origin is possible.

**Keywords:** Aortic stenosis; Hypercholesterolemia; Etiology

### Introduction

Familial hypercholesterolemia (FH) is an autosomal dominant genetic disease that leads to the increase of low density lipoprotein (LDL) cholesterol [1]. It comes in two forms of different severity. The FH heterozygous affects 1/200 to 1/500 subjects. The homozygous form, more severe, affects one in a million [2].

Although acute rheumatoid arthritis has long been the most frequent source of aortic stenosis (AS), the valvular sclerosis, so-called degenerative, is now the predominant etiology. This form of AR has long been regarded as a degenerative process linked to aging, of which it was therefore difficult to modify evolution. However, recent studies show that this disease has many similarities to atherosclerotic coronary artery disease (ACAD) in both pathophysiology and risk factor, suggesting that AS is in fact only one of the many manifestations of atherosclerosis [3]. However, in Africa, the etiology of aortic stenosis is dominated by acute rheumatic fever. We report the case of a patient with aortic stenosis probably related to a heterozygous FH.

### Observation

He was a patient of 24 years, male, followed in dermatology for tuberous xanthomas. Physical examination revealed a NYHA's stage III dyspnea. Familial history did not show any similar case with his mother and sister. His father died of unknown causes. Cardiac

auscultation had highlighted a midsystolic murmur 4/6 at aortic area irradiating at the neck's vessels and an abolition of B2. There was no peripheral sign of cardiac decompensation. Blood pressure was 120/65 mm Hg in the right arm and 100/60 mmHg in the left arm and the resting heart rate was of 51 beats/min. The electrocardiogram showed regular sinus rhythm and left ventricular hypertrophy with disturbances of repolarization type of ischemia subepicardial in apical-lateral. In biology, we found hypercholesterolemia with levels of total cholesterol at 6.23 g/l and LDL cholesterol at 5.42 g/l. HDL cholesterol was 0.62 g/l and triglycerides 0.70 g/l. The Doppler echocardiography concluded a very severe aortic stenosis on highly calcified tricuspid aortic valves, with an aortic area of 0.6 cm<sup>2</sup>/m<sup>2</sup> of body surface area calculated by continuity equation, an average gradient of 68 mmHg, a maximum speed of aortic flow at 5.35 m/s and a permeability index at 19% (Figure 1). There were no other valvular abnormalities. Ejection fraction of the left ventricle was normal. The coronarography objectified a coronary network moderately atheromatous without angiographically significant lesions (Figure 2). The dermatological examination showed tuberous xanthomas as nodular lesions sitting at the pressure areas (elbows, knees and buttocks) measuring 8 cm, painless, taking a tumor-like appearance of reddish color (Figure 3). Ophthalmologic examination showed corneal arc in both eyes. His treatment associated lipid-lowering diet, statins at high doses (atorvastatin 80 mg/day) and loop and potassium sparing diuretics. The patient is waiting for surgery for aortic valvular replacement. The opportunity to take a sample for histopathological analysis will be exploited during the gesture.

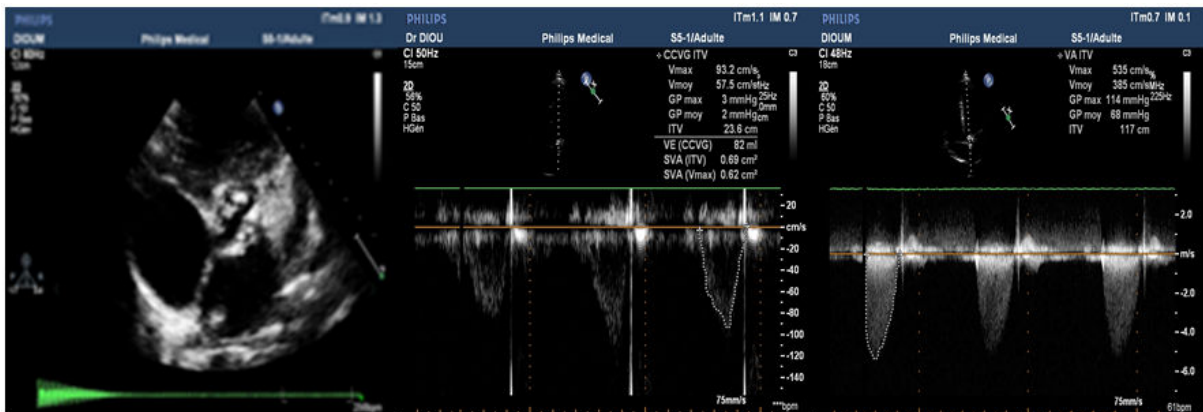


Figure 1: A: Transthoracic echocardiography parasternal short axis showing calcifications of aortic valve with reduced opening, B: Continuous-wave Doppler measurement of mean gradient, C: Pulsed-wave Doppler measurement of aortic valve area.

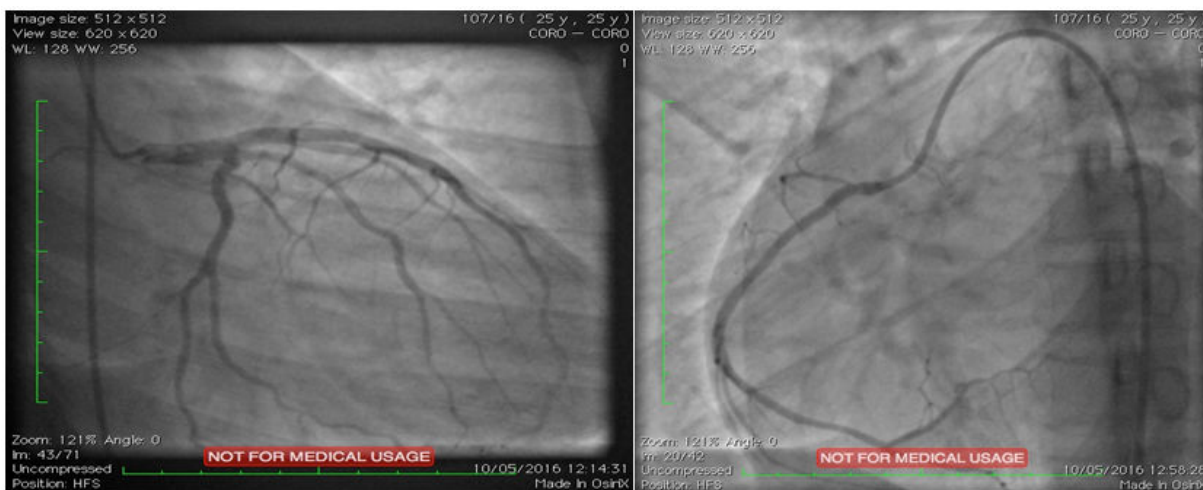

Figure 2: Coronary angiography showing normal arteries.

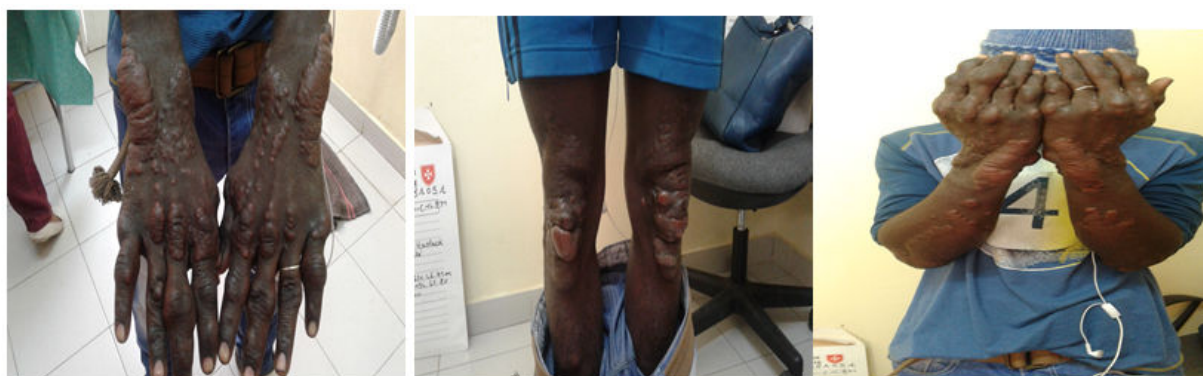

Figure 3: Tuberous xanthomas located at pressure areas.

## Discussion

Familial hypercholesterolemia is due to biological alteration of a pathogenic mutation carried by a single gene of the LDL receptor (LDLR). Other mutations were recently identified as the genes coding for ApoB, the LDLRAP1 (LDL receptor adapter protein 1) and PCSK9 (pro-protein convertase subtilisin / Kexin Type 9) [4,5]. Genetic analysis provides a definitive diagnosis and facilitates family screening. Given the complexity and the cost of the procedure, this genetic analysis was not performed on our patient and his siblings. However, this analysis has limitations with a low probability to identify the mutation [6,7]. Patients with FH have a long-term high risk for a cardiovascular disease which is of the order of 20 to 40% [8,9]. Valvular sclerosis has long been considered a degenerative process associated with aging. However, recent studies show that this disease has many similarities with atherosclerotic heart disease both in terms of the pathophysiology and of the risk factors suggesting that the AS would be one of the many manifestations of atherosclerosis [3,10,11]. The treatment of FH has the main purpose of reducing mortality and the effects of the atherosclerotic cardiovascular disease by reducing plasma LDL levels [1,12,13]. The therapeutic treatment in our patient consisted of a lipid-lowering diet associated with statins. Although it has a partial efficacy, association with ezetimibe or sequestering bile acids agents was not possible due to lack of availability. LDL apheresis would have been a treatment of choice for our patient, but was, unfortunately, not available.

## Conclusion

The AS has long been seen as a purely degenerative disease. The results presented in this article, however, support the concept that AS is an active disease that has many similarities with atherosclerosis and, therefore, likely to be altered by changes in feeding behaviors and/or pharmacological interventions.

## References

1. Genest J, Hegele RA, Bergeron J, Brophy J, Carpentier A, et al. (2014) Canadian Cardiovascular Society position statement on familial hypercholesterolemia. *Can J Cardiol* 30: 1471-1481.
2. Austin MA, Hutter CM, Zimmern RL, Humphries SE (2004) Genetic causes of monogenic heterozygous familial hypercholesterolemia: a HuGE prevalence review. *Am J Epidemiol* 160: 407-420.
3. Pibarot P, Dumesnil JG, Mathieu P (2007) New insight into the treatment of aortic stenosis. *Med Sci (Paris)* 23: 81-87.
4. Varret M, Abifadel M, Rabès JP, Boileau C (2008) Genetic heterogeneity of autosomal dominant hypercholesterolemia. *Clin Genet* 73: 1-13.
5. Marduel M, Carrié A, Sassolas A, Devillers M, Carreau V, et al. (2010) Molecular spectrum of autosomal dominant hypercholesterolemia in France. *Hum Mutat* 31: E1811-1824.
6. Turgeon RD, Barry AR, Pearson GJ (2016) Hypercholestérolémie familiale: révision du diagnostic, du dépistage et du traitement. *Can Fam Physician* 62: e4-e10.
7. Farnier M, Bruckert E, Boileau C, Krempf M (2013) Diagnostic et traitement des hypercholestérolémies familiales chez l'adulte: recommandations de la nouvelle société française d'athérosclérose (NFSA). *La presse médicale* 42: 930-950.
8. Alonso R, Mata N, Castillo S, Fuentes F, Saenz P, et al. (2008) Cardiovascular disease in familial hypercholesterolaemia: influence of low-density lipoprotein receptor mutation type and classic risk factors. *Atherosclerosis* 200: 315-321.
9. Humphries SE, Whittall RA, Hubbart CS, Maplebeck S, Cooper JA, et al. (2006) Genetic causes of familial hypercholesterolaemia in patients in the UK: relation to plasma lipid levels and coronary heart disease risk. *J Med Gen* 43: 943-949.
10. Rajamannan NM, Gersh B, Bonow RO (2003) Calcific aortic stenosis: from bench to the bedside-emerging clinical and cellular concepts. *Heart* 89: 801-805.
11. Chan KL (2003) Is aortic stenosis a preventable disease? *J Am Coll Cardiol* 42: 593-599.
12. Watts GF, Gidding S, Wierzbicki AS, Toth PP, Alonso R, et al. (2014) Integrated guidance on the care of familial hypercholesterolaemia from the International FH Foundation. *Int J Cardiol* 171: 309-325.
13. European Association for Cardiovascular Prevention & Rehabilitation, Reiner Z, Catapano AL, De Backer G, Graham I, et al. (2011) The Task Force for the management of dyslipidaemias of the European Society of Cardiology (ESC) and the European Atherosclerosis Society (EAS) ESC/EAS guidelines for the management of dyslipidemia. *Eur Heart J* 32: 1769-1818.