

Use of Venovenous Extracorporeal Membrane Oxygenation to Anticipate Difficult One Lung Ventilation in Thoracic surgery

Perdomo JM^{1*}, Gomar C¹, Navarro R¹, Mata MT¹ and Gimferrer J²

¹Department of Anesthesiology, Clinic hospital, Barcelona, Spain

²Thoracic Surgery, Clinic hospital, Barcelona, Spain

*Corresponding author: Perdomo JM, Department of Anesthesiology Clinic hospitalVillarroel 170, 08036 Barcelona, Spain, E-mail: JMPERDOM@clinic.ub.es

Received date: Jan 19, 2015, Accepted date: Feb 23, 2015, Published date: Feb 27, 2015

Copyright: © 2015 Perdomo JM, et al. This is an open-access article distributed under the terms of the Creative Commons Attribution License, which permits unrestricted use, distribution, and reproduction in any medium, provided the original author and source are credited.

Abstract

Thoracic surgery may create clinical scenarios where the maintenance of a correct oxygenation and ventilation may be challenging and could lead to incomplete surgery despite cardiovascular stability. Recently, venovenous extracorporeal membrane oxygenation (V-V ECMO) has emerged as an alternative to manage these situations when neither one lung ventilation (OLV) nor other ventilation and oxygenation techniques are feasible or sufficient due to associated lung disease or difficult airway. Here, we report the use of V-V ECMO support in two cases of thoracic surgery in which difficult OLV was anticipated. From the experience gathered in these two cases, we recommend to consider the use of V-V ECMO in selected patients with compromised airway or significant disease of the contralateral surgical hemithorax where conventional options cannot guarantee a correct ventilation and oxygenation. However, V-V ECMO use is not free of complications, being bleeding one of the most frequent and severe problems in surgical patients, which must be thoroughly prevented and treated by the anesthesiologist, the surgeon and the perfusionist.

Keywords: Lung ventilation; Thoracic surgery; Oxygenation techniques

Case Report

Thoracic surgery can create clinical scenarios where the maintenance of a correct oxygenation and ventilation may be challenging, compromising the completion of the surgery even under cardiovascular stability. Recently, venovenous extracorporeal membrane oxygenation (V-V ECMO) has emerged as an alternative to manage these situations [1]. Perioperative use of V-V ECMO has already been reported as a bridge therapy to lung transplantation [2], primary lung transplantation graft failure and during intraoperative anesthetic management when neither one lung ventilation (OLV) nor other ventilation and oxygenation techniques were feasible or sufficient due to associated lung disease or difficult airway [3-7]. However, V-V ECMO use is not free of complications, being bleeding one of the most frequent and severe problems in surgical patients. Here, we report the use of V-V ECMO support in two cases of thoracic surgery in which difficult OLV was anticipated.

Case 1

Right thoracotomy in a patient with a bronchopleural fistula.

A 37-year-old man was admitted for right metastatic pleural implants resection through right thoracotomy. His medical history included a diagnosis of malignant thymoma four years before. For this reason, he had been operated in several occasions to resect pleural, pericardial and diaphragmatic recurrences. Unfortunately, he developed a bronchopleural fistula that required a left thoracostomy one year before the present operation.

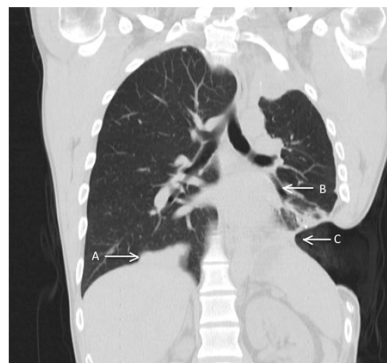


Figure 1: Preoperative computed tomography scan assessment of the thorax-case1. Coronal plane showing (A) metastatic implants in the right hemithorax, (B) fistula and (C) left thoracostomy.

Intraoperative use of V-V ECMO was considered since difficult left OLV was anticipated due to the existence of left bronchopleural fistula and left thoracostomy (Figure 1). Anesthetic induction and orotracheal intubation with a 41-Fr left double lumen tube (DLT) were performed uneventfully under total intravenous anesthesia (TIVA). Anesthetic monitoring included ECG, invasive arterial pressure, central venous pressure through a left femoral venous catheter, transesophageal echocardiography (TEE), and bispectral index (XP Platform, Aspect Medical*). An activated coagulation time (ACT) of 295 s was obtained after administration of 1 mg Kg⁻¹ of sodium heparin. The right jugular internal (19-Fr) and right femoral (25-Fr) veins were cannulated. After confirming the correct placement of the V-V ECMO cannulae with mid-esophageal bivalvular view in TEE, the

patient was turned to left lateral decubitus position and the correct placement of DLT was confirmed with fibre optic bronchoscopy (FOB).

The V-V ECMO outflow was increased gradually up to 2200 ml min⁻¹ and then left protective OLV was started, when low pulmonary compliance and leaks were seen as anticipated. Initial oxygen desaturation was treated with continuous positive airway pressure (CPAP) of 5 cm of H₂O on the right lung and adjustment of V-V ECMO parameters, to obtain PaCO₂ <45 mmHg and arterial oxygen saturation >97%.

After metastatic implants were resected and surgery was finished without complication, bilateral lung ventilation was reestablished and the patient was gradually weaned from V-V ECMO support without complications. The final ACT was 172 s. Therefore, 50 mg of protamine were administered and the cannulae were removed with a posterior manual compression of the insertion sites during 10 minutes. Bleeding through pleural drainage was negligible. After tracheal extubation in the operating room, the patient was transferred to the intensive care unit (ICU). No adverse events were recorded and the patient was discharged from the hospital eight days after the operation without any complications.

Case 2

Tracheal and both main bronchi tumor resection through right thoracotomy

A 68-year-old woman was admitted to evaluate a tracheal tumor (Figure 2) six days before surgery. A FOB was performed under spontaneous ventilation, sedation and local anesthesia administered by the anesthesiologist at the endoscopic respiratory unit. During the FOB, a hypervascularized and pedunculated tumor was observed in the lower third of the trachea obstructing both main bronchi lumen (Figure 3). The tumor was biopsied what unfortunately caused profuse bleeding that led to respiratory failure and cardiac arrest. In consequence, cardiopulmonary resuscitation maneuvers and orotracheal intubation were performed and spontaneous circulation was reestablished. Next, a new FOB performed through the orotracheal tube, showed a decrease of bleeding. The patient was transferred to ICU, under sedation, tracheal intubation and without active bleeding. Oxygenation was difficult and several attempts to wean from mechanical ventilation were unsuccessful due to mechanical airway obstruction. The clinical course was complicated by severe arterial hypertension. The pathological study of the biopsy showed a tracheal carcinoid cystadenoma.

Therefore, a tumor resection was planned for the 6th day after ICU admission through right thoracotomy under OLV. After discussion among the multidisciplinary team members, early spontaneous ventilation was considered desirable to avoid positive airway pressure that could be detrimental for the tracheal suture. Due to the respiratory difficulties observed during the previous days in ICU, as well as the anatomical location of the tumor and the complexity of the surgical procedure, it was considered that the use of V-V ECMO support would probably be necessary during the surgery and in the immediate postoperative period to maintain oxygenation and ventilation with spontaneous ventilation. Anesthetic technique and monitoring were performed as described in the first case. After the administration of 1 mg Kg⁻¹ of sodium heparin the ACT was 163 s. As the orotracheal tube number 7.5 that had the patient partially compressed the tumor and the bleeding risk was high it was decided to

keep it in place and a bronchial blocker (HS Hospital service®) was placed into the right main bronchus under FOB guidance. The advancement of the bronchial blocker was difficult due to tumor obstruction and bleeding. The internal jugular (15-F) and femoral (21-F) veins were cannulated. After confirming the correct placement of the V-V ECMO cannulae with mid-esophageal bivocal view in TEE, the patient was turned to left lateral decubitus position.

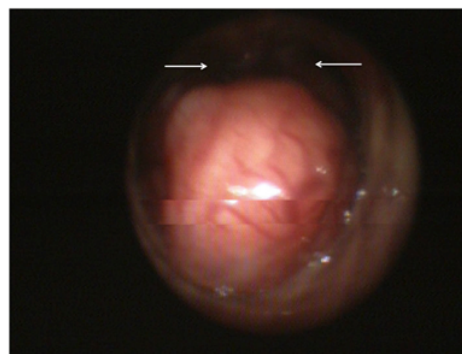


Figure 2: Preoperative bronchoscopy - case 2. Picture showing the near complete obstruction of both bronchus at the carina level.

The V-V ECMO outflow was increased gradually to 3120 ml min⁻¹ aiming the same gasometric data as described in case 1. Left OLV through the orotracheal tube keeping the right bronchial blocker inflated was ineffective due to tumor obstruction. Therefore, it was necessary to adjust V-V ECMO parameters to restore correct PaCO₂ and oxygen saturation. In addition, during tracheal tumor resection, apneic oxygenation was performed on the left main bronchus through the surgical field. During the procedure, an important bleeding associated to unstable cardiovascular status occurred that made difficult to maintain V-V ECMO flow. Consequently, administration of fluid and blood products was required. After the transfusion of 12 packed red blood cells, 1 L of fresh frozen plasma and 1 pool of platelets, laboratory test showed an INR of 1.37, prothrombin time of 55%, platelet count of 96 X 09/L, and fibrinogen of 130 mg-dl⁻¹. Unfortunately, other coagulation tests such heparin concentration and thromboelastography were not available. A single dose (1 g) of tranexamic acid was empirically administered considering that fibrinolysis could be a contributing factor. At the end of the procedure, a tracheotomy was performed in order to facilitate early recovery of spontaneous ventilation and airway secretion aspiration. Moreover, double lung protective ventilation was started without complications. However, an important diffuse bleeding (superior to 400 ml h⁻¹) persisted before the end of the surgery without an obvious surgical cause despite an ACT of 102 s, a normal body temperature and an adequate correction of acid-base disorder. Given the difficulty to control bleeding and considering that adequate oxygenation and ventilation were obtained with conventional ventilator settings, the multidisciplinary team (anesthesiologist, thoracic surgeon and perfusionist) decided to attempt the weaning process from ECMO. Even if spontaneous ventilation was considered desirable, the actual bleeding status forced a change in patient's approach, as anticoagulation needed for ECMO would be unsustainable. In case that the ECMO weaning process wouldn't have been tolerated, the plan would have been to continue the ECMO support without heparin. The patient was gradually weaned from V-V ECMO support without

complications. The ACT was corrected after reversion of protamine and the cannulae were removed with a posterior manual compression of the insertion site during 10 minutes. Bleeding through the pleural drainage decreased but remained (100 ml h^{-1}) during the first 6 hours in ICU. Consequently, 4 packed blood cells, 1 pool of platelets and 1 L of fresh frozen plasma were transfused in the ICU. After 48 hours the bleeding ceased and the coagulation times normalized. However, the patient presented significant complications consisting in a hospital-acquired pneumonia and a delayed right hemothorax that required drainage placement two weeks after surgery. Therefore, weaning from mechanical ventilation was difficult and complicated by the uncontrollable arterial hypertension. Unfortunately, dehiscence of the tracheal suture finally occurred, requiring a new surgery. Despite the surgery, the leak persisted and the patient died.

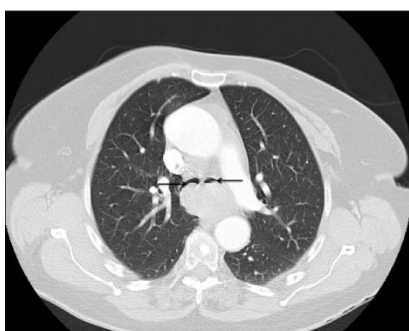


Figure 3: Preoperative computed tomography scan assessment of the thorax-case 2. Transverse plane showing the near complete obstruction of both main bronchus.

Discussion

From our experience, it is crucial to increase the intraoperative team experience in the use of V-V ECMO for difficult ventilation and airway management in thoracic surgery. In both cases described, the main issue for intraoperative management was the requirement of OLV for the surgical approach in a clinical scenario where difficult OLV was anticipated. In the first case, the difficulty was due to an injury in the dependent lung and in the second case, a tracheal and both main bronchi obstruction by a tumor. The V-V ECMO support was considered as a first option in both cases. Other options such as high frequency jet ventilation (HFJV) weren't considered due to the risk of barotrauma and worsening of bronchopleural fistula in the first case, and due to the obstruction of the flow by the tumor that could lead to distal air trapping in the second case. The management of both cases suggests that V-V ECMO is a valuable option for the intraoperative management in thoracic surgery where difficult OLV is anticipated. However, the use of V-V ECMO is not exempt of complications.

The V-V ECMO use had been described in ICU as part of failure respiratory management in patients with a stable cardiovascular status [8,9], in the perioperative period of lung transplantation [2] and as rescue strategy in acute airway obstruction [7,10]. However, there are only a few case reports of V-V ECMO establishment in situations where difficult OLV was anticipated [3,4,6,11]. Despite its successful use in these published cases, [3,4,6,11] V-V ECMO support during thoracic surgery has several anesthetic implications. First, the use of TIVA technique is compulsory. Second, the higher difficulty at

maintaining a normovolemic status to prevent recirculation of the system flow but at the same time preventing volume overload and its deleterious effects in thoracic surgery [12]. Finally, hemorrhagic complications are more frequent and severe. In addition to bleeding, cannulation is the other principal complication associated to the use of V-V ECMO [8]. Cannulation may be performed with one or two cannulae. The most frequent places for cannulation are directly in the right atrial, in the inferior and superior cave veins, and in the right femoral vein [13]. In the cases reported in the literature of V-V ECMO use in thoracic surgery, as well as in our cases, the cannulae were placed in the internal jugular and the right femoral veins through the Seldinger technique. It is mandatory to confirm the correct placement of the cannulae through the mid-esophageal bivocal view in TEE. The cannulae must be located with the longest possible distance between them to avoid recirculation of the ECMO [14]. The correct placement of the cannulae should be maintained during all the possible changes of both arm and thorax position along the surgery. Recently, single-venous percutaneous cannulation with dual stage cannula (Avalon Elite[®]) has allowed less traumatic access and more comfortable experience for the patient. This technique can also be used in extubated patients, being an option to maintain the ECMO support as a bridge to lung transplantation [15,16].

Bleeding control is the greatest challenge in the perioperative use of ECMO as illustrated by the second case presented in this report. The bleeding associated to both the surgery and the cannulation sites of the ECMO is a frequent complication with an incidence of 22.4% and 11.5%, respectively [1,13,17]. Generally, bleeding is caused by multiple factors including hypothermia, thrombocytopenia and fibrinolysis associated to the surgery. However, a key factor is the anticoagulation mediated by heparin required during the ECMO. The objective of ACT for V-V ECMO is usually lower than the ones for veno-arterial ECMO (V-A ECMO) and cardiopulmonary by-pass, oscillating between 160 and 180s. The use of ECMO without heparin during a short period of time has been described as an alternative strategy to reduce the bleeding risk. V-A ECMO without heparin has been used during the perioperative period of cardiogenic shock while V-V ECMO without heparin has been used during the oxygenation and ventilation support of traumatic patients [18-20]. However, there is no evidence of V-V ECMO use without heparin in cases as the ones we present in this report. A team approach with the anesthesiologist, the surgeon and the perfusionist is crucial for anticoagulation management and its consequences. In the first case, the patient didn't have hemodynamic risk factors and arrived to the procedure in good condition. Accordingly, the use of V-V ECMO was well tolerated, allowing the performance of the surgical procedure with optimal results. Oppositely, in the second case, the patient was in a worse condition before the surgery. On the one hand, she had received cardiopulmonary resuscitation six days before the surgery. On the other hand, her clinical course during the ICU admission was complicated under aggressive treatment. In consequence, V-V ECMO made the surgical procedures feasible but was associated to a difficult-to-control bleeding complication and cardiovascular instability from the beginning of the V-V ECMO. Despite the bleeding was not the direct cause of death, it certainly complicated the postoperative treatment.

In conclusion, V-V ECMO is an increasingly accessible and useful option to manage ventilation and oxygenation problems in thoracic surgery but it is not exempt of fundamental risks. From the experience gathered in these two cases, we conclude that the use of V-V ECMO may be a valuable tool in highly selected cases with compromised

airway or significant disease of the contralateral surgical hemithorax where conventional options (OLV and HFJV) cannot guarantee a correct ventilation and oxygenation. However, the most severe complication associated to the V-V ECMO use in surgical patients is bleeding, which must be thoroughly prevented and treated by the anesthesiologist, the surgeon and the perfusionist.

References

1. Barash PG, Landoni G, Odonkor PN, Stansbury L, Garcia JP, et al. (2013) Perioperative Management of Adult Surgical Patients on Extracorporeal Membrane Oxygenation Support. *J Cardiothorac Vasc Anesth* 27: 329-344.
2. Blum JM, Woodcock BJ, Dubovoy A V, Dubovoy T, Masood M, et al. (2013) Perioperative management of bridge-to-lung transplant using ECMO *ASAIO J* 59: 331-335.
3. Gourdin M, Dransart C, Delaunois L, Louagie Y a G, Gruslin A, et al. (2012) Use of venovenous extracorporeal membrane oxygenation under regional anesthesia for a high-risk rigid bronchoscopy. *J Cardiothorac Vasc Anesth* 26: 465-467.
4. Keeyapaj W, Alfirevic A (2012) Carinal resection using an airway exchange catheter-assisted venovenous ECMO technique. *Can J Anaesth* 59: 1075-1076.
5. Kolníková I, Kunstýř J, Lindner J, Lipš M, Kopecký P, et al. (2012) Extracorporeal membrane oxygenation used in a massive lung bleeding following pulmonary endarterectomy. *Prague Med Rep* 113: 299-302.
6. Schiff JH, Köninger J, Teschner J, Henn-Beilharz a, Rost M, et al. (2013) Venovenous extracorporeal membrane oxygenation (ECMO) support during anaesthesia for oesophagectomy. *Anaesthesia* 68: 527-530.
7. Thung A, Hayes D, Preston T, Tobias J (2012) Respiratorio Support Including Emergent Extracorporeal Membrane Oxigenation As a Bridge to Airway Dilatation Following Perioperative Broncial Occlusion. *M E J ANESTH* 21: 879-888.
8. Zangrillo A, Landoni G, Biondi-Zoccai G, Greco M, Greco T, et al. (2013) A meta-analysis of complications and mortality of extracorporeal membrane oxygenation. *Crit Care Resusc* 15: 172-178.
9. Peek GJ, Mugford M, Tiruvoipati R, Wilson A, Allen E, et al. (2009) Efficacy and economic assessment of conventional ventilatory support versus extracorporeal membrane oxygenation for severe adult respiratory failure (CESAR): a multicentre randomised controlled trial. *Lancet* 374: 1351-1363.
10. Willms DC, Mendez R, Norman V, Chammas JH (2012) Emergency bedside extracorporeal membrane oxygenation for rescue of acute tracheal obstruction. *Respir Care* 57: 646-649.
11. Smith IJ, Sidebotham D a, McGeorge AD, Dorman EB, Wilsher ML, et al. (2009) Use of extracorporeal membrane oxygenation during resection of tracheal papillomatosis. *Anesthesiology* 110: 427-429.
12. Assaad S, Popescu W, Perrino A (2013) Fluid management in thoracic surgery. *Curr Opin Anaesthesiol* 26: 31-39.
13. Wiles MD (2013) Blood pressure management in trauma: from feast to famine? *Anaesthesia* 68: 445-449.
14. Mazzeffi M, Fischer S (2013) Transesophageal echocardiographic guided placement of a right internal jugular dual-lumen venovenous extracorporeal membrane oxygenation (ECMO) catheter. *J Cardiothorac Vasc Anesth* 27: e46-47.
15. Reeb J, Falcoz P-E, Santelmo N, Massard G (2012) Double lumen bi-cava cannula for veno-venous extracorporeal membrane oxygenation as bridge to lung transplantation in non-intubated patient. *Interact. Cardiovasc. Thorac Surg* 14: 125-127.
16. Bermudez CA, Rocha R V, Sappington PL, Toyoda Y, Murray HN, et al. (2010) Initial Experience With Single Cannulation for Venovenous Extracorporeal Oxygenation in Adults. *Ann Thorac Surg* 90: 991-995.
17. Conrad S, Rycus PT, Dalton H (2004) Extracorporeal Life Support Registry Report. *ASAIO J* 51: 4-10.
18. Lamarche Y, Chow B, Bédard A, Johal N, Kaan A, et al. (2010) Thromboembolic events in patients on extracorporeal membrane oxygenation without anticoagulation. *Innovations (Phila)* 5: 424-429.
19. Muellenbach RM, Kredel M, Kunze E, Kranke P, Kuestermann J, et al. (2012) Prolonged heparin-free extracorporeal membrane oxygenation in multiple injured acute respiratory distress syndrome patients with traumatic brain injury. *J Trauma Acute Care Surg* 72: 1444-1447.
20. Arlt M, Philipp A, Voelkel S, Rupperecht L, Mueller T, et al. (2010) Extracorporeal membrane oxygenation in severe trauma patients with bleeding shock. *Resuscitation* 81: 804-809.