

## Visual Outcome in Ocular Toxoplasmosis: A Case Series of 30 Patients from Ghana

Emmanuel Kwasi Abu<sup>1\*</sup>, Johnson Nyarko Boampong<sup>2</sup>, Richmond Afoakwah<sup>2</sup>, Elvis Ofori Ameyaw<sup>2</sup>, Michael Ntodie<sup>1</sup> and Irene Ayi<sup>3</sup>

<sup>1</sup>Department of Optometry, School of Physical Sciences, University of Cape Coast, Ghana

<sup>2</sup>Department of Biomedical and Forensic Sciences, School of Biological Sciences, University of Cape Coast, Ghana

<sup>3</sup>Department of Parasitology, Noguchi Memorial Institute for Medical Research, College of Health Sciences, University of Ghana, Ghana

\*Corresponding author: Dr. Emmanuel Kwasi Abu, Department of Optometry, School of Physical Sciences, University of Cape Coast, Ghana, Tel: +233244990030; E-mail: [eabu@ucc.edu.gh](mailto:eabu@ucc.edu.gh)

Received date: June 13, 2015, Accepted date: Aug 07, 2015, Published date: Aug 13, 2015

Copyright: © 2015 Abu et al. This is an open-access article distributed under the terms of the Creative Commons Attribution License, which permits unrestricted use, distribution, and reproduction in any medium, provided the original author and source are credited.

### Abstract

**Purpose:** To determine visual outcome (low vision and blindness) in patients with inactive ocular toxoplasmosis.

**Methods:** This study employed a cross sectional design involving a series of 30 patients with inactive toxoplasmic ocular lesions. Ophthalmic assessment including best corrected visual acuity (BCVA) measurement, slit lamp biomicroscopy, and dilated fundus examination by indirect ophthalmoscopy was performed on all participants. Ocular toxoplasmosis was diagnosed based on characteristic retinal lesions in addition to a positive serologic testing using commercial ELISA kits. Visual impairment (VI) was determined based on the International Classification of Diseases.

**Results:** Their ages ranged from 16-59 years (mean age of  $34.2 \pm 14.19$ ), with 19 (63.3%) males and 11 (36.7%) females. There were 33 infected eyes in all (3 patients had bilateral cases). The most common complaint (77%) was blurred vision in the infected eyes. 11 (33%) eyes had mild or no visual impairment (VI category 1), 22 (67%) eyes had low vision ( $VA < 6/18$ ), and 11 (33%) eyes were blind ( $VA < 3/60$ ). Posterior pole ( $p < 0.001$ ) and larger retinal lesions ( $p = 0.04$ ) were the major causes of visual impairment. However, there was no association between visual impairment and the number of lesions occurring in the infected eyes ( $\chi^2 = 3.52$ ,  $p = 0.11$ ). Older patient age was significantly associated with: posterior pole lesions (0.003), larger retinal lesion sizes ( $p = 0.001$ ) and multiple lesions ( $p = 0.001$ ). Only three cases each of strabismus and bilateral involvement suggest that acquired infection is more common in this Ghanaian population.

**Conclusion:** Low vision and blindness were common in *Toxoplasma* eye infection in our Ghanaian population and that posterior pole and larger retinal lesions rather than multiple lesions were the major causes of reduced vision.

**Keywords:** *Toxoplasma*; Visual impairment; Ocular toxoplasmosis; Ghana

### Introduction

Ocular toxoplasmosis is caused by an intracellular protozoan parasite *Toxoplasma gondii*. It is responsible for up to 70% of all posterior uveitis cases in certain populations [1]. It is also a leading cause of visual impairment throughout the whole world, accounting for up to 57% of visual impairment and 24% of blindness in infected persons [2,3].

About a third of the world's population has been infected with *T. gondii* [4]. A fascinating observation, however, is the disparity in the occurrence of ocular toxoplasmosis in different populations with similar seroprevalence findings. In the United States, for example, where 15.8% of the general population was reported to have been infected with *Toxoplasma*, ocular involvement among the infected individuals was estimated at 2% [5,6]. In Brazil ocular toxoplasmosis is disproportionately high and seroprevalence findings are equally high. In the southern Brazilian city of Erechim, 85% of the population was

infected with *T. gondii* and 17.7% of the infected individuals had retinal lesions caused by the parasite [7]. A more recent study in the city of Campos dos Goytacazes, located in the north of Rio de Janeiro, found 31.8% prevalence of ocular infection in the population where 76.4% of the people were infected with the parasite [8]. In Colombia an estimated 5.5% of the entire population has *Toxoplasma* retinochoroidal scars and 47% of the population has been infected with the parasite [9]. Seroprevalence surveys in Ghana have reported *Toxoplasma* infection rates between 49.7% and 92% [10-12] while toxoplasmic retinochoroidal lesions occur in 3% of the population exposed to the parasite [13]. Higher and severe ocular disease outcomes have been attributed to infection with more virulent parasite strains and human genetic factors.

The most common complications and characteristics of ocular toxoplasmosis that lead to increased visual disability include macular scars, dragging of the macula secondary to peripheral lesions, strabismus, retinal detachment, nystagmus, optic atrophy, cataract, glaucoma, opacification of the media, amblyopia and bilateral involvement [14]. There are no prior reports that describe visual function in ocular toxoplasmosis in Ghana. The purpose of the current

study was to determine the visual outcome in patients with inactive ocular toxoplasmosis in a Ghanaian population.

## Materials and Methods

The study participants consisted of 20 consecutive patients with inactive ocular toxoplasmosis, who visited the University of Cape Coast Eye Unit plus 10 patients from an earlier population-based survey in the Central Region [13]. The study was conducted in accordance with the Helsinki Declaration on Research Regarding Human Subjects. The protocol for this study was reviewed and approved by the Ghana Health Service's Ethical Review Committee (ID: GHS-ERC: 21/11/12). Participants signed consent forms after the study protocol had been explained to them.

Ophthalmic examination was conducted by trained ophthalmologists and optometrists. The examination included distance Best Corrected Visual Acuity (BCVA) measurement, slit lamp biomicroscopy and dilated funduscopy by binocular indirect ophthalmoscopy. Fundus photographs were taken for cases of retinochoroiditis. Clinical diagnosis of ocular toxoplasmosis was based on characteristic ocular lesions consistent with *Toxoplasma* retinochoroiditis, in addition to a positive serologic result and in the absence of other identifiable ocular morbidities. The criterion for positive serologic result was a positive test for any of the two anti-*Toxoplasma* IgG or IgM antibodies or a combination of both. For purposes of consistency, description and measurement of toxoplasmic retinal lesions was made by one clinician.

Venous blood samples were collected by trained laboratory technologists. About 3 ml of venous blood was obtained from each participant, clear sera prepared and tested for the presence of anti-*Toxoplasma* antibodies IgG and IgM using commercial ELISA test kit (VEDALAB-France) and following the manufacturer's instructions. ELISA results were obtained using a micro-plate reader as a measure of optical densities of the reaction intensity of *T. gondii* antigen and serum anti-*T. gondii* antibodies at a filter wavelength of 450 nm. Cut-off points and antibody index calculations were done according to the manufacturers' recommendation to categorize samples as positives or negatives. Serology testing was performed at the time of inclusion to this study.

Patients who had other ocular morbidities such as macular degeneration, cataracts and glaucoma that could interfere with visual function were excluded. This was necessary in order that every visual disability would be attributed to the *Toxoplasma* lesions.

Patients' data such as age, gender, and chief complaints were recorded. Description of ocular lesions included size of lesion in disc diameters (DD), location of lesion, and number of lesions. Sizes of lesions were categorized as <2DD and  $\geq$  2DD; in multiple lesions the largest one was considered [15]. Lesions located within the major vascular arcades were classified as posterior pole lesions and those outside the major arcades as peripheral lesions. Posterior pole lesions were further classified as macular (involving the macula), juxtamacular (around the macular) and juxtapapillary (around the optic disc). In the case of multiple lesions priority was given to macular lesions. Lesions were also classified as single or multiple (2 or more lesions). Categories of visual impairment (VI) were determined based on the International Classification of Diseases criteria [16]. For

purposes of this study, visual impairment was determined after best refractive correction and for each infected eye separately.

Data was analyzed using the Statistical Package for Social Sciences (version 16; SPSS Inc., Chicago, IL). The Chi-square test was used to determine associations between categorical variables and where counts were below 5, the Fisher's Exact Test was used. The t-test was used to compare the mean ages of patients with different characteristics of *Toxoplasma* ocular lesions. Multivariate logistic regression analysis test (with 95% confidence intervals) was used to predict associations between dependent and independent variables. A p-value  $\leq$  0.05 was considered statistically significant.

## Results

A total of 30 cases with inactive *Toxoplasma* ocular scars were included for the current study. Their ages ranged from 16 to 59 years (mean age=34.2; SD= $\pm$  14.19), where 19 (63.3%) were males and 11 (36.7%) females. All the patients tested positive for IgG antibodies but none had IgM antibodies. Twenty three (77%) patients complained of blurred vision in the infected eyes, 14(47%) complained of seeing floaters, 5(17%) patients reported of mild pains while 3(10%) reported seeing halos around bright light. Three patients (10%) had complications of strabismus and two (6.7%) patients had developed cataracts in the infected eyes. Twelve (40%) patients had the lesions in their right eyes while in 15(50%) patients lesions occurred in the left eyes and 3(10%) patients had bilateral cases. Altogether, there were 33 infected eyes.

Visual Acuity	N (%)
6/6 or better	6 (18.2)
6/9-6/18	5 (15.2)
worse than 6/18-6/60	10 (30.3)
worse than 6/60-3/60	1 (3.0)
worse than 3/60	11 (33.3)
Total	33 (100.0)

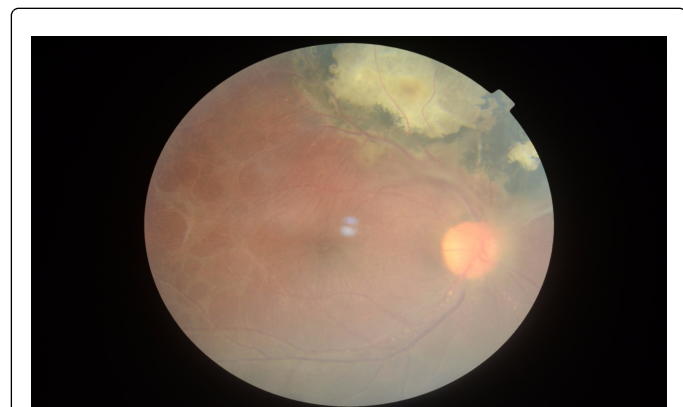
**Table 1:** Best corrected visual acuities of infected eyes.

Table 1 shows the BCVA of the infected eyes where 11(33%) eyes had visual impairment category 1 (no or mild visual impairment), 22(67%) eyes had low vision (VA<6/18), and 11 (33%) eyes being legally blind (VA<3/60). Majority of the infected eyes 18 (54.5%) had retinal scars/lesions of sizes less than 2DD while in 15 eyes the lesions were of sizes 2DD or bigger. However, the bigger retinal scars  $\geq$  2DD were more likely to cause low vision and blindness respectively [Low vision:<2DD, (41%);  $\geq$  2DD (59%, OR=6.50, p=0.04); Blindness: <2DD (27%);  $\geq$  2DD (73%, OR=5.7, p=0.03). Posterior pole retinal lesions occurred in 24 (72.7%) eyes and in 9 (27.3%) eyes the lesions were at the periphery. Lesions at the posterior pole were: macular 11, juxtamacular 6, and juxtapapillary 7. The cause in all eleven patients with legal blindness was attributed to posterior pole lesions: 10 macular cases and 1 juxtapapillary scar. No lesion outside the posterior pole contributed to any visual impairment.

Characteristic	Number of eyes (n=33)	Patients with low vision (n=22): VA<6/18			Patients with blindness (n=11): VA<3/60		
		N (%)	OR (CI)	p-value	n(%)	OR (CI)	p-value
<b>Size of lesion</b>							
<2 DD	18	9(50)	Reference	Reference	3(17)	Reference	Reference
≥ 2 DD	15	13(87)	6.5 (1.13-37.48)	0.04	8(53)	5.7 (1.15-28.35)	0.03
<b>Location of lesion</b>			$\chi^2$			$\chi^2$	
Posterior pole	24	22(92)	24.75	< 0.001	11(46)	6.2	0.02
Periphery	9	0 (0)			0 (0)		
<b>Number of lesions</b>			3.52	0.11		1.79	0.24
Single	23	13 (57)			6 (26)		
Multiple (2 or more)	10	9 (90)			5 (50)		

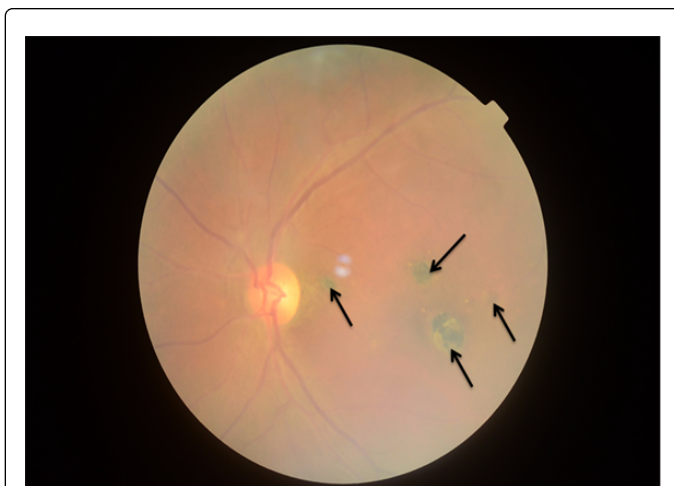**Table 2:** Relationship between characteristics of *Toxoplasma* retinochoroidal lesions and low vision/blindness in the infected eyes.

Low vision of VA worse than 6/18 occurred in 22 (66.7%) eyes, out of which 11 occurred at the macular, 5 juxtamacular and 6 juxtapapillary. Multiple (two or more) scars occurred in 10(30.3%) eyes; the other 23(69.7) eyes had single lesions. However, there was no association between cause of visual impairment and the number of lesions occurring in the infected eyes ( $\chi^2=3.52$ ,  $p=0.11$ ). Table 2 gives the relationship between characteristics of *Toxoplasma* ocular lesions and low vision/blindness in the infected eyes where bigger and posterior pole lesions were significantly associated with the causes of low vision and blindness in the infected eyes. Figures 1-3 represent fundus photographs of some of the patients.

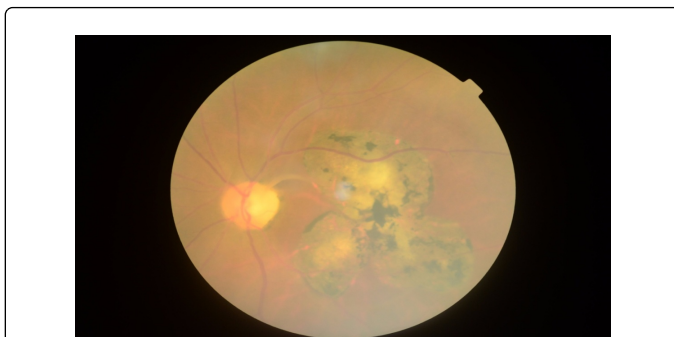


**Figure 1:** A large peripheral lesion of a 26 year old patient; Size of lesion>2DD; presence of vitreous strands; VA=6/12.

Elder patients had larger retinochoroidal lesions: mean age of patients ( $43.7 \pm 13$  years) with lesions  $\geq 2DD$  was significantly higher than the mean age of patients ( $27.1 \pm 10$  years) with smaller lesions  $<2DD$  [ $F=14.2$ ,  $p=0.001$ ]. Similarly, multiple lesions occurred significantly ( $F=13.4$ ,  $p=0.001$ ) in elder patients (mean age of  $47.4 \pm 11$  years) than in younger patients (mean age of  $29.4 \pm 12$  years).



**Figure 2:** Multiple posterior pole lesions of a 50 year old patient; Size of lesion<1DD; VA=6/36.



**Figure 3:** A large macular scar of a 59 year old patient; Size of lesion>2DD; VA=CF @2 m.

Again, elder patients had significantly more posterior pole lesions than younger patients ( $p=0.003$ ). However, there was no association between gender and location ( $\chi^2=0.6$ ,  $p=0.67$ ), size ( $\chi^2=2.9$ ,  $p=0.13$ ),

and number ( $\chi^2=0.8$ ,  $p=0.41$ ) of retinal lesions. Table 3 presents the relationship between characteristics of *Toxoplasma* retinochoroidal lesions and ages/gender of patients.

Description of lesion	Mean age (SD)	F-test	p-value	Gender		$\chi^2$	p-value
				Male	female		
Size of lesion		14.2	0.001			2.9	0.13
< 2DD	27.1 (± 10.4)			13 (76)	4 (24)		
≥ 2DD	43.5 (± 13.3)			6 (46)	7 (54)		
Location of lesion		10.5	0.003			0.6	0.67
Posterior pole	38.6 (± 14.1)			13 (59)	9 (41)		
Periphery	22.1 (± 3.8)			6 (75)	2 (25)		
Number of lesions		13.4	0.001			0.8	0.41
Single	29.4 (± 12.1)			15 (68)	7 (32)		
Multiple	47.4 (± 11.0)			4 (50)	4 (50)		

**Table 3:** Relationship between characteristics of *Toxoplasma* retinochoroidal lesions and ages/gender of patients.

## Discussion

This is a report of characteristic visual findings associated with *Toxoplasma* ocular infection from Ghana. Similar to the current finding, a study by Kadarisman et al. [2] in Indonesia found 56.7% of visual impairment and 20.1% of blindness in 41 eyes infected with toxoplasmosis. Another study from Indonesia found visual impairment and blindness to occur in 70 and 13.9% respectively in patients with ocular toxoplasmosis [14]. A study by Kodjikian et al. [17] reported a lower prevalence (23%) of visual impairment in 130 ocular toxoplasmosis cases. The devastating visual outcome in ocular toxoplasmosis is highly associated with the preponderance of posterior pole lesions. This was particularly the case in the current study where all the eyes with low vision 22 (67%) and blindness 11 (33%) had retinal lesions at the posterior pole. A study from Brazil found that the major cause of visual disability was papillomacular bundle area lesions, occurring in 76.3% [18]. Another study found the main (67.9%) contribution to vision loss in inactive lesions to be macular scars [19]. Tabatabaei et al. [15] reported that most of their ocular toxoplasmosis patients (87.5%) had lesions in the posterior pole. Several reasons have been argued for the preference of toxoplasmic ocular lesions at the macular area. It has been argued, for instance, that anatomic and microvascular differences between the macula and the peripheral retina might create a microenvironment that can influence the location of lesions [20]. Another major cause of visual impairment was larger lesion size ( $\geq 2DD$ ) which occurred in 45% of eyes and contributed to 87% of low vision. Tabalabei et al. [15] however, reported that only 5 (12.5%) of their patients had lesions larger than 2DD. The reason for this disparity may be related to the younger age of their patients (mean age of  $24.3 \pm 11.7$ ) as compared to mean age of  $34.2 \pm 14.19$  in the current study. They also found a relationship between the size of retinal lesion and age of patient, with older patients having larger lesions [15]. Dodds et al. [21] have also reported that signs of increased inflammation leading to marked reduction of visual acuity in patients with toxoplasmic retinochoroiditis were related to older patient age and larger retinal lesions. These observations may be

explained by the fact of a possible multiple recurrences of ocular toxoplasmosis that makes the scars larger in elder patients and also by reason of declining immunity with advancing age [20]. In the current study, not only were elder patients likely to have larger retinal scars but they were also likely to have multiple (2 or more) and posterior pole lesions (Table 3).

Unlike this study which found only three cases of strabismus and no nystagmus, other studies have found higher cases of strabismus and nystagmus in ocular *Toxoplasma* infection [14,17]. The development of strabismus and nystagmus seem to be associated with congenital cases as a result of disturbances of macular function during the developmental age. Strabismus develops as a result of poor central vision and extra foveal fixation due to macular lesions, and if fixation becomes continuously poor nystagmus becomes evident. Another feature of congenitally acquired infection which was absent from this study is the predominance of bilateral involvement. Kodjikian et al. [17] reported bilateral involvement of 96% in their congenital cases compared to 10% in the current study. Kadarisman et al. [2] found bilateral involvement in 50% of their cases where they reported complications of strabismus and nystagmus, both occurring in 50% of the episodes. For these reasons we may speculate that postnatally acquired infection is more common in this Ghanaian population.

In conclusion, we found higher episodes of low vision and blindness in our ocular toxoplasmosis patients. The major causes of visual impairment were posterior pole and larger retinal lesions and not multiplicity of the lesions. Posterior pole, multiple and larger retinal scars were significantly associated with older patient age.

## Acknowledgement

The study was sponsored by the University of Cape Coast.

## References

1. Ayanru JO (1977) The problem of uveitis in Bendel State of Nigeria: experience in Benin City. *Br J Ophthalmol* 61: 655-659.



2. Kadarisman RS, Marsetio M, Simangunsong LB (1991) Visual impairment and blindness in ocular toxoplasmosis cases. *Southeast Asian J Trop Med Public Health* 22 Suppl: 99-101.
3. Bosch-Driessen LE, Berendschot TT, Ongkosuwito JV, Rothova A (2002) Ocular toxoplasmosis: clinical features and prognosis of 154 patients. *Ophthalmology* 109: 869-878.
4. Commodaro AG, Belfort RN, Rizzo LV, Muccioli C, Silveira C, et al. (2009) Ocular toxoplasmosis: an update and review of the literature. *Mem Inst Oswaldo Cruz* 104: 345-350.
5. Holland GN (2003) Ocular toxoplasmosis: a global reassessment. Part I: epidemiology and course of disease. *Am J Ophthalmol* 136: 973-988.
6. Jones JL, Kruszon-Moran D, Wilson M (2003) *Toxoplasma gondii* infection in the United States, 1999-2000. *Emerg Infect Dis* 9: 1371-1374.
7. Glasner PD, Silveira C, Kruszon-Moran D, Martins MC, Burnier Júnior M, et al. (1992) An unusually high prevalence of ocular toxoplasmosis in southern Brazil. *Am J Ophthalmol* 114: 136-144.
8. Peixe RG, Boechat MS, Rangel AL, Rosa RF, Petzl-Erler ML, et al. (2014) Single nucleotide polymorphisms in the interferon gamma gene are associated with distinct types of retinochoroidal scar lesions presumably caused by *Toxoplasma gondii* infection. *Mem Inst Oswaldo Cruz* 109: 99-107.
9. de-la-Torre A, López-Castillo CA, Gómez-Marín JE (2009) Incidence and clinical characteristics in a Colombian cohort of ocular toxoplasmosis. *Eye (Lond)* 23: 1090-1093.
10. Ayeh-Kumi PF, Opoku AG, Kwakye-Nuako G, Dayie TKD, Asmah RO, et al. (2010) Sero-prevalence of toxoplasmosis among patients visiting the Korle-Bu teaching hospital, Accra, Ghana. *RIF* 1: 147-150.
11. Abu EK, Boampong JN, Ayi I, Ghartey-Kwansah G, Afoakwah R, et al. (2015) Infection risk factors associated with seropositivity for *Toxoplasma gondii* in a population-based study in the Central Region, Ghana. *Epidemiol Infect* 143: 1904-1912.
12. Ayi I, Edu SA, Apea-Kubi KA, Boamah D, Bosompem KM, et al. (2009) Sero-epidemiology of toxoplasmosis amongst pregnant women in the greater accra region of Ghana. *Ghana Med J* 43: 107-114.
13. Abu EK, Boampong JN, Amoabeng J, Ilechie A, Kyei S, et al. (2015) Epidemiology of Ocular Toxoplasmosis in three community surveys in the Central Region of Ghana, West Africa. *Ophthalmic Epidemiol*, Accepted for publication.
14. Suhardjo I, Utomo PT, Agni AN (2003) Clinical manifestations of ocular toxoplasmosis in Yogyakarta, Indonesia: a clinical review of 173 cases. *Southeast Asian J Trop Med Public Health* 34: 291-297.
15. Tabatabaei S, Soleimani M, Foroutan A, Ahmadabadi M, Zarei R, et al. (2011) Ocular toxoplasmosis in Iran: 40 cases analysis. *Int J Ophthalmol* 4: 199-201.
16. World Health Organization. International Statistical Classification of Diseases and Related Health Problems. 10th Revision, 2nd Ed. World Health Organization, Geneva, 2005.
17. Kodjikian LI, Wallon M, Fleury J, Denis P, Binquet C, et al. (2006) Ocular manifestations in congenital toxoplasmosis. *Graefes Arch Clin Exp Ophthalmol* 244: 14-21.
18. Melamed J, Eckert GU, Spadoni VS, Lago EG, Uberti F (2010) Ocular manifestations of congenital toxoplasmosis. *Eye (Lond)* 24: 528-534.
19. London NJ, Hovakimyan A, Cubillan LD, Siverio CD Jr, Cunningham ET Jr (2011) Prevalence, clinical characteristics, and causes of vision loss in patients with ocular toxoplasmosis. *Eur J Ophthalmol* 21: 811-819.
20. Holland GN (2004) Ocular toxoplasmosis: a global reassessment. Part II: disease manifestations and management. *Am J Ophthalmol* 137: 1-17.
21. Dodds EM, Holland GN, Stanford MR, Yu F, Siu WO, et al. (2008) Intraocular inflammation associated with ocular toxoplasmosis: relationships at initial examination. *Am J Ophthalmol* 146: 856-865.