

## Optic Nerve Aplasia and Microphthalmos: A Case Report

Gian Maria Cavallini<sup>1</sup>, Matteo Forlini<sup>1</sup>, Ana Laura Gramajo<sup>2</sup>, Alberto Brombin<sup>1</sup>, Giulio Torlai<sup>1</sup>, Elisa Volpini<sup>1</sup> and Cesare Forlini<sup>3\*</sup>

<sup>1</sup>Institute of Ophthalmology, University of Modena, Modena, Italy

<sup>2</sup>Centro Privado de Ojos Romagosa – Fundación VER, Córdoba, Argentina.

<sup>3</sup>Department of Ophthalmology, "Santa Maria Delle Croci" Hospital, Ravenna, Italy

### Abstract

Optic nerve aplasia is an extremely rare anomaly that is usually associated with microphthalmos as well as with other ocular and extraocular anomalies. In this case report we describe a case of an occasional finding of unilateral complete aplasia of the optic nerve in girl at the age of 42 days, in association only with microphthalmos.

**Keywords:** Optic nerve aplasia; Microphthalmos; Rare developmental anomaly; Congenital absence of the optic nerve; Malformation

### Introduction

Optic nerve aplasia (ONA) is a rare developmental anomaly characterized by the congenital absence of the optic nerve, central retinal vessels, retinal ganglion cells and optic nerve fibers. ONA is most often seen in a unilaterally malformed eye [1-3] and seems to fall within a malformation complex that is fundamentally distinct from optic nerve hypoplasia, although numerous case reports in the ophthalmic literature misidentify aplasia and described hypoplasia of the optic nerve instead [4]. There is no racial predisposition and males and females are similarly affected [5]. Unilateral ONA is generally associated with normal brain development without evidence of an inherited factor. Family history is not consistent with Mendelian inheritance, and results of chromosome exams are within normal parameters [6]. This is contrasting with bilateral optic nerve aplasia cases that are far more uncommon and are usually accompanied by other central nervous system (CNS) derangements and a possible familiar history [7].

To our knowledge, the largest series of optic nerve aplasia was published by Weiter et al., who described 11 unilateral cases of ONA and 2 atypical bilateral cases suspected to be an extreme form of hypoplasia of the optic nerve [8].

In most cases of unilateral ONA the patients display other spectrum of ocular abnormalities on the affected eye, with the most common being microphthalmos. Histopathologic studies of 25 eyes with ONA showed microphthalmia in 20 of 25 eyes [5]. Colobomas, and anterior or posterior staphylomas are additionally present in the majority of eyes. Other clinical features may be a vestigial dural sheath; retinal dysplasia and retinal rosettes; retinal detachment; primary hyperplastic persistent vitreous; choroidal, iris or ciliary body hypoplasia; microcornea, microphakia, cataract and hypoplasia of the corneal stroma [5,8]. Esotropia of the affected eye is also commonly found.

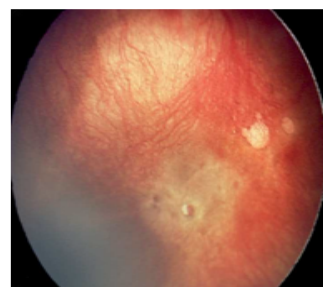
### Case Report

Our patient was a female infant, born from nonconsanguineous parents at 39 weeks of gestation with a birth weight of 3360 gr. Her parents' familial and ocular history was negative for malformations and genetic defects. The infant was the product of a full term pregnancy and elective caesarean section (due to a previous analogous caesarean section), the neonatal period was unremarkable.

The girl was referred to the ophthalmologist at the age of 42 days because her parents noted an unequal size of the eyes. The first

evidences that emerged at the ophthalmological examination were microphthalmos of the right eye (16.84 mm x 17.40 mm for the right eye (OD) and 17.82 mm x 18.45 mm on the left eye) and the absence of a right pupillary afferent reflex. At the biomicroscopy the cornea appeared clear, the anterior chamber was formed, the lens was transparent and no evidence of coloboma, cataract, sclerocornea, nystagmus or strabismus was detected. At the RetCam fundus examination the ophthalmologist noted a dysplastic retina, with a complete absence of retinal vessels, optic nerve and optic disc on the OD (Figure 1).

A Magnetic resonance imaging (MRI) examination was performed. Coronal T1-weighted images showed the absence of the right optic nerve in the orbit and in the optic foramen, whereas the optic nerve was normal at all levels on the OS. The optic chiasm appeared asymmetric due to chiasmatic hypoplasia on the right side. Coronal or axial T2-weighted images showed a decreased volume of the right optic globe and the absence of the right optic nerve whereas both optic tracts were present (Figure 2).



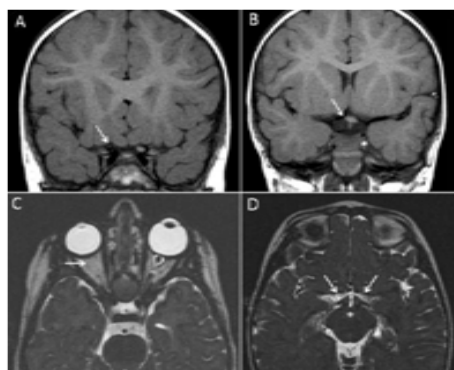
**Figure 1:** RetCam fundus examination of OD revealing a dysplastic retina with complete absence of retinal vessels, optic nerve and optic disc.

**\*Corresponding author:** Cesare Forlini, Chief of Department of Ophthalmology, "Santa Maria delle Croci" Hospital, Viale V. Randi n. 5, (48121) Ravenna, Italy, Tel: +39 0544 270385; Fax +39 0544 280049; E-mail: [forlinic@forlinic.it](mailto:forlinic@forlinic.it)

**Received** July 25, 2013; **Accepted** August 26, 2013; **Published** August 28, 2013

**Citation:** Cavallini GM, Forlini M, Gramajo AL, Brombin A, Torlai G, et al. (2013) Optic Nerve Aplasia and Microphthalmos: A Case Report. J Genet Syndr Gene Ther 4: 175. doi:[10.4172/2157-7412.1000175](http://dx.doi.org/10.4172/2157-7412.1000175)

**Copyright:** © 2013 Cavallini GM, et al. This is an open-access article distributed under the terms of the Creative Commons Attribution License, which permits unrestricted use, distribution, and reproduction in any medium, provided the original author and source are credited.



**Figure 2:** MRI examination showing the absence of the right optic nerve in the optic foramen (panel A) and chiasmatic hypoplasia on the right side (panel B). Axial T2-weighted images show decreased volume of the right optic globe and the absence of the right optic nerve in the orbit (panel C). Both optic tracts are present (panel D).

During the following weeks a sensory esotropia without any associated ocular torticollis emerged in the affected eye.

At 12 months a visually evoked cortical response was performed. Retino-cortical signalling and cortical response pattern appeared to be normal after OS visual stimulation; whereas OD stimulation evoked no cortical response. Bilateral and left-eye-only visually evoked cortical response seemed to be the same. These data and MRI images are available on line.

## Discussion

This case report summarizes the main features of the unilateral aplasia of the optic nerve in a non-syndromic infant, only associated with microphthalmos and with no evidence of any other malformation or dysmorphic feature.

ONA is an extremely rare, nonhereditary occurrence of unknown etiology that can occur as an isolated finding but is usually associated with other ocular abnormalities such as cyclopia, retinal dysplasia, cataracts, and sclerocornea. Coexisting microphthalmos and retinochoroidal coloboma have also been described.

The pathogenesis of ONA is controversial and remains speculative. Some authors affirm that this clinical feature may be related to a defective formation of the embryonal fissure, to a failure of the mesenchymal anlage of the hyaloid system to enter the embryonal fissure, or it may be related to a primary agenesis of the retinal ganglion cells [1,9]. Other hypothesis suggests that this feature can be a consequence of an abnormal invagination of the ventral fissure [8].

Environmental factors have been linked to ONA since some case reports mention exposure to a viral-like episode during the first trimester of pregnancy [6]. Acetone exposure or smoking during pregnancy has also been described [10]. Furthermore ONA can be produced in multiple animal species by exposing pregnant animals to different environmental factors [11,12].

Behrens-Baumann et al. in 1981 implied that the aplasia of the optic nerve in association with microphthalmos could have an autosomal-recessive mode of inheritance since they found oculocerebral dysplasia (aplasia of the optic nerve with familial microphthalmos and cryptophthalmos) in a brother and sister with healthy parents [13].

Pfeiffer et al. also described two unrelated cases of ONA in two

children with partial trisomy 10q24.1-ter. The authors suggested a common specific genetic effect due to the similar ophthalmological findings in these two patients [14].

In a recent publication it was reported an autosomal-dominant form of nonsyndromic ONA, where the authors suggested a role of CYP26A1 and CYP26C1 in the pathogenesis of nonsyndromic ONA [15].

The genetic source of optic nerve aplasia has been studied in mice. The recessive ocular retardation (*or*) mutation in the mouse has a complete penetrance in the homozygous state, and it has been linked to optic nerve aplasia, cataractous degeneration of the lens and microphthalmia [16]. In insects, it was suggested that a mutation or inactivation on the *eya* gene, presented in specie of fly (*Drosophila melanogaster*), could be a possible explanation for the development of ONA since this gene is required for normal eye development. Moreover, as stated by the authors, function of the *eya* gene appears to be restricted to the eye. The authors speculated that although the *eya* gene is not found in mammals, perhaps *eya* function is conserved and an *eya* mutation could be responsible for ONA [5].

Optic nerve aplasia has been previously linked with microphthalmos; however, this combination is usually reported to be in association with other ocular or systemic anomalies as contralateral microphthalmos [13] aniridia [6] or malformation of the anterior chamber and colobomas [8] among others. In addition, Margo et al reported bilateral optic tracts hypoplasia on a 3-year-old girl with monocular microphthalmos who had optic nerve aplasia as revealed by MRI [9].

To our knowledge this is the first report on optic nerve aplasia in association exclusively to microphthalmos. In our opinion it would be useful to implant an ocular prosthesis in these patients to grant a normal development of the orbit at least for aesthetic reasons.

## References

1. Sanjari MS, Ghasemi Falavarjani K, Parvaresh MM, Kharazi HH, Kashkooli MB (2006) Bilateral aplasia of the optic nerve, chiasm, and tracts in an otherwise healthy infant. Br J Ophthalmol 90: 513-514.
2. Brodsky MC (1998) Anomalies of the optic disc. In: Miller NR, Newman NJ, eds. Walsh and Hoyts clinical neuro-ophthalmology (5th edn), Baltimore: Williams and Wilkins 1: 799-800.
3. Brodsky MC (2005) Congenital optic disc anomalies. In: Taylor D, Hoyt G (Eds.), Pediatric ophthalmology and strabismus (3rd edn) Baltimore: Elsevier-Saunders 637-638.
4. Little LE, Whitmore PV, Wells TW Jr (1976) Aplasia of the optic nerve. J Pediatr Ophthalmol 13: 84-88.
5. Howard MA, Thompson JT, Howard RO (1993) Aplasia of the optic nerve. Trans Am Ophthalmol Soc 91: 267-276.
6. Ginsberg J, Bove KE, Cuesta MG (1980) Aplasia of the optic nerve with aniridia. Ann Ophthalmol 12: 433-439.
7. Brodsky MC, Atreides SP, Fowlkes JL, Sundin OH (2004) Optic nerve aplasia in an infant with congenital hypopituitarism and posterior pituitary ectopia. Arch Ophthalmol 122: 125-126.
8. Weiter JJ, McLean IW, Zimmerman LE (1977) Aplasia of the optic nerve and disk. Am J Ophthalmol 83: 569-576.
9. Margo CE, Hamed LM, Fang E, Dawson WW (1992) Optic nerve aplasia. Arch Ophthalmol 110: 1610-1613.
10. Barry DR (1985) Aplasia of the optic nerves. Int Ophthalmol 7: 235-242.
11. Shibuya K, Tajima M, Yamate J (1992) Unilateral optic nerve aplasia in an F344 rat with special reference to pathomorphological changes of the optic nerve pathways. J Vet Med Sci 54: 571-574.

12. Shibuya K, Tajima M, Yamate J, Kudow S (1989) Unilateral optic nerve aplasia in two young Slc:Wistar rats. *Vet Pathol* 26: 518-520.
13. Behrens-Baumann W, Dust G, Rittmeier K, Langenbeck U, Vogel M (1981) Oculo-cerebral dysplasia: aplasia of the optic nerve with familial microphthalmos and cryptophthalmos. Clinical and computer tomography study. *Klin Monbl Augenheilkd* 179: 90-93.
14. Pfeiffer RA, Jünemann A, Lorenz B, Sieber E (1995) Aplasia of the optic nerve in two cases of partial trisomy 10q24-ter. *Clin Genet* 48: 183-187.
15. Meire F, Delpierre I, Brachet C, Roulez F, Van Nechel C, et al. (2011) Nonsyndromic bilateral and unilateral optic nerve aplasia: first familial occurrence and potential implication of CYP26A1 and CYP26C1 genes. *Mol Vis* 17: 2072-2079.
16. Robb RM, Silver J, Sullivan RT (1978) Ocular retardation (or) in the mouse. *Invest Ophthalmol Vis Sci* 17: 468-473.

**Citation:** Cavallini GM, Forlini M, Gramajo AL, Brombin A, Torlai G, et al. (2013) Optic Nerve Aplasia and Microphthalmos: A Case Report. J Genet Syndr Gene Ther 4: 175. doi:[10.4172/2157-7412.1000175](https://doi.org/10.4172/2157-7412.1000175)

This article was originally published in a special issue, **Genetic Disorders** handled by Editor(s). Dr. Xiaobo Li, Yeshiva University, USA

### Submit your next manuscript and get advantages of OMICS Group submissions

#### Unique features:

- User friendly/feasible website-translation of your paper to 50 world's leading languages
- Audio Version of published paper
- Digital articles to share and explore

#### Special features:

- 250 Open Access Journals
- 20,000 editorial team
- 21 days rapid review process
- Quality and quick editorial, review and publication processing
- Indexing at PubMed (partial), Scopus, EBSCO, Index Copernicus and Google Scholar etc
- Sharing Option: Social Networking Enabled
- Authors, Reviewers and Editors rewarded with online Scientific Credits
- Better discount for your subsequent articles

Submit your manuscript at: <http://www.editorialmanager.com/omicsgroup/>

