

Optic Neuropathy Secondary to Multifocal Nerve Compression by Dolichoectatic Vasculature

Thomas S Bacon^{1*}, Tariq T Lamki², Mario Ammirati², David K Hirsh³ and Claudia F Kirsch⁴

¹Department of Medical Education, Mount Carmel Health System, Columbus, OH, USA

²Department of Neurosurgery, The Ohio State University Wexner Medical Center, Columbus, Ohio, USA

³Department of Ophthalmology, The Ohio State University Wexner Medical Center, Columbus, Ohio, USA

⁴Department of Radiology, The Ohio State University Wexner Medical Center, Columbus, Ohio, USA

Abstract

Progressive vision loss due to compression of the optic pathways by perichiasmal vasculature is uncommon. Several case reports describe unilateral vision loss due to compression of the optic nerve by the distal portions of the internal carotid artery, or less commonly the anterior cerebral artery. Bilateral vision loss is infrequently reported in the context of vascular compressive optic neuropathy and is either the result of independent compression of both optic nerves or rarely due to vascular compression at the optic chiasm. This paper presents a unique case of progressive bilateral vision loss due to multiple nerve lesions produced by compression of the optic pathways by dolichoectatic perichiasmal vasculature. In this case, both an enlarged right cavernous carotid artery and an ectatic segment of the left anterior cerebral artery compress the optic chiasm, in addition to compression of the left optic nerve by the supraclinoid portion of the left carotid artery.

Keywords: Compressive optic neuropathy; Dolichoectatic vasculature; Multifocal nerve compression; Progressive vision loss

Introduction

Compression of the anterior visual pathways by aberrant vasculature can result in progressive vision loss. Numerous cases cite optic nerve lesions due to aneurysmal compression, or less commonly impinging dolichoectatic vasculature [1-3]. Frequently implicated vessels include the cavernous carotid artery, or in a small subset of the affected population, the proximal A1 portion of the anterior cerebral artery (ACA) [1,2]. Single dolichoectatic vascular anomalies are reported in unilateral, and in rare cases, bilateral vision loss, resulting from compression at the optic nerve or chiasm respectively [4]. This report presents a novel case wherein progressive bilateral loss of vision resulted from three lesions surrounding the optic chiasm; each of which is the result of independent abnormal vasculature impinging on the optic pathways.

Case Report

A 47 year old male with calcified pleural plaques resulting in pulmonary disease and congestive heart failure presented with persistent painless loss of vision OD greater than OS over three months with subacute worsening over three weeks. Near visual acuity was J7 OD and J3 OS without afferent pupillary defect. Intraocular pressures were 16 OU and dilated fundoscopic exam revealed the macula, vessels, and peripheral retina to be within normal limits bilaterally. Cup to disc ratio was elevated at 0.75 OU with no neural rim thinning. Humphrey visual field (HVF) OS revealed mild general depression with moderate superior central scotoma, which split the horizontal midline (Figure 2A). OD was not assessed due to low visual acuity; count fingers at 3 feet. Subsequent follow up included an MRI of the brain and orbits, which revealed a tortuous A1 segment of the ACA abutting the optic chiasm superiorly on the left (Figure 1A), an enlarged cavernous carotid artery compressed the inferior portion of the optic chiasm on the right (Figure 1B), and compression of the left optic nerve by the left supraclinoid internal carotid artery (Figure 1C). Moreover, enhancement within the right optic chiasm was also noted on neuroimaging (Figure 1A).

Due to limited treatment options and chiasmal enhancement on

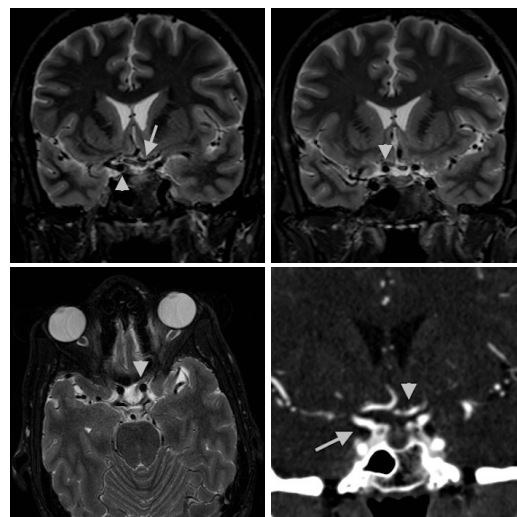


Figure 1: A. (Top Left) Coronal T2 MRI: Arrowhead showing right cavernous carotid displacing optic chiasm superiorly. Arrow highlighting left ACA displacing the left portion of the optic chiasm inferiorly. Also note focal hyperintensity in the right chiasm. B. (Top Right) Coronal T2 MRI: Arrowhead showing displacement of optic chiasm superiorly by supraclinoid cavernous carotid. C. (Bottom Left) Axial T2 MRI: Arrowhead showing medial displacement of left optic nerve. D. (Bottom Right) Coronal MRA: Arrowhead highlighting course of ACA. Arrow showing the internal carotid artery.

***Corresponding author:** Thomas S Bacon, Department of Medical Education, Mount Carmel Health System, Columbus, OH, USA, E-mail: thomas.scott.bacon@gmail.com

Received July 08, 2013; **Accepted** September 30, 2013; **Published** October 07, 2013

Citation: Bacon TS, Lamki TT, Ammirati M, Hirsh DK, Kirsch CF (2013) Optic Neuropathy Secondary to Multifocal Nerve Compression by Dolichoectatic Vasculature. J Clin Exp Ophthalmol 4: 297. doi: [10.4172/2155-9570.1000297](https://doi.org/10.4172/2155-9570.1000297)

Copyright: © 2013 Bacon TS, et al. This is an open-access article distributed under the terms of the Creative Commons Attribution License, which permits unrestricted use, distribution, and reproduction in any medium, provided the original author and source are credited.

MRI suggesting inflammation, the patient was treated with steroids while autoimmune etiologies were investigated. Steroids failed to improve the patient's vision loss, and the investigative panels were negative for autoimmune or infectious etiologies. Repeat HVF two weeks later showed slight worsening OS with a papillomacular defect superiorly and centrally in relation to the macula that again split the horizontal midline (Figure 2B). Neurosurgical evaluation included magnetic resonance angiography (MRA) and computed axial tomography with angiography (CTA) which confirmed chiasmal displacement by the tortuous A1 segment of the ACA on the left and further mass effect on the right by the supraclinoid internal carotid artery (Figure 1D).

Discussion

The pathophysiology of compressive optic neuropathy by aberrant vasculature is complex and not yet fully elucidated. It is hypothesized that age related vascular changes in anatomically predisposed individuals may result in compression related optic atrophy and subsequent vision loss [5]. Predisposed persons include those with normal anatomic variations in the perichiasmal vasculature resulting in a more immediate nerve vessel relationship [2]. Moreover, alterations in vessel wall thickness as the result of hypertension or atherosclerosis can contribute to the non-distensible nature of compressing vessels [4]. These arteries can impinge on the optic pathways and result in deleterious nerve compression [1,4].

The diagnosis of compressive optic neuropathy is complicated due to a lack of definitive testing. While physical compression of the optic pathway is necessary, it is not solely adequate to explain vision loss as compression is also observed in asymptomatic patients [2]. Furthermore, the implications of identifying such an anatomic arrangement are not well researched. Whether it represents a pre-symptomatic stage in a predisposed individual is unknown [2]. In the absence of unequivocal nerve compression, it is prudent to perform a thorough evaluation for alternative pathologic explanations.

An additional issue in correlating perichiasmal lesions with vision loss is the inconsistent ocular manifestations of nerve compression. While compression at the center of the chiasm classically produces bitemporal hemianopsia, the asymmetric nature of vascular impingement can cause various visual field defects [3]. The most common defects are a central scotoma or a superior defect as seen in the left eye of the patient in this case [2,3]. The more severe vision loss in the right eye of our patient is hypothesized to be a result of the chiasmal hyperintensity identified on MRI (Figure 1A). It is speculated

that compression of the optic chiasm and nerve compromised the vaso nervorum, lead to optic nerve ischemia and resultant edema as evidenced by the hyperintensity on the T2 weighted MRI sequences.

Therapeutic options are limited in compressive optic neuropathy and are dependent on either reversing the cause of vascular compression or altering the relationship of the vessel to the nerve. In the absence of medically reversible etiologies, neurosurgical intervention represents a theoretical therapeutic option. However, surgical exploration is controversial, as several case series have reported a decrease or plateau in the loss of vision over time [2,3]. Furthermore, due to the late age of onset most patients have medical comorbidities often precluding them from surgery. However, in the event of severe, disabling, and subacute vision loss, neurosurgical decompression represents a viable option. Procedures include unroofing the optic canal, or lysis of arachnoid adhesions and compressing ligaments, with ligation of the responsible vessel [2,3]. These procedures have variable efficacy, and ultimately a lack of randomized control trials fail to provide evidenced based guidelines on surgical management. Given the complexity of this patient's compression and their multiple comorbidities, they were offered surgical decompression. The risks of this procedure were presented to the patient, who at this time has elected not to undergo treatment.

In conclusion, this case report presents a unique case of progressive bilateral loss of vision in a patient with compression of the right optic chiasm by an enlarged cavernous carotid artery inferiorly, compression of the left optic chiasm by an ectatic A1 segment of the ACA superiorly, and compression of the left optic nerve by the left supraclinoid internal carotid artery. The dedicated MRI imaging of the orbits revealing increased T2 signal within the nerves may have resulted from the aforementioned compression. The pathophysiology, diagnosis, and treatment of compressive optic neuropathy by aberrant vasculature remains complex, although improved techniques via Three Tesla MRI imaging and CT angiography may lead to an improved diagnosis and understanding of this unique cause of vision loss.

References

1. Mitts M, McQueen D (1965) Visual Loss Associated with Fusiform Enlargement of the Intracranial Portion of the Internal Carotid Artery. J Neurosurg 23: 33-37.
2. Jacobson DM (1999) Symptomatic compression of the optic nerve by the carotid artery: clinical profile of 18 patients with 24 affected eyes identified by magnetic resonance imaging. Ophthalmology 106: 1994-2004.
3. Purvin V, Kawasaki A, Zeldes S (2004) Dolichoectatic arterial compression of the anterior visual pathways: neuro-ophthalmic features and clinical course. J Neurol Neurosurg Psychiatry 75: 27-32.
4. Hilton G, Hoyt W (1966) An Atherosclerotic Chiasmal Syndrome: Bitemporal Hemianopia Associated With Fusiform Dilatation of the Anterior Cerebral Arteries. JAMA 196: 1018-1020.
5. Chen C, Gailloud P, Miller N (2008) Bitemporal Hemianopia Caused by an Intracranial Vascular Loop. Arch Ophthalmol 126: 274-276.

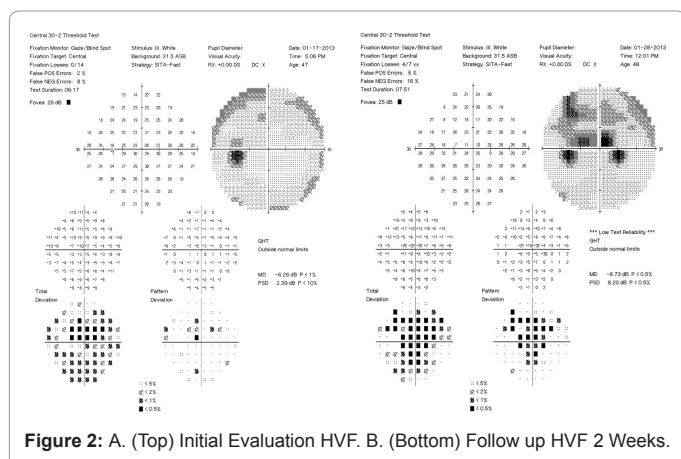


Figure 2: A. (Top) Initial Evaluation HVF. B. (Bottom) Follow up HVF 2 Weeks.

Citation: Bacon TS, Lamki TT, Ammirati M, Hirsh DK, Kirsch CF (2013) Optic Neuropathy Secondary to Multifocal Nerve Compression by Dolichoectatic Vasculature. J Clin Exp Ophthalmol 4: 297. doi: 10.4172/2155-9570.1000297