

# Ossified Metaplastic Meningioma with Intratumoral Hemorrhage

Hui-Chun Tai<sup>1</sup>, Chih-Jung Chen<sup>1</sup>, Chien-Min Chen<sup>2</sup>, Wei-Liang Chen<sup>3</sup> and Pi-Yu Chen<sup>1</sup>

<sup>1</sup>Department of Surgical Pathology, Changhua Christian Hospital, Changhua, Taiwan

<sup>2</sup>Department of Neurosurgery, Changhua Christian Hospital, Changhua, Taiwan

<sup>3</sup>Department of Radiology, Changhua Christian Hospital, Changhua, Taiwan

## Abstract

**Background:** Metaplastic meningioma is a rare subtype of WHO grade I meningioma. Among the diverse types of mesenchymal differentiation seen in this tumor, the presence of extensive "ossified change" or "ossification" is rare. Most cases of osseous meningioma in the literature occurred in spinal level and intracranial location is relatively rare. The pathogenesis is postulated to be associated with increased level of intratumoral alkaline phosphatase.

**Case presentation:** We reported a case of intracranial ossified meningioma with extensive ossification and intratumoral hemorrhage. The patient was a 60-year-old male with clinical presentation of left-side limb weakness. Radiologic features revealed extensive intratumoral calcification. Surgical treatment resulted in complete resection without any complications. Upon histological examination, the meningioma was found to be comprised of meningothelial-like and spindle cells admixed with extensive mature lamellar bone tissue. In addition, multifocal hemorrhage and areas of infarct were also found. Immunohistochemical studies revealed that the immunophenotype of tumor cells was identical to that of meningothelial type meningioma. The tumor also contained a rich intratumoral vascular network highlighted by CD34 stain.

**Conclusion:** Here we report a rare presentation of intratumoral hemorrhage in an intracranial ossified meningioma. Intratumoral hemorrhage is hardly seen in this kind of meningioma in the literature. In addition, the rarity of extensively ossification in this intracranial tumor may make it hard to distinguish from extensive hyperostosis of skull bone, intraosseous meningioma, and periosteal osteoblastoma clinically. Although, the true mechanism of ossification is still not clear, be aware of this rare entity is important for clinical practice.

**Keywords:** Metaplastic meningioma; Ossified meningioma; Intratumoral hemorrhage

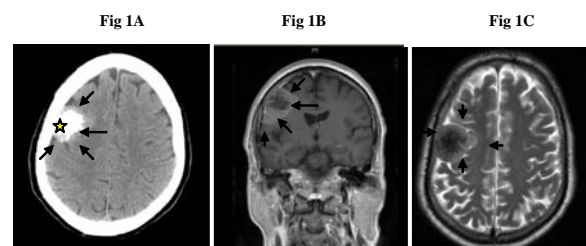
## Introduction

Metaplastic meningioma is a rare subtype of meningioma. By definition, the mesenchymal differentiation includes osseous, cartilaginous, lipomatous, myxoid or xanthomatous changes [1,2]. Nonetheless, this kind of tumor is benign and is classified as WHO grade I [1,2]. However, the morphologic changes in reported osseous meningioma vary from extensive distribution of psammomatous bodies within the tumor to the presence of mature bony trabeculae. The latter has to be distinguished from associated hyperostosis of adjacent skull, intraosseous meningioma, and periosteal osteoblastoma [3]. Intratumoral hemorrhage of meningioma is another phenomenon rarely observed. We report a case of ossified meningioma with the presence of both rare features.

## Case Report

A 60-year-old man suffering from headache for 3 days and progressive weakness of left-sided limbs was admitted to our Neurosurgery Department. Neurologic examination showed decreased muscle power at left limbs. CT examination revealed a 3.1 cm heavily calcified lesion on right posterior frontal lobe (Figure 1A). MRI imaging revealed a right temporal extra-axial mass with increased signal on T<sub>1</sub> and decreased T<sub>2</sub>-weighted sequences, suggestive of a heavily calcified tumor (Figure 1B and 1C). The overlying calvarium showed hyperostosis. The association of the extra-axial mass with dural and osseous reaction as well as calcified fatty components led us to the clinical suspicion of an ossified meningioma or other brain tumors with calcifying elements. It also revealed some intratumoral and peripheral vasculature devoid of flow. A right fronto-temporal craniotomy was performed. The tumor showed adhesion to the

overlying skull. The tumor and its dural insertion were completely removed. The postoperative course was uneventful, and there was no neurologic sequel.



**Figure 1:** **A)** The CT scan reveals the presence of a 3.1 cm subcortical tumor (indicated by arrow) located in the posterior frontal lobe of the right side. There is heavy calcification within the tumor (indicated by star). **B)** The extra-axial well-defined lobulated tumor with mixed hypo- and isosignal intensity occupies the right temporal region. Increased signal density is in the periphery of the tumor (T<sub>1</sub>-weighted MRI). **C)** Decreased signal density in the central portion of tumor in the T<sub>2</sub>-weighted MRI.

**\*Corresponding author:** Dr. Pi-Yu Chen, Department of Surgical Pathology, Changhua Christian Hospital, 135 Nan-Hsiao St., Changhua, 500, Taiwan, Tel: 886-4-7238595 Ext: 4834; Fax: 886-4-7238595-3500#; E-mail: [135549@cch.org.tw](mailto:135549@cch.org.tw)

**Accepted** October 18, 2010; **Accepted** October 18, 2010; **Published** October 18, 2010

**Citation:** Tai HC, Chen CJ, Chen CM, Chen WL, Chen PY (2010) Ossified Metaplastic Meningioma with Intratumoral Hemorrhage. J Cytol Histol 1:102. doi:10.4172/2157-7099.1000102

**Copyright:** © 2010 Tai HC, et al. This is an open-access article distributed under the terms of the Creative Commons Attribution License, which permits unrestricted use, distribution, and reproduction in any medium, provided the original author and source are credited.



## Pathological findings

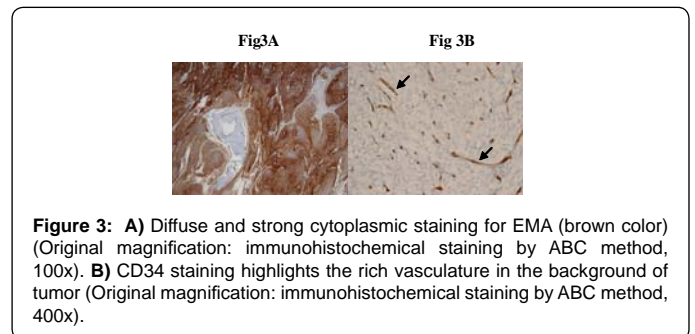
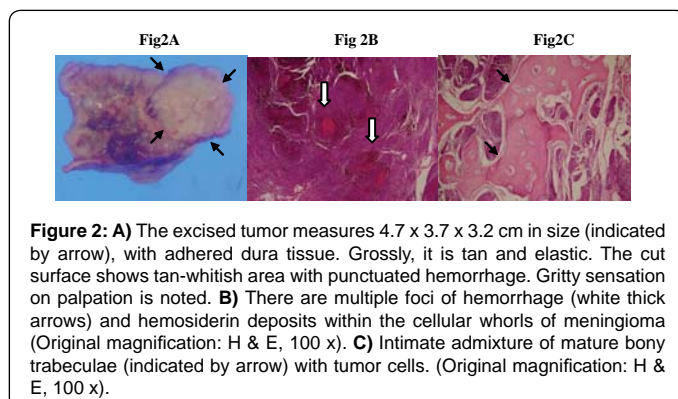
Gross inspection of the removed tissue revealed a tumor measuring 4.7 x 3.7 x 2.0 cm in size, with attached dura measuring 3.5 x 3.3 cm in dimensions. We observed a hemorrhagic area surrounded by hard bony tissue in the central portion of this tan and elastic tumor (Figure 2A). The tumor was composed of polygonal cells growing in a whorled pattern, suggestive of meningothelial-like cells. In some areas, there was a transition of the growth pattern showing fibroblast-like spindle cells in vague fascicular arrangement. Foci of erythrocyte extravasation and abundant deposition of hemosiderin granules, suggestive of previous intratumoral bleeding, were present within the tumor cells (Figure 2B). An area of infarct was also seen. Large lamellated trabeculae of mature bone were seen within the tumor extensively. We also observed osteoblastic rimming (Figure 2C). The tumor cells were positive for immunostains of EMA (Figure 3A) and vimentin. The rich vascular background was also identified by the CD34 staining (Figure 3B), but there was no endothelial proliferation or angiomatous vascularization present. The MIB-1 proliferative index was less than 5%.

## Discussion

The first case of ossified meningioma in human occurred in the spinal cord and was reported by Roger in 1928 [4]. A review of the literature revealed that less than 25 cases of ossified meningioma had been reported from 1977 to 2005 [5]. The vast majority of these tumors are spinal location sometimes, extensive ossification in this intracranial tumor could mimic extensive hyperostosis, intraosseous meningioma, and periosteal osteoblastoma clinically [6]. Only 5 cases of intracranial meningioma were present in the literatures (see Table 1) and of only one demonstrated true bony trabeculae formation histologically. All the other case reports described tumors rich in psammoma bodies or calcification or located intraosseously.

The mechanism of ossification in meningioma is unclear. Typically, the arachnoid membrane contains frequent regions of microscopic calcification. It has been suggested that calcified meningiomas are, in fact, precursor lesions to ossified meningioma [7]. W. J. Pepler demonstrated a strong enzyme reaction of alkaline phosphatase in all cells comprising a meningothelial meningioma and the cells around the psammoma bodies in the psammomatous type [7].

Most meningiomas are benign and slow-growing tumors. Hemorrhage is a very rare presentation of meningiomas and the hemorrhagic patterns can be classified into three types: subarachnoid hemorrhage, intracranial hemorrhage/intratumoral and subdural hemorrhage [8]. The bleeding propensity of intracranial hemorrhage is highest when it is found in association with the meningothelial



Site	Age(years)/sex	Clinical presentation	Case number	Reference
F-S	unknown	Extensive hyperostosis extending from the anterior clinoid process to the cerebral convexity and falx cerebri	1	11
O	68/F	Complete blindness on the 2nd post-op day of colon surgery	1	12
F	64/F	Initial a protrusion of her forehead with subsequent loss of vision in 23 years	1	13
P	60/M	Three months history of left focal seizures	1	14
F	unknown	Extraosseous localization of bone-seeking radiopharmaceuticals	1	15

Abbreviation: F- frontal, S-sphenoidal, P- parietal, O-occipital

**Table1:** The list of reported ossified meningiomas in the cranium.

type [8]. However, Helle and Conley suggested that angioblastic meningiomas had bleeding tendency more than twice as frequently as all other types of meningiomas [9]. While clinically significant hemorrhage is associated with loss of consciousness, the surgery-related mortality rate in unsuspected meningioma with hemorrhage is similar to the cases without bleeding [10]. We do not know whether ossified meningiomas have bleeding tendency due to rare reported cases in the literatures. In addition, the image signal of hemorrhagic foci sometimes could be masked by the osseous background so that makes it hard to detect the intratumoral hemorrhage clinically. In our case, rich vascularity within the tumor is found and may explain its bleeding propensity. However, the true mechanism of hemorrhage in this osseous tumor is still unknown.

In summary, we report a rare case of ossified meningioma occurring in a 60-year-old man with unusual clinical manifestations. Extensive osseous change and multifocal intratumoral hemorrhage were distinct. The mechanism of ossification of meningioma is still unclear. The clinical doctors should take this rare tumor into the differential diagnosis when encountering the intracranial osseous tumors. In addition, pay attention to progressive neurologic changes which may imply the underlying tumor bleeding.

## References

- Louis DN, Scheithauer BW, Budka H (2000) Meningiomas In Paul Kleihues and Webster K Cavenee. World Health Organization Classification of Tumours, Pathology and Genetics of Tumours of the Nervous System. Lyon: IARCPress 176-184.
- Perry A, Louis DN, Scheithauer BW (2007) Meningiomas. In: David N Louis, Hiroko Ohgaki, Otmar D. Wiestler, et al. World Health Organization Classification of Tumors of the Central Nervous System. Lyon: IARCPress 164-172.
- Lin YC, Commins DL, Fedenko AN, Gregory PS (2005) A Rare Case of Periosteal Osteoblastoma Located in the Frontal Cranial Bone. Arch Pathol Lab Med 129: 787-789.



4. Rogers L (1928) A spinal meningioma containing bone. *Br J Surg* 15: 675-677.
5. Liu CL, Lai PL, Jung SM, Liao CC (2006) Thoracic ossified meningioma and osteoporotic burst fracture: treatment with combined vertebroplasty and laminectomy without instrumentation: case report. *J Neurosurg Spine* 4: 256-259.
6. Kato K, Chernov M, Urino T, Kasuya H, Kubo O, et al. (2008) Ossified frontosphenoorbital meningioma en plaque, mimicking extensive hyperostosis. *Minim Invasive Neurosurg* 51: 237-239.
7. Kaufman AB, Dunsmore RH (1971) Clinicopathological considerations in spinal meningeal calcification and ossification. *Neurology* 21: 1243-1248.
8. Pepler WJ (1960) Alkaline phosphatase in the meninges and meningiomas. *Nature* 186: 979.
9. Bošnjak R, Derham C, Popovic M, Ravnik J (2005) Spontaneous intracranial meningioma bleeding: clinicopathological features and outcome. *J Neurosurg* 103: 473-484.
10. Helle TL, Conley FK (1980) Hemorrhage associated with meningioma: a case report and review of the literature. *J Neurol Neurosurg Psychiatry* 43: 725-729.
11. MacCarty CS, Taylor WF (1979) Intracranial meningiomas: experience at the Mayo Clinic. *Neurol Med Chir* 19: 569-574.
12. Naderi S, Yilmaz M, Canda T, Acar U (2001) Ossified thoracic spinal meningioma in childhood - A case report and review of the literature. *Clin Neurol Neurosurg* 103: 247-249.
13. Castellano-Sanchez AA, Alexis JB, Poppiti RJ Jr, Nanes M, Villalobos EE (2001) Pathologic quiz case: an unexpected occipital tumor. *Arch Pathol Lab Med* 125: 301-303.
14. Colón GP, Ross DA, Hoff JT (1998) Sequential outer table craniotomy a in hyperossified meningioma. Technical note. *J Neurosurg* 88: 346-348.
15. Mathuriya SN, Vasishta RK, Khandelwal N, Pathak A, Sharma BS, et al. (2000) Calcified falx meningioma. *Neurol India* 48: 285-287.
16. Shih WJ, Wang AM, Domstad PA, Cho SR, DeLand FH (1985) Intracranial meningioma with abnormal localization of bone-seeking radiopharmaceutical: correlation with gross and microscopic pathology. *Eur J Nucl Med* 11: 43-45.

