

Osteosarcoma of Mandible: A Case Report and Review of Literature

Manisha M Khorate^{1*}, S. Goel², M. P. Singh³ and J. Ahmed⁴

¹Senior Lecturer, Department of Oral Medicine & Radiology, Pacific Dental College & Hospital, Udaipur, Rajasthan

²Post-Graduate Student, Department of Oral Medicine & Radiology, Pacific Dental College & Hospital, Udaipur, Rajasthan

³Associate Professor, Department Of Oral Medicine & Radiology, Pacific Dental College & Hospital, Udaipur, Rajasthan

⁴Professor & Head Of The Department, Department Of Oral Medicine & Radiology, Pacific Dental College & Hospital, Udaipur, Rajasthan

Abstract

Osteosarcoma is a bone tumor and can occur in any bone, usually in the extremities of long bones near metaphyseal growth plates. The most common sites are the femur (42%), tibia (19%), and humerus (10%). Other significant locations are the skull and jaw (8%), pelvis (8%), other bones (13%). Osteosarcoma of the jaw differs from osteosarcoma of the long bones in its biological behavior even though they have the same histologic appearance. Its radiographic appearance varies, though the presence of radial spicules and Codman's triangle are highly suggestive of Osteosarcoma. Early diagnosis and radical surgery are the keys to high survival rates. This article presents a case of osteosarcoma of mandible in a 20 year old male patient.

Keywords: Osteosarcoma; Sunray appearance; Codman's triangle; Radical surgery

Introduction

Osteosarcoma is the most common malignant bone tumor (Vander Griend, 1996; Marulanda et al., 2008). The term "sarcoma" was introduced by the English surgeon John Abernathy in 1804 and was derived from Greek roots meaning "fleshy excrescence" (Peltier, 1993). In 1805, the French surgeon Alexis Boyer first used the term "Osteosarcoma" (Peltier, 1993; Rutkow, 1993). Intraoral sarcoma is a very rare disease and may constitute approximately 1% of all head and neck cancers and only 0.14% of intraoral malignancies (Gorsky and Epstein, 1998). The most common clinical presentation of osteosarcoma is pain in the involved region of bone, with or without a soft tissue mass. The lesions are slightly more common in men (Tanazawa et al., 1991; Vege et al., 1991; Bennett et al., 2000).

Case Report

A 20 year old male patient reported to the Department of Oral Medicine and Radiology, Pacific Dental College and Hospital, Udaipur, with a chief complaint of swelling in left side of the lower jaw since past one month. The patient gave history of similar swelling 2 months back which subsided on its own. A small swelling developed in the left lower side of the mouth about one month back which was painless and had been growing gradually, since then to the present size. According to the patient, presently it is evident extra-orally since 15-20 days. Patient also expressed difficulty in chewing food on the affected side.

Extra-oral examination revealed a diffuse swelling on the left side of the mandible, extending antero-posteriorly from the left parasymphysis region to the angle of the mandible on the left side and superio-inferiorly extending from a line, drawn from the left angle of the mouth to the tragus of the left ear, to the inferior border of the mandible (Figure 1a), roughly measuring around 5cms X 4cms in size. The overlying skin appeared to be slightly tensed. On palpation, the swelling was firm to hard, non-tender, with a slightly raised temperature. Left and right submandibular lymph nodes were palpable, soft to firm, mobile and non tender. Intraoral examination revealed a well defined swelling along the mandibular arch, extending from the premolar to the retromolar region on left side causing obliteration of the buccal vestibule (Figure 1b). The overlying mucosa

was reddish pink in color. On palpation, buccal and lingual cortical plate expansion was evident which was hard in consistency. Patient had restricted mouth opening. Tooth numbers 36, 37, 38 were tender on percussion and 38 exhibited grade II mobility with pericoronitis.

The radiographic evaluation included the intraoral periapical radiograph (IOPA), and panoramic radiograph. The IOPA revealed a widening of the periodontal ligament space (WPLS) with an irregular absence or attenuation of the lamina dura i.r.t. 36, 37, 38. Panoramic radiograph revealed an ill defined, mixed radiolucent-radiopaque lesion along the left body of mandible, denoting irregular areas of osteolysis. The mandibular cross-sectional radiograph showed the

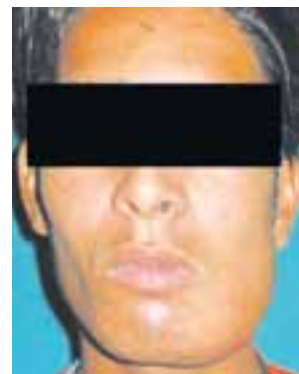

Figure 1a: Extraoral photograph: A diffuse swelling over left body and ramus of the mandible.

***Corresponding author:** Manisha M. Khorate (M.D.S.), Senior Lecturer, Oral Medicine, Diagnosis, & Radiology Department, Pacific Dental College and Hospital, Airport Road, Debari, Udaipur, Rajasthan, India, Tel: 0091-294- 2494501 to 02 (Ext-237, 239); Fax: 0091-294-2491508; E-mail: khoratemanisha@rediffmail.com

Received May 25, 2010; **Accepted** July 05, 2010; **Published** July 05, 2010

Citation: Khorate MM, Goel S, Singh MP, Ahmed J (2010) Osteosarcoma of Mandible: A Case Report and Review of Literature. J Cancer Sci Ther 2: 122-125. doi:10.4172/1948-5956.1000036

Copyright: © 2010 Khorate MM, et al. This is an open-access article distributed under the terms of the Creative Commons Attribution License, which permits unrestricted use, distribution, and reproduction in any medium, provided the original author and source are credited.

presence of radial spicules spreading outside the jaw bone on left side, giving a “sunray appearance” (Figure 2a).

Based upon the clinical and radiological findings, a provisional diagnosis of malignancy of left body of mandible was given. The differential diagnosis included central vascular lesion (hemangioma), cellulitis involving left buccal, vestibular and submandibular space. The non-contrast multislice spiral CT scan of the mandible and face revealed expansile destructive complex mass lesion involving the body and ramus of left side of mandible with hypodense to cystic component surrounding it (Figures 2b). Incisional biopsy revealed proliferation of spindle shaped anaplastic fibroblasts and osteoblasts

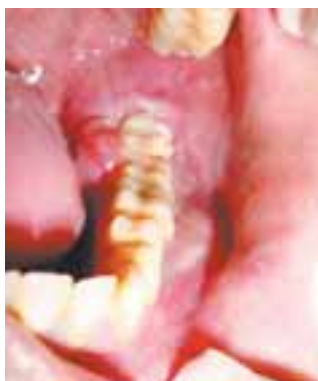

Figure 1b: Intraoral photograph: A swelling causing obliteration of the buccal vestibule.

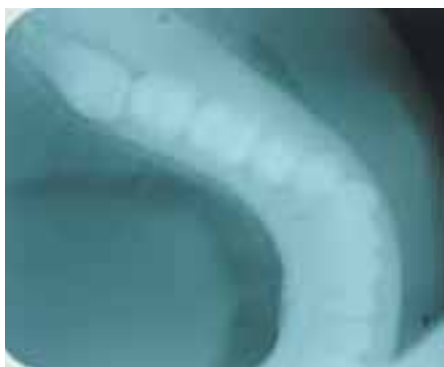

Figure 2a: The mandibular occlusal radiograph: Radial spicules spreading outside the jaw bone on left side, giving a “sunburst appearance”.

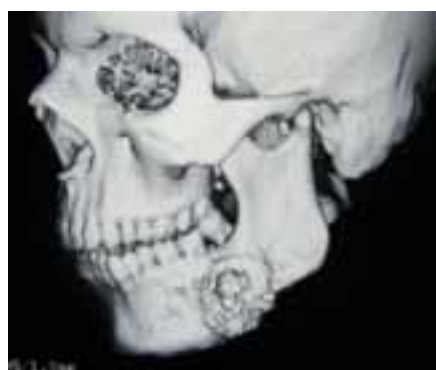

Figure 2b: 3D construction CT image: Lateral aspect of the lesion.

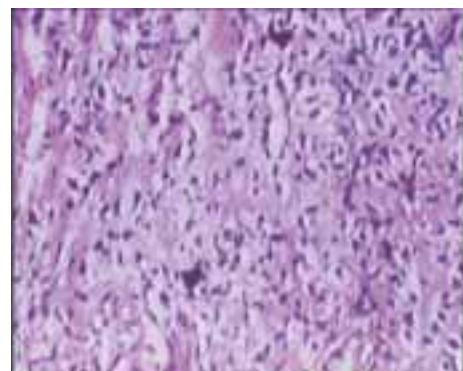


Figure 3: Histopathological examination: Spindle shaped anaplastic fibroblasts and neoplastic Osteoblasts.

with irregularly shaped hyperchromatic nuclei (Figure 3). The findings were suggestive of osteosarcoma (fibroblastic type). The patient was referred to Oncology centre, and the treatment regimen prescribed was radical surgical resection along with a margin of normal surrounding tissue, and chemotherapy. The five year survival rate was predicted to be 65.3% (Bielack et al., 2002).

Discussion

Osteosarcoma is a highly malignant tumor with extensively destructive potential. It is also the most common primary malignant lesion of bone. It is a true cancerous degeneration of bone, which manifests itself in the form of a white or reddish mass, lardaceous and firm at an early stage of the disease; but at a later period, presenting with points of softening, cerebriiform matter, extravasating blood, and white or straw colored fluid of a viscid consistence in its interior (Peltier, 1993).

The exact cause of osteosarcoma is unknown. However, a number of risk factors are apparent, as follows (Hudson et al., 1990):

- Rapid bone growth: Increased incidence during the adolescent growth spurt.
- Environmental factors such as radiation. Radiation-induced osteosarcoma is a form of secondary osteosarcoma.
- Genetic predisposition: Bone dysplasias, including Paget disease, fibrous dysplasia, enchondromatosis, and hereditary multiple exostoses and retinoblastoma (germ-line form) are risk factors.

Males are affected more frequently in most series (male: female ratio; 1.4:1), though the rate for girls up to about age 13 years are roughly 30% higher than those for boys. In the 15 to 24 year old age group, the male rate exceeds the female rate by some 140%. They occur with almost equal frequency in both the jaws (Clark et al., 1983; Tanazawa et al., 1991). The most common places of occurrence are the alveolar ridge and the body of maxilla and mandible (Clark et al., 1983; Slootweg and Muller, 1985; Forteza et al., 1986; Tanazawa et al., 1991; Bertoni et al., 1991; Bennett et al., 2000). The median age of maxillary osteosarcoma is reported to be higher than the mandibular one.

Radiography is the initial imaging modality in the evaluation of bone tumors (Massengill et al., 1995). The diagnosis of osteosarcoma is typically suspected by the radiographic appearance of the affected bone. Ossification in the soft tissue component of the bone, manifesting as “sunburst” pattern is classic for osteosarcoma but

is not a sensitive or specific feature. Periosteal new formation with lifting of the cortex leads to the appearance of a Codman's triangle. Garrington et al. (1967) mentioned that roentgenographic evidence of a symmetrically widened periodontal membrane space is a significant early finding in Osteosarcoma of jaw, although the same features have been seen in some chondrosarcomas (Garrington et al., 1967).

The extent of the tumor in both bone and soft tissue is best appreciated with cross sectional imaging techniques such as computerized tomography (CT) or magnetic resonance imaging (MRI). This is particularly important prior to definitive surgery. Although MRI is generally accepted to be superior to CT scanning in the evaluation of local tumor spread, Panicek and colleagues have shown that CT scanning and MRI are equally accurate in the staging of local disease in bone tumors (Panicek et al., 1997). However, in the present case, MRI could not be done due to financial limitations, as the patient belonged to a lower socioeconomic group.

Clark et al. (1983) who classified the radiographic pattern of osteosarcoma of the jaw into lytic, sclerotic, and mixed, mentioned that no relationship was found between the radiographic pattern and the histological type of osteosarcoma (Clark et al., 1983). In the present case, it was observed that the lesion was mixed (radiolucent-radiopaque) in appearance, in accordance with Clark et al. (1983) classification. The diagnosis of osteosarcoma must be verified histologically with a biopsy before initiation of treatment. Osteosarcoma is thought to arise from primitive mesenchymal bone-forming cells, and its histological hallmark is the production of malignant osteoid. Other cell populations may also be present, as these types of cells may also arise from pluripotential mesenchymal cells, but any area of malignant bone in the lesion establishes the diagnosis as osteosarcoma. The World Health Organization's histological classification of bone tumors separates the osteosarcomas into central (medullary) and surface (peripheral) tumors and recognizes a number of subtypes within each group (Table 1). The most common pathologic subtype is conventional high-grade central osteosarcoma (Schajowicz, 1993). It accounts for 80-90% of all osteosarcomas and is characterized by areas of necrosis, atypical mitoses and malignant cartilage. Its most frequent subtypes are osteoblastic, chondroblastic and fibroblastic osteosarcomas. Unni and Dahlin (1984) described that osteosarcomas of jaw are usually histologically grade II or III, and they are associated with a better prognosis than conventional osteosarcoma (Unni and Dahlin, 1984).

The Enneking system for the surgical staging of bone tumors is based on grade (G), site (T), and metastasis (M) and uses histologic, radiologic, and clinical criteria. It is the most widely used staging system and has been adopted by the Musculoskeletal Tumor Society (Enneking et al., 1980; Musculoskeletal Tumor Society and Enneking, 1985; Enneking, 1986).

CENTRAL (MEDULLARY)
a. Conventional high-grade central osteosarcoma b. Telangiectatic osteosarcoma c. Intraosseous well-differentiated (low-grade) osteosarcoma d. Small cell osteosarcoma
SURFACE (PERIPHERAL)
a. Parosteal (juxtacortical) well-differentiated (low-grade) osteosarcoma b. Periosteal osteosarcoma - low- to intermediate-grade osteosarcoma c. High-grade surface osteosarcoma

Table 1: Osteosarcoma subtypes within central and surface tumors (The World Health Organization's histologic classification of osteosarcoma).

Before the use of chemotherapy (which began in the 1970s), osteosarcoma was treated primarily with surgical resection along with a margin of normal surrounding tissue (Forteza et al., 1986). Bielack et al. (2002) in their analysis of prognostic factors in high-grade osteosarcoma of the extremities of trunk, concluded that incomplete surgery was the most important negative prognostic indicator, followed by poor response, primary metastases and axial location (Bielack et al., 2002), as well as tumor size in those patients where it could be evaluated (Bieling et al., 1996; Bielack et al., 2002). Anatomical limitations in face can sometimes cause difficulties in achievement of uninvolved margins and for this reason local recurrence of these lesions is high (Forteza et al., 1986; Bertoni et al., 1991). Mandibular osteosarcomas have a better prognosis than maxillary osteosarcomas (Garrington et al., 1967).

Conclusion

Pain in the involved region of bone is a unique clinical presentation of osteosarcoma, which is unusual of other tumors and thus osteosarcoma can be confused with other inflammatory lesions. Radiographic evaluation often plays an important role in the initial diagnosis of osteosarcoma. In addition, CT scans are excellent for demonstrating the degree of intramedullary extension, cortical involvement and soft tissue involvement. Thus, the treatment and prognosis for osteosarcoma depend to a large extent on early diagnosis and radical surgery.

References

- Bennett JH, Thomas G, Evans AW, Speight PM (2000) Osteosarcoma of the jaw: A 30 years retrospective review. *Oral Surg Oral Med Oral Pathol Oral Radiol Endod* 90: 323-333.
- Bertoni F, Dallera P, Bacchini P, Marchetti C, Campobassi A (1991) The institute Rizzoli-Beretta experience with osteosarcoma of the jaw. *Cancer* 68: 1555-1563.
- Bielack SS, Kempf-Bielack B, Delling G, Exner GU, Flege S, et al. (2002) Prognostic factors in high-grade osteosarcoma of the extremities of trunk: an analysis of 1,702 patients treated on neoadjuvant cooperative osteosarcoma study group protocols. *J Clin Oncol* 20: 776-790.
- Bieling P, Rehan N, Winkler P, Helmke K, Maas R, et al. (1996) Tumour size and prognosis in aggressively treated osteosarcoma. *J Clin Oncol* 14: 848-858.
- Clark JL, Unni KK, Dahlin DC, Devine KD (1983) Osteosarcoma of the jaw. *Cancer* 51: 2311-2316.
- Enneking WF (1986) A system of staging musculoskeletal neoplasms. *Clin Orthop Relat Res* 204: 9-24.
- Enneking WF, Spanier SS, Goodman MA (1980) A system for the surgical staging of musculoskeletal sarcoma. *Clin Orthop Relat Res* 153: 106-120.
- Forteza G, Colmenero B, Lopez-Barea F (1986) Osteogenic sarcoma of the maxilla and mandible. *Oral Surg Oral Med Oral Pathol* 62: 179-184.
- Garrington GE, Scofield HH, Cornyn J, Hooker SP (1967) Osteosarcoma of the jaws. Analysis of 56 cases. *Cancer* 20: 377-391.
- Gorsky M, Epstein JB (1998) Head and neck and intra-oral soft tissue sarcomas. *Oral Oncol* 34: 292-296.
- Hudson M, Jaffe MR, Jaffe N, Ayala A, Raymond AK, et al. (1990) Pediatric osteosarcoma: therapeutic strategies, results, and prognostic factors derived from a 10-year experience. *J Clin Oncol* 8: 1988-1997.
- Marulanda GA, Henderson ER, Johnson DA, Letson GD, Cheong D (2008) Orthopedic surgery options for the treatment of primary osteosarcoma. *Cancer Control* 15: 13-20.
- Massengill AD, Seeger LL, Eckardt JJ (1995) The role of plain radiography, computed tomography, and magnetic resonance imaging in sarcoma evaluation. *Hematol Oncol Clin North Am* 9: 571-604.
- Musculoskeletal Tumor Society, Enneking WF (1985) Staging of musculoskeletal neoplasms. *Skeletal Radiol* 13: 183-194.

15. Panicek DM, Gatsonis C, Rosenthal DI, Seeger LL, Huvos AG, et al. (1997) CT and MR imaging in the local staging of primary malignant musculoskeletal neoplasms: report of the Radiology Diagnostic Oncology Group. *Radiology* 202: 237-246.
16. Peltier LF (1993) Tumors of bone and soft tissues. *Orthopedics: A History and Iconography*, Norman Publishing, San Francisco, California 264-291.
17. Rutkow IM (1993) The nineteenth century. *Surgery: An Illustrated History*, St Louis, Mo: Mosby-Year Book, 321-504.
18. Schajowicz F (1993) Histological typing of bone tumours (2nd edn). Berlin: Springer-Verlag.
19. Slootweg PJ, Muller M (1985) Osteosarcoma of the jaw bones. Analysis of 18 cases. *J Maxillofac Surg* 13: 158-166.
20. Tanazawa H, Uchiyama S, Sato K (1991) Statistical observation of osteosarcoma of the maxillofacial region in Japan. Analysis of 114 Japanese cases reported between 1930 and 1989. *Oral Surg Oral Med Oral Pathol* 72: 444-448.
21. Unni KK, Dahlin DC (1984) Grading of bone tumors. *Semin Diagn Pathol* 1: 165-172.
22. Vander Griend RA (1996) Osteosarcoma and its variants. *Orthop Clin North Am* 27: 575-581.
23. Vege DS, Borges AM, Aggrawal K, Balasubramaniam G, Parikh DM et al. (1991) Osteosarcoma of the craniofacial bones. A clinico-pathological study. *J Craniomaxillofac Surg* 19: 90-93.

