

Patellar Tendon Rupture: Case Report of a Rare Complication of Total Knee Replacement

Sahibzada Nasir Mansoor^{1*}, Farooq A Rathore² and Ahmad Zaheer Qureshi³

¹Department of Rehabilitation Medicine, Combined Military Hospital, Kohat, KPK, Pakistan

²Department of Rehabilitation Medicine, Combined Military Hospital, Lahore Cantt, Punjab, Pakistan

³Department of Physical Medicine and Rehabilitation, King Fahad Medical City, Riyadh Saudi Arabia

Abstract

Total Knee Replacement (TKR) is the procedure of choice for patients with advanced knee osteoarthritis when non surgical treatment options fail. Complications of TKR include infection, deep vein thrombosis and joint loosening. A rare but debilitating complication is patellar tendon rupture, which may be due to inherent weakness of the tendon and/or damage to the tendon during surgery or trauma.

We report a case of patellar tendon rupture after TKR in a 75 years old female. On post operative day 22, she had rupture of patellar tendon while trying to get up from a low lying commode. Site of rupture was confirmed by MRI and musculoskeletal ultrasound. Patellar tendon repair surgery was done using semitendinosis graft followed by knee immobilization for six weeks. Rehabilitation was continued for twelve weeks. Patient was able to walk with cane and was independent in activities of daily living.

Care should be taken before, during and after surgery. Low lying commode chairs and commode can lead to rupture of an already compromised tendon. Clinical examination and radiographs can confirm the diagnosis. Surgical repair is the only option for treatment. Prognosis is usually not good.

Keywords: Patellar tendon; Total knee replacement; Osteoarthritis; Complication; Rehabilitation

Introduction

Total knee replacement (TKR) is the procedure of choice for advanced knee osteoarthritis with unremitting knee pain. In Pakistan total knee replacement surgery has developed in the last decade and more surgeons are now performing the surgery. The complications of the surgery include infection, deep vein thrombosis, joint loosening and patellar tendon rupture. Patellar tendon rupture is a rare but devastating complication of total knee replacement. It can be due to improper surgical technique resulting in compromised blood supply to the tendon during surgery, micro trauma during surgery, increased stretch for good exposure, damage to the pad of fat, poor joint alignment or loose patellar component of the prosthesis [1].

It may be due to inherent weakness of the tendon or damage to the tendon during or after surgery. Sudden jerky movements of the knee especially in the squatting position can cause tremendous load on quadriceps leading to rupture of the patellar tendon. The management of patellar tendon rupture is difficult and the prognosis is not good. The reported incidence of patellar ligament rupture is 0.22-0.55% [2].

We report a case of patellar tendon rupture as a complication of total knee replacement in a 75 years old lady.

Case Presentation

A Seventy five years old female underwent left TKR for grade IV osteoarthritis. She had successful right TKR four years before this surgery. There was normal range of movement of left knee before surgery however her recent TKR surgery involved patellar resurfacing along with polypropylene patellar component. Surgery was uneventful with good post-operative recovery. She had normal patellar position on post operative Xrays. Post TKR rehabilitation protocols were initiated and she was able to achieve limited indoor ambulation within three days. She continued with range of motion and strengthening exercises with proprioceptive training. Surgical drains were removed on the fourth post-operative day and she was discharged on 14th post-operative

day after removal of stitches. By this time her ROM was more than 90 and muscle strength in Quadriceps was 4/5. On 22nd post op day, while getting up from a low lying commode chair, she experienced twisting and excruciating pain in her left knee and was unable to stand. She could not extend her knee which was swollen. She asked for assistance from family member for mobility. Later on she was unable to walk without support due to severe pain and the knee giving way on weight bearing. She used neoprene sleeve over the affected knee along with walker for limited indoor mobility. She sought medical advice after one week when the pain and swelling did not improve. There was no past history of trauma, steroid injections or oral use of steroids. Upon examination the left knee joint was warm, tender and swollen. Swelling and skin discoloration were suggestive of hematoma formation. She was unable to actively extend her knee joint and the range of motion was painful. The patella was mobile and high riding (Figure 1). X-ray left knee joint revealed a patella Alta (Figure 2) while rest of the joint was normal. MRI of the knee showed a ruptured patellar tendon although failed to locate the exact site of rupture due to artifacts from the underlying metallic prosthesis. Musculoskeletal ultrasound revealed the extent of ruptured patellar tendon involving most of its midsubstance length. Patellar tendon repair was done, augmentation was done using semitendinosis graft and knee was immobilized in a cast for 6 weeks with subsequent mobilization and rehabilitation. Within two weeks of mobilization, patient was able to achieve more than 90 degree knee flexion, grade IV MRC power in quadriceps and extensor mechanism and there was no extensor lag. At twelve weeks of followupatient was able to walk

***Corresponding author:** Sahibzada Nasir Mansoor, Department of rehabilitation medicine, Combined Military Hospital Kohat, KPK, Pakistan, Tel: 00923329448818; E-mail: drnasirmansoor@gmail.com

Received March 05, 2013; **Accepted** April 20, 2013; **Published** April 23, 2013

Citation: Mansoor SN, Rathore FA, Qureshi AZ (2013) Patellar Tendon Rupture: Case Report of a Rare Complication of Total Knee Replacement. Int J Phys Med Rehabil 1: 125. doi:10.4172/2329-9096.1000125

Copyright: © 2013 Mansoor SN, et al. This is an open-access article distributed under the terms of the Creative Commons Attribution License, which permits unrestricted use, distribution, and reproduction in any medium, provided the original author and source are credited.

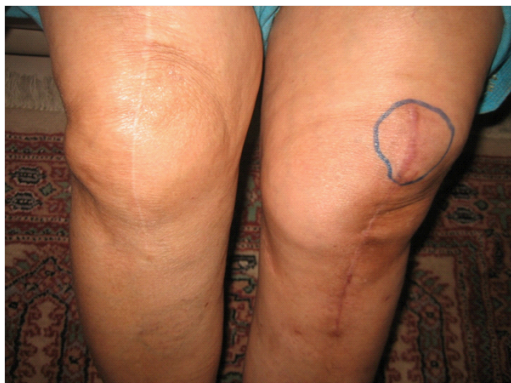

Figure 1: Patella has been displaced upward and associated with swelling and painful restriction of movements.

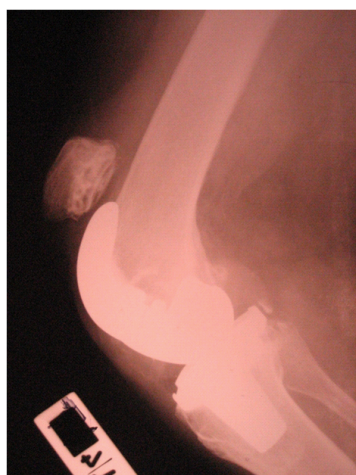


Figure 2: Lateral Radiograph of the Knee showing high riding patella.

independently with a walking cane. Patient was pain free and achieved full range of motion of affected joint.

Discussion

Extensor mechanism disruption from quadriceps tendon rupture, patellar fracture, or patellar tendon rupture is an uncommon complication of TKR. Patellar tendon rupture is the most common among the extensor mechanism disruption. It can cause significant functional limitations for a successful joint replacement.

The possible cause of patellar tendon rupture in our case could be attributed to the inherent weakness of the tendon due to old age and advanced osteoarthritis, associated micro trauma and increased stretch during surgery. Finally the sudden jerky movement to get up from a low lying commode chair leading to violent contraction of quadriceps might have been the main reason for the subsequent rupture. Repair with semitendinosus graft was chosen due to the level and extent of tendon rupture along with surgeon's preference and expertise in the procedure. In old patients with already weak and compromised musculoskeletal system, great care should be taken in the immediate post operative period to avoid extreme stress on the tendon and joints, aggressive physiotherapy should be avoided and post operative mobility protocols should be tailored to the age and fitness level of the patient to prevent tendon rupture.

Treatment outcomes for ruptured patellar ligaments are not good. Primary repair is successful in the early cases but in late and complicated cases grafting is required. Semitendinosus and Achilles tendon allograft are commonly used. For partial tears cast immobilization and the use of brace is treatment of choice. Reconstruction options include direct surgical repair, local autologous graft, distant autologous graft, synthetic graft, or various types of allograft [3]. The management depends upon the level of the rupture. Patellar pole rupture and mid substance tears are treated with simple tension band suturing and immobilization while tibial tuberosity avulsions are pinned with screw. Calcaneal and Achilles tendon grafts are used in some cases [4].

Cadambi and Engh [4] reported in their cases series that six out of seven ruptures occurred intra operatively or immediately afterwards. While Gustillo and Thompson found patellar tendon ruptures to occur later [5,6].

Cadambi and Engh [4] used the semitendinosus tendon. In two of their seven patients, the repair was augmented by using the gracilis tendon and passing it through the patella drill hole. Knee range of motion was restored in all patients.

Extensor mechanism allograft was used by Emerson in a series of 15 patients with a rupture of the patella tendon in association with a total knee arthroplasty [7]. The allograft consisted of the tibial tubercle, patellar tendon, patella, and quadriceps tendon that were freeze dried or fresh frozen. The graft was secured to the tibia with distally and quadriceps tendon proximally.

Zanotti et al. [7] have reported successful treatment of a patellar tendon-deficient knee in a single patient with the use of a bone-patellar tendon-bone allograft. They used an irradiated, freeze-dried patellar-patellar tendon-proximal tibial allograft from a fresh cadaver. The repair was protected postoperatively in a cast for 3 months, and progressed to ambulation with a Knee Ankle Foot Orthosis. They reported the graft to be healed with full active extension at 2-year follow-up.

An alternative surgical technique of reconstruction of the patellar tendon using a semitendinosus gracilis (STG) graft with an interference screw and a staple fixation enabling an immediate mobilization was described by Jarvela in a case report [8].

Recently use of synthetic mesh to reconstruct a disrupted patellar tendon after TKR was successfully reported. Patients had significant improvement in the mean Knee Society scores for pain and function and the synthetic mesh was significantly less expensive than the allograft [9].

Conclusion

Patellar tendon rupture is a catastrophe and has a complicated course. Prevention is more important than treatment. Gentle manipulation of the soft tissue during surgery, correct alignment of the components and vigilant post op care should be practiced. Low lying commode or chairs should be avoided after TKR surgery as they add tremendous amount of stress to the already compromised joint.

References

1. Rand JA, Morrey BF, Bryan RS (1989) Patellar tendon rupture after total knee arthroplasty. Clin Orthop Relat Res : 233-238.
2. Hsu RW (2006) The management of the patella in total knee arthroplasty. Chang Gung Med J 29: 448-457.
3. Crossett LS, Sinha RK, Sechriest VF, Rubash HE (2002) Reconstruction of a ruptured patellar tendon with achilles tendon allograft following total knee arthroplasty. J Bone Joint Surg Am 84-84A: 1354-61.

4. Cadambi A, Engh GA (1992) Use of a semitendinosus tendon autogenous graft for rupture of the patellar ligament after total knee arthroplasty. A report of seven cases. *J Bone Joint Surg Am* 74: 974-979.
5. Gustillo RB, Thompson R (1987) Quadriceps and patellar tendon ruptures following total knee arthroplasty. *Total Arthroplasty of the Knee*. Rockville, Maryland 41-47.
6. Emerson RH Jr, Head WC, Malinin TI (1990) Reconstruction of patellar tendon rupture after total knee arthroplasty with an extensor mechanism allograft. *Clin Orthop Relat Res* : 154-161.
7. Zanotti RM, Freiberg AA, Matthews LS (1995) Use of patellar allograft to reconstruct a patellar tendon-deficient knee after total joint arthroplasty. *J Arthroplasty* 10: 271-274.
8. Järvelä T, Halonen P, Järvelä K, Moilanen T (2005) Reconstruction of ruptured patellar tendon after total knee arthroplasty: a case report and a description of an alternative fixation method. *Knee* 12: 139-143.
9. Browne JA, Hanssen AD (2011) Reconstruction of patellar tendon disruption after total knee arthroplasty: results of a new technique utilizing synthetic mesh. *J Bone Joint Surg Am* 93: 1137-1143.

Citation: Mansoor SN, Rathore FA, Qureshi AZ (2013) Patellar Tendon Rupture: Case Report of a Rare Complication of Total Knee Replacement. Int J Phys Med Rehabil 1: 125. doi:[10.4172/2329-9096.1000125](https://doi.org/10.4172/2329-9096.1000125)