

## Is Extra-uterine Migrated IUCD Always Innocent?

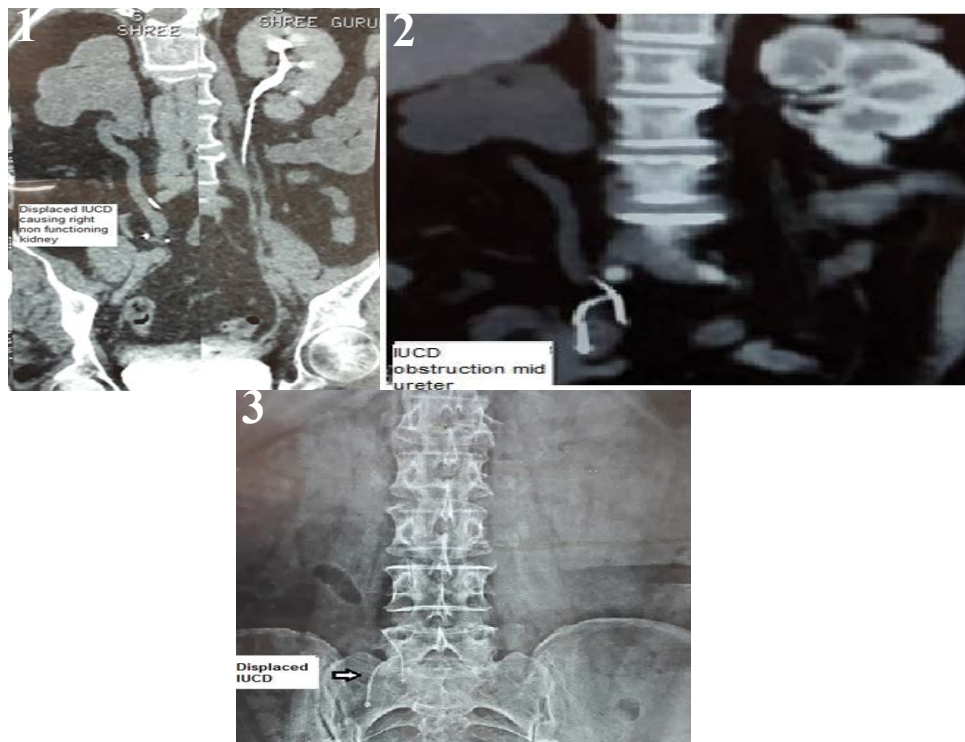
Parmar K<sup>1</sup>, Manoharan V<sup>2</sup>, Chandna A<sup>2</sup> and Mavuduru R<sup>2</sup>

<sup>1</sup>Department of Urology, Post Graduate Institute of Medical Education and Research, Chandigarh, India

<sup>2</sup>Post Graduate Institute of Medical Education and Research, Chandigarh, India

### Introduction

A 50-years-old hypertensive post-menopausal female presented with right flank pain. Her past history was insignificant. Ultrasound abdomen showed right gross hydronephrosis. X-ray kidney, ureter and bladder revealed a T-shaped radio density overlying the upper border of sacrum at L5-S1 level. Detailed record revealed that she had history of 'lost' intrauterine contraceptive device (IUCD) 30 years back after 2 years of its insertion. Routine CBC, biochemistry and renal function were normal (Figure 1). Contrast CT revealed surprising finding of right non-excretory kidney with gross hydroureteronephrosis and IUCD which was not present in the uterus but migrated outside and lying at level of upper sacrum along the course of right ureter (Figures 2 and 3). Extra-uterine migration of IUCD is very well-known adverse event. However, a migrated IUCD causing ureteric obstruction is an extremely rare and disastrous event.



**Figure 1:** Showing displaced IUCD causing right non functioning kidney.

**Figure 2:** Showing IUCD obstruction mid ureter.

**Figure 3:** Showing displaced IUCD.

\*Corresponding author: Kalpesh Parmar, Department of Urology, Post Graduate Institute of Medical Education and Research, Chandigarh, India, Tel: +919915105062, E-mail: [kalpesh010385@gmail.com](mailto:kalpesh010385@gmail.com)

Received January 10, 2019; Accepted February 12, 2019; Published February 19, 2019

Citation: Parmar K, Manoharan V, Chandna A, Mavuduru R (2019) Is Extra-uterine Migrated IUCD Always Innocent?. OMICS J Radiol 8: 305. doi: [10.4172/2167-7964.1000305](https://doi.org/10.4172/2167-7964.1000305)

Copyright: © 2019 Parmar K, et al. This is an open-access article distributed under the terms of the Creative Commons Attribution License, which permits unrestricted use, distribution, and reproduction in any medium, provided the original author and source are credited.