

## Squamous Cell Carcinoma in Mature Cystic Teratoma Ovary: A Rare Presentation

Aruna Gupta and Garima Shah\*

Department of Health and Family Welfare, Dr Rajendra Prasad Government Medical College, Kangra, Himachal Pradesh, India

\*Corresponding author: Garima Shah, Department of Health and Family Welfare, Dr Rajendra Prasad Government Medical College, Kangra, Himachal Pradesh, India, Tel: (+91)9805101402; E-mail: [docshahgarima@gmail.com](mailto:docshahgarima@gmail.com)

Received date: August 02, 2019; Accepted date: August 19, 2019; Published date: August 26, 2019

Copyright: © 2019 Gupta A, et al. This is an open-access article distributed under the terms of the Creative Commons Attribution License, which permits unrestricted use, distribution, and reproduction in any medium, provided the original author and source are credited.

### Abstract

**Introduction:** Mature cystic teratoma also known as dermoid cyst is the most common ovarian tumors accounting for 30%-45% cases.

1. The incidence of Squamous cell carcinoma arising in the mature cystic teratoma is 2%.
2. In this case report we are presenting two cases of squamous cell carcinoma arising in mature cystic teratoma.

**Case presentation:** Two women of age 62 and 47 years are presented to the gynecology OPD with the complaints of distension and pain in the lower abdomen. On CECT-Features suggestive of mature cystic teratoma was given as the diagnosis. TAH with BSO was done. On histopathologic examination, diagnosis of squamous cell carcinoma arising in the background of mature cystic teratoma was given.

**Discussion:** Mature cystic teratoma is a common ovarian tumor in young women while squamous cell carcinoma in the setting of mature cystic teratoma is extremely rare. Carcinoma arising in the mature teratoma is common among postmenopausal women. It has poor prognosis but preoperative diagnosis of this malignant transformation of mature cystic teratoma is difficult.

**Conclusion:** Although mature cystic teratoma is common but its malignant transformation is extremely rare. It carries poor prognosis and has to be diagnosed early. Its preoperative diagnosis is difficult and can be confirmed on histopathology only. The clinicians, pathologists and radiologist should be well aware of this entity and should take it into consideration.

**Keywords:** Squamous cell carcinoma; Mature cystic teratoma; Postmenopausal women

### Case Presentation

#### First case

A postmenopausal woman of age 47 years was presented to gynecological OPD with the complaints of pain lower abdomen for past 1 month. On clinical examination adnexal mass was felt on left side. Routine and specific examinations were carried out. On CECT, a cystic mass of size (13.8 × 11 × 9.8) cm suggestive of mature cystic teratoma was given as the diagnosis. TAH with BSO was done. Intraoperative findings showed left ovarian cyst with smooth external surface. The capsule was intact and no adhesions were present. Cut section showed-multiloculated cyst containing sebaceous material, hair and solid and papillary areas and diagnosis of Malignant ovarian tumor was suggested. Other structures were grossly unremarkable. The histopathologic examination confirmed the malignant nature of the cyst and diagnosis of squamous cell carcinoma arising in setting of mature cystic teratoma was given as shown in Figure 1.

#### Second case

A woman of age 62 years was presented with the complaints of distension of abdomen from past 4-5 weeks. A mass of 24 weeks was felt. Routine and specific examinations were carried out. PAP smears

showed inflammatory atrophic smear. On USG, diagnosis was solid cystic mass Dermoid Malignant tumor of size (17 × 16 × 12) cm was given with the advice of MRI for further characterization. TAH with BSO was done. The intraoperative findings showed left ovarian cyst with dense adhesion on posterior aspect and omentum. Cut section showed cyst containing sebaceous material and hair. The histopathologic examination of the sample was carried out and diagnosis of squamous cell carcinoma arising in the mature cystic teratoma was given as shown in Figures 2 and 3.

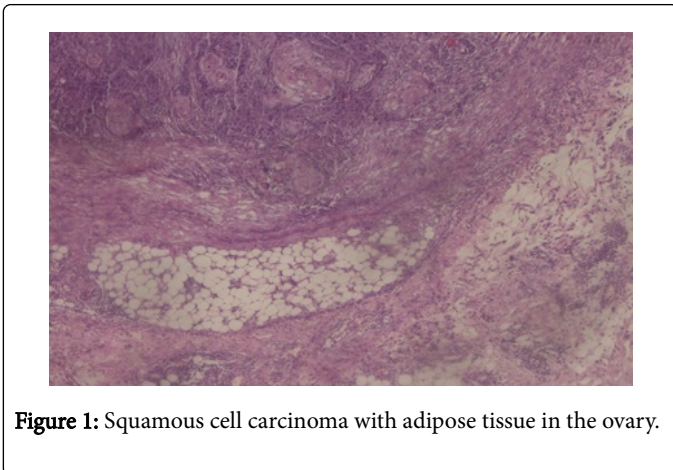


Figure 1: Squamous cell carcinoma with adipose tissue in the ovary.

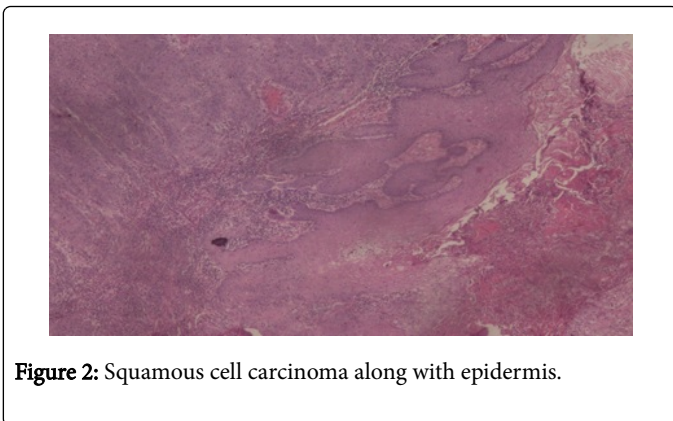


Figure 2: Squamous cell carcinoma along with epidermis.

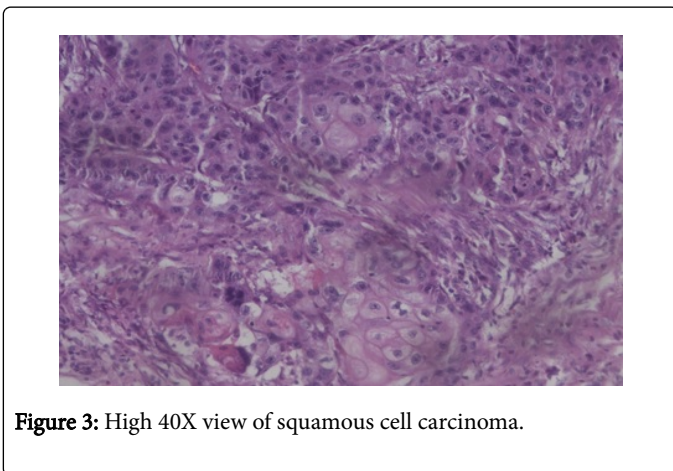


Figure 3: High 40X view of squamous cell carcinoma.

## Discussion

Mature cystic teratoma is common ovarian tumor among young patients. It is also known as dermoid cyst. It is a germ cell tumor. Squamous cell carcinoma arising in mature cystic teratoma is extremely rare [6]. Other malignant transformations include adenocarcinoma and carcinoid tumors [7] can evolve from any germ layer [8]. It carries poor prognosis especially when diagnosed in advanced stage. Chemotherapy is required along with the surgery. Its preoperative diagnosis is difficult. Clinical features, tumor markers, CECT and MRI are not definitive for diagnosis. The diagnosis can be confirmed only on histopathologic examination. The malignancy can be suspected when mature cystic teratoma is arising in postmenopausal women [7,8]. The size of the cyst is larger than 9.9 cm [9]. Cut section of the cyst shows solid and cystic areas. The adhesions are seen during surgery. These features can be considered as risk factors for the malignant transformation. Takagi et al. have studied tumor markers and found CEA to be more useful than CA 125 and CA19-9 in malignant transformations [6].

The two cases presented here were also from postmenopausal age. The size of the cysts was greater than 9.9 cm. One of the case showed solid cystic areas while other showed adhesions with the posterior wall and omentum. The tumor marker can suggest the malignant transformation of mature cystic teratoma.

## Conclusion

Although mature cystic teratoma is common but its malignant transformation into Squamous cell carcinoma, adenocarcinoma is extremely rare. It carries poor prognosis and need chemotherapy along with surgery. It has to be diagnosed early. Its preoperative diagnosis is difficult and can be confirmed on histopathology only so clinicians, radiologist and pathologist should be well aware of this entity.

## Conflict of Interest

There was no conflict of interest between the authors.

## References

1. Kong CS, Longacre TA, Hendrickson MR (2012) Philadelphia: Lippincott, Williams & Wilkins; 2012. *Gynecol Oncol* 38: 176-178.
2. Comerci JJ, Licciardi F, Bergh PA, Gregori C, Breen JL (1994) Mature cystic teratoma: A clinicopathologic evaluation of 517 cases and review of the literature. *Obstet Gynecol* 84: 22-28.
3. Shen DH, Khoo US, Xue WC, Cheung AN (1998) Ovarian mature cystic teratoma with malignant transformation: An interface cytogenetic study. *Int J Gynecol Pathol* 17: 351-357.
4. Hackethal A, Brueggmann D, Bohlmann MK, Franke FE, Tinneberg HR, et al. (2008) Squamous-cell carcinoma in mature cystic teratoma of the ovary: Systematic review and analysis of published data. *Lancet Oncol* 9: 1173-1180.
5. Hurwitz JL, Fenton A, McCluggage WG, McKenna S (2007) Squamous cell carcinoma arising in a dermoid cyst of the ovary: A case series. *BJOG* 114: 1283-1287.
6. Takagi H, Ichigo S, Murase T, Ikeda T, Imai A (2012) Early diagnosis of malignant: Transformed ovarian mature cystic teratoma: Fat-suppressed MRI findings. *J Gynecol Oncol* 23: 125-128.
7. Hackethal, Brueggmann D, Bohlmann MK, Franke FE, Tinneberg HR, et al. (2008) Squamous-cell carcinoma in mature cystic teratoma of the ovary: Systematic review and analysis of published data. *Lancet Oncol* 9: 1173-1180.

8. Rim SY, Kim SM, Choi HS (2006) Malignant transformation of ovarian mature cystic teratomas. *Int J Gynecol Cancer* 16: 140-144.
9. Kikkawa F, Ishikawa H, Tamakoshi K, Nawa A, Suganuma N, et al. (1997) Squamous cell carcinoma arising from mature cystic teratoma of the ovary: A clinicopathologic analysis. *Obstet Gynecol* 89: 1017-1022.