

Y90 Radioembolization of Liver Tumors *via* Radial approach-Correlation between Common Femoral Artery and Radial Artery Size

Jarren Adam¹, Michael Brockman¹, Nisha Kalmadi² and Robert Hanna^{2*}

¹Department of Interventional Radiology, Division of Diagnostic Radiology, Banner Desert Medical Center, Mesa, Arizona 85202, USA

²Department of Interventional Radiology, Division of Diagnostic Radiology, Arizona State University, 800 W Jefferson St, Kirksville, MO 63501, United States

Abstract

Purpose: Typically, before the Y90 Radioembolization procedure undergoes, a CT is completed and the Barbeau test followed by radial artery ultrasound is used to determine if the artery is sufficiently large for vascular access. 2.5 mm is the average radial artery diameter, and a vessel measurement of 2.0 mm is the recommended minimum diameter for safe vessel access, but a diameter of 1.5-2.0 mm can be accessed. Our study explores using common femoral artery measurements from the pre-procedure CT abdomen/pelvis to assess in a binary manner if the vessel is sufficiently large to use for radial artery access.

Materials and methods: All computed tomography scans of Yttrium-90(Y90) Radioembolization of the liver tumor procedures from January 1, 2015 to December 31, 2019 were retrospectively reviewed. Medical records were used from 47 procedures to gather patients' age, gender, Avastin use, femoral artery size (mm), administer Y90 (%), history of diabetes, and smoking status were recorded.

Results: The minimum femoral artery size in patients who underwent transradial artery Y90 liver tumor Radioembolization was 6 mm, with a mean femoral artery size of 10 mm. A comparative analysis of Y90 liver tumor uptake revealed no significant difference in Radioembolization tumor uptake based on the initial site of procedure, trans femoral or transradial artery, ($p>0.81229$).

Conclusion: The study suggests that femoral arteries can predict radial artery diameter and that a femoral artery diameter of 10 mm should yield high confidence that the patient will be a candidate for transradial approach.

Introduction

For the past decade, Radioembolization with Yttrium-90(Y90) has revolutionized the treatment of liver tumors. Trans arterial methodologies for chemoembolization, Radioembolization, and bland embolization have reduced the need for formally invasive open procedures [1,2]. Prior to the procedure, a Computed Tomography (CT) scan is performed to stage the liver tumor and once the appropriate preoperative steps are completed, the procedure is performed *via* the Trans arterial access. The catheter tip is moved through the arterial system to deliver the Y90 microspheres to the tumor which will disrupt the tumor's cellular replication integrity, destroying the tumor in effect [3,4]. Possible side effects secondary to this procedure include fatigue, nausea, vomiting, fever, abdominal pain, anorexia, and cachexia [5,6]. Severe side effects that warrant hospitalization include gastrointestinal ulceration caused by spread of microsphere [7]. Hepatobiliary toxicity may occur but it is difficult to conclude if the abnormal enzymes and metabolite levels are due to worsening hepatic cirrhosis or secondary to the procedure [7]. Due to the nature of the procedure, there is a low possibility of causing vascular injury and is mostly seen in patients who are taking systemic chemotherapy medication due to weakening of the vessel wall [7,8].

Innovations such using the radial artery instead of the traditional femoral artery access, has proven to be a practicable and safe technique that has reduced recovery time and pain, however extra steps must be taken [9-14]. If a transradial artery procedure is required, a Barbeau test and an ultrasound are often performed to determine if the diameter and circulatory flow are adequate to prevent ischemia to ulnopalmar arch [15-19]. The Barbeau test relies on the plethysmography waveform of the pulse oximetry and without adequate flow, waveforms cannot be viewed in extremities assessed [19,20]; Furthermore, the waveforms

signal changes according to the hypervolemia or flow in a hemodynamic stable patients [21].

While CT scans are used to determine the extent of the liver tumor, the question arises as to whether the CT scan can also predict the radial artery size. Regardless of the inconvenience and expense of receiving an ultrasound, transradial artery Radioembolization seems to be on the trajectory for standard-of-practice, forgoing the Trans femoral artery-based procedure [15-18]. The purpose of this study is to assess if the CT scan can serve as an additional or primary method for predicting the radial artery's feasibility for the procedure instead of requiring a pre-operative ultrasound.

Materials and Methods

A retrospective analysis was conducted on 47 patients, each having Y90 Radioembolization performed at our institution from January 1, 2015 to December 31, 2019 (Table 1). Before data was reviewed from each patient, IRB was obtained and approved by the institution; patients were

***Corresponding author:** Robert Hanna, Department of Interventional Radiology, Division of Diagnostic Radiology, Banner Desert Medical Center, Mesa, Arizona 85202, USA, Tel: 801-870-8942; E-Mail: sa200388@atsu.edu

Received: 01-Feb-2022, Manuscript No. AOT-22-51318; **Editor assigned:** 04-Feb-2022, PreQc No. AOT-22-51318(PQ); **Reviewed:** 18-Feb-2022, QC No. AOT-22-51318; **Revised:** 21-Feb-2022, Manuscript No. AOT-22-51318(R); **Published:** 28-Feb-2022, DOI: 10.4172/aot-7.s1-1000003.

Citation: Adam J, Brockman M, Kalmadi N, Hanna R (2022) Y90 Radioembolization of Liver Tumors *via* Radial approach-Correlation between Common Femoral Artery and Radial Artery Size. J Oncol Res Treat S1:003.

Copyright: © 2022 Adam J, et al. This is an open-access article distributed under the terms of the Creative Commons Attribution License, which permits unrestricted use, distribution, and reproduction in any medium, provided the original author and source are credited.

Y90 data set								
	Access site	Administered Y90 (%)	Femoral artery size (mm)	Smoking history	Diabetic	Avastin exposure	Age	Gender
1	Femoral	95	11.2	No	Yes	No	63	Male
2	Femoral	95	11	Yes	No	No	70	Male
3	Femoral	88.2	12.6	No	No	No	52	Male
4	Radial	96.2	11.6	No	No	No	53	Male
5	Radial	78.4	11.6	No	No	No	54	Male
6	Femoral	100	8.5	No	No	No	72	Female
7	Radial	96.1	7.7	Yes	No	No	50	Female
8	Radial	95.3	12.2	No	No	Yes	78	Male
9	Radial	96.3	12.7	No	No	No	53	Male
10	Radial	99.4	13	No	No	No	66	Male
11	Femoral	95.3	7.3	Yes	Yes	No	58	Female
12	Femoral	67.5	8.3	Yes	No	No	52	Female
13	Radial	98.4	9.2	Yes	No	No	58	Male
14	Femoral	96.1	11.5	Yes	No	No	50	Male
15	Femoral	93.4	10.6	Yes	No	No	65	Male
16	Radial	91.2	11.3	Yes	Yes	No	72	Male
17	Femoral	100	8.6	No	No	No	76	Female
18	Femoral	88	9.9	No	No	No	63	Female
19	Femoral	80	8.4	No	No	No	50	Female
20	Radial	93.3	9.9	Yes	No	No	71	Male
21	Femoral	95.9	8	Yes	No	No	45	Male
22	Radial	84.1	9.8	No	No	No	82	Male
23	Radial	95.9	13.7	Yes	No	No	51	Male
24	Radial	96.2	7.9	Yes	No	No	57	Male
25	Radial	98	6.2	No	No	No	63	Female
26	Radial	92.5	9.6	No	No	No	73	Female
27	Radial	73.4	11.1	No	No	Yes	66	Female
28	Radial	100	8.3	No	No	No	64	Female
29	Radial	43	10	No	No	No	74	Female
30	Radial	83.6	11.1	No	No	No	79	Female
31	Radial	100	11.1	Yes	No	No	73	Female
32	Femoral	97.2	13.1	No	No	No	74	Male
33	Radial	98.8	9.4	Yes	Yes	No	48	Male

Table 1: Patient dataset from Y90 liver tumor radio embolization procedure.

assigned an identification number to avoid any biases and to preserve confidentiality of personal information. All methods, experiments, and retrospective studies were carried out in accordance with relevant guidelines and regulations. All experimental protocols were approved by Banner Health. Informed consents were waived by the Banner Health Institutional Review Board Ethics Committee.

Prior to each procedure, the patient underwent an ultrasound and Barbeau test. If the radial artery was 2.5 mm or greater in size and the patient had Barbeau A-C waveforms, the patient was deemed a candidate for radial artery access. If the vessel was smaller than 2.5 mm or Barbeau D, they underwent femoral arterial access. No other exclusions were made from statistical analysis if the patient met the prerequisites. Python-base module, Scipy (Version 1.6.0) was used to analyse the data.

The research team used a pre-operative CT abdomen/pelvis to measure

the diameter of the femoral artery at the level of the femoral head. This value was recorded. Medical records were reviewed for demographic data. If no preoperative CT was performed, the patient was excluded. 47 patients were reviewed while 33 patients were included in the study. CT established diameters pertaining to presented study requirements. There were no other requirements to be included in the study. No other exclusion was made from statistical analysis if the patient met the prerequisites. There were no post-procedural complications recorded.

Procedural techniques

Data collection: For each respective Y90 liver tumor Radioembolization procedure performed, an accession number was assigned. The accession number adhered to Health Insurance Portability and Accountability Act (HIPAA) compliance coinciding with providing the patient appropriate anonymity during analysis. Only Y90 Radioembolization

procedure information and patient demographics pertaining to gender, age, history of smoking, Avastin usage, and history of diabetic diagnosis were provided due to necessity for analysis. All other de-anonymizing information was withheld for patient anonymity and safety.

The CT scan images for each procedure were reviewed for analysis. Measurements of the femoral artery diameter were performed by leveraging the radiologic imaging software, Synapse[®] by Fujifilm Global. We validated the measurements by repeating the measuring step, blinded to the initial results, and reporting the mean femoral artery diameter between the two measurements steps if a difference was present. The final results of the femoral artery diameter were reported in millimetres.

From the records, total percentage of Y90 administration relative to the prescribed dose and procedure access site (femoral or radial artery) were recorded.

Analysis

Results of each procedure, (access site, total percentage uptake, femoral artery size, smoking history, diabetes, Avastin, age, and gender) were reported in Table 1. Figure 1 compares procedure access site to femoral artery dimension. Statistical analysis was performed on the collected data via the open-source computer language, Python (Version 3.9.1) [22], and the open-source, web-based interactive computational environment, Jupyter Notebook (Version 7.19.0) [23]. Using the statistics, Python-base module, Scipy (Version 1.6.0), characteristics of the transradial artery procedure group and Tran's femoral artery procedure group were revealed and compared [24]. Characteristics such as minimum femoral artery diameter within the transradial artery group, femoral artery diameter variability when compared to age and an

unpaired t-test of the mean Y90 tumor uptake between the radial artery procedure group and femoral artery procedure group were performed. All statistical results and methodology were reported [22,23].

Results

Of the 47 patients recorded in Table 1, 14 were excluded due to unreliable data collection, lack of pre-operative CT availability, or loss to follow up. The 33 analysed procedures contained 19 men and 14 women. The mean age of the patients was 63 years old (range 45-82 years old). It was found that 9 patients had a history of smoking, of which 5 were active smokers. 4 patients were found to have a diagnosis of diabetes and 2 patients received Avastin. The group was subdivided into patients who received Radioembolization via transradial artery or Tran's femoral artery procedure. 20 patients (12 males, 8 females) received transradial artery Radioembolization, while 13 patients (7 males, 6 females) received Tran's femoral artery Radioembolization.

The transradial artery procedure group was found to have a mean Tran's femoral artery diameter of 10 mm. The Trans femoral artery procedure group was found to have a mean femoral artery diameter of 10 mm. The minimum femoral artery diameter for the transradial artery procedure group was found to be 6 mm.

Comparative analysis of Y90 liver tumor uptake was performed via unpaired t-test. It was revealed that there was no statistical difference between the transradial artery procedure group and Trans femoral artery procedure group when comparing mean Y90 uptake ($p > 0.81229$).

Further analyses were performed via stratification of patient groups based on diabetes history, smoking history, and procedural access

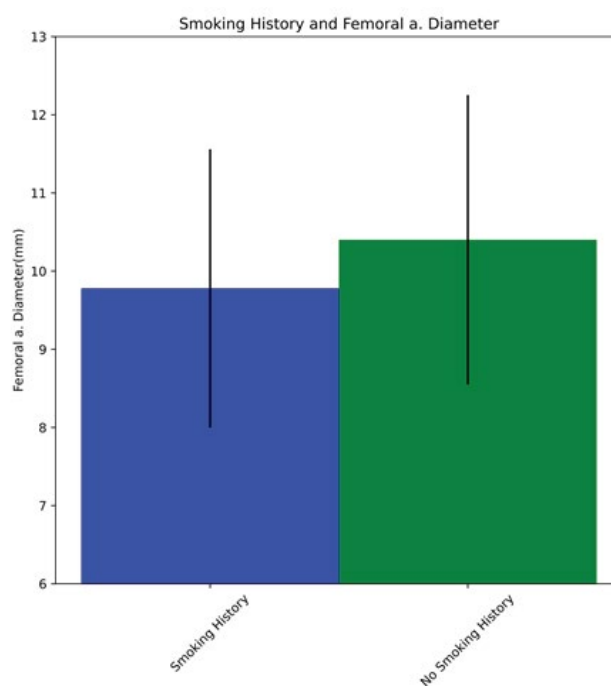


Figure 1: Comparison of mean femoral artery diameter with no respect to patient smoking diabetes diagnosis history.

Note: ■ Smoking history ■ No Smoking history

point, either transradial or Trans femoral. Figures 1 and 2 illustrate the differences in mean femoral artery diameter based on prior diagnosis of diabetes and prior smoking history, respectively. Figure 1 illustrates

the mean femoral artery diameter for patients with a prior diagnosis of diabetes was reported to be 9.8 mm with a standard deviation of 1.6 mm, while the mean femoral artery diameter for patients without a

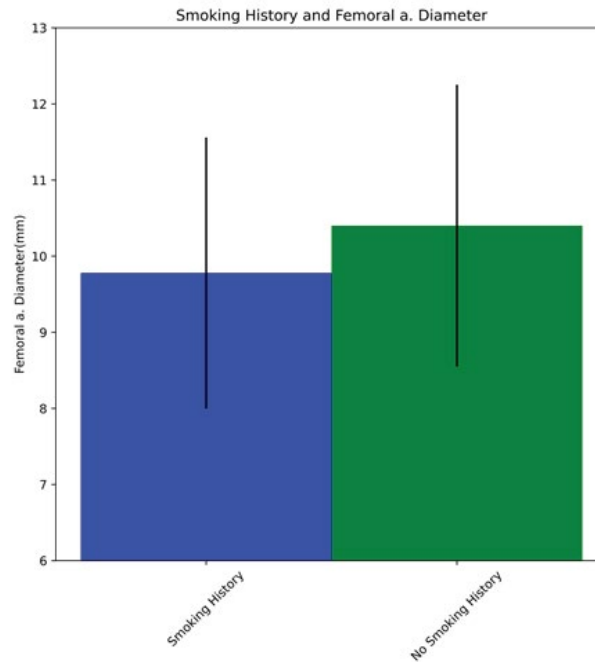


Figure 2: Comparison of mean femoral artery diameter with no respect to patient diabetes diagnosis history. Note: Blue Diabetes history Green No Diabetes history

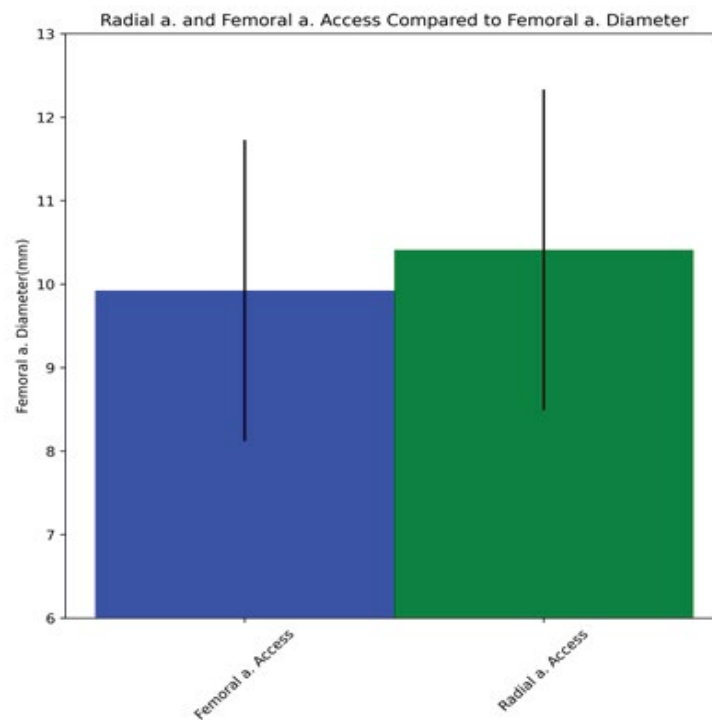


Figure 3: Comparison of mean femoral artery diameter with no respect to radioembolization access site. Note: Blue Femoral a. access Green Radial a. access

prior diagnosis of diabetes was reported to be 10.3 mm with a standard deviation of 1.9 mm. Figure 2 illustrates the mean femoral artery diameter for patients with a smoking history was reported to be 9.8 mm with a standard deviation of 1.8 mm, while the mean femoral artery diameter for patients without a smoking history was reported to be 10.4 mm with a standard deviation of 1.9 mm.

Figure 3 illustrates the comparison of mean femoral diameter between patients that successfully received Tran's femoral artery Radioembolization and transradial artery Radioembolization. It was found that the mean femoral artery diameter for the Trans femoral artery Radioembolization group was 9.9 mm with a standard deviation of 1.8 mm, while the mean for the transradial artery Radioembolization group was 10.4 mm with a standard deviation of 1.9 mm.

Discussion

Transradial approach is becoming the preferred method of treatment for Y90 liver tumor Radioembolization. From a clinical standpoint, studies have shown that transradial artery Radioembolization has similar clinical outcomes when compared to Tran's femoral artery Radio embolization [25]. In addition, patients have shorter recovery times when using the transradial approach. As discussed by Liu, transradial artery procedures were associated with significantly lower pain scores overall during the procedure, at the access site during the procedure, and in the recovery room compared with trans femoral artery procedures [12].

Our study attempts to improve the ease of pre-procedure planning for transradial Radioembolization by providing an alternative means of assessing radial artery capacity for procedure without needing additional tests. Traditionally, ultrasound, as well as, the Barbeau test followed by radial artery ultrasound is used for radial artery assessment. This study reports successful assessment of the radial artery by sole reliance on femoral artery measurements *via* CT scan.

Out of 47 patients that have undergone Y90 Radioembolization, 33 patients' femoral arteries were measured and recorded regardless of access point of procedure. 20 patients underwent the transradial approach with a mean femoral artery diameter of 10 mm. No adverse effects or diminished outcomes were found when using either artery. Thus we conclude that a femoral artery diameter of 10 mm or greater is predictive of adequate radial artery diameter for catheter access. Moreover, statistical analysis didn't reveal a significant difference between radioisotope uptake between the different access points for the procedure ($p>0.81229$). It is acknowledged that due to limited sample size, more investigation should be performed on the variable that could influence radial artery size.

Other studies have attempted to capture contributing factors to radial artery size variability. For example, it is understood that differences in sex may also include anatomic differences, such as vasculature diameters and lengths, can have an effect on procedure times, rates of vessel spasm, and radiation exposures. However, multiple studies have found that sex is insignificant when attempting to predict radial artery size based on characteristics such as Body Mass Index (BMI), lifestyle, etc. [12,26,27] Other methods have been used to assess radial artery size differences. In Aykan it was found that radial artery diameter was correlated with wrist circumference ($r=0.539$, $p<0.001$), height ($r=0.258$, $p<0.001$), weight ($r=0.237$, $p<0.001$), body mass index ($r=0.167$, $p=0.013$), shoe size ($r=0.559$, $p<0.001$), and pulse pressure ($r=-0.161$, $p=0.016$). The right radial artery was larger in men than in women (2.73 ± 0.39 mm *vs.* 2.15 ± 0.35 mm, $p<0.001$), and smaller in

patients with sedentary office work than in physically active outdoor workers (2.42 ± 0.45 mm *vs.* 2.81 ± 0.37 mm, $p<0.001$) [28].

Further investigation of radial artery size was performed by Kis. Using ultrasound guidance for vascular access, their study performed successful transradial artery Y90 Radioembolization procedures. Though the study size was only 27 patients, Kis found that radial arteries with a diameter of greater than 1.7 mm were indicative of transradial feasibility [29].

Regardless of procedure success, the transradial artery Radioembolization is not without its drawbacks. It was found by Kis. that the procedure required greater technical acuity and skill. Traditionally, Tran's femoral artery procedures are routine for interventional radiologists [29]. Thus, expenses for continuing education must be taken into account when deciding between the two methods of Radioembolization [12,30].

Conclusion

These concerns have subsided due to improvements in technology and imaging modalities. In addition, more training programs are exposing their trainees to the transradial approach earlier in their careers. Physicians continue to become more precise and healthcare costs conscious which improves patient care. What may seem now as a more difficult procedure, transradial artery procedures show greater promise over Tran's femoral artery procedures in a multitude of medical fields, from interventional oncology to cardiology. Since medical infrastructure has been adapting from the traditional femoral artery approach to the newer transradial approach, our research hopes to further this advancement by providing an improved method to assess radial artery size based off of the pre-procedure CT.

This study acknowledges the limited retrospective cohort size with regards to the findings. Moreover, this study would benefit from measurement of the radial artery per each patient, which would provide a direct comparative analysis between the femoral and radial artery.

Conflict of Interest

No conflicts of interest reported.

Funding Sources

No financial gain or funding was provided in conducting the study.

IRB

Banner Health- Project # 05-18-0038, iRIS Reference # 020561, FWA #00002630

IORG #0004299

Acknowledgements

This study was supported by Banner Desert Medical.

Presented Materials

NA

Compliance with Ethical Standards

Retrospective study: For this type of study formal consent is not required per Banner Health Institutional Review Board.

References

1. Riaz A, Lewandowski RJ, Kulik LM, Mulcahy MF, Sato KT, et al. (2009) Complications following radioembolization with yttrium-90 microspheres: A

- Comprehensive literature review. *J Vasc Interv Radiol* 20: 1121-1130.
2. Sacco R, Bargellini I, Bertini M, Bozzi E, Romano A, et al. (2011) Conventional versus doxorubicin-eluting bead transarterial chemoembolization for hepatocellular carcinoma. *J Vasc Interv Radiol* 22: 1545-1552.
 3. Kallini JR, Gabr A, Salem R, Lewandowski RJ (2016) Transarterial radioembolization with yttrium-90 for the treatment of hepatocellular carcinoma. *Adv Ther* 33: 699-714.
 4. Sia J, Szmyd R, Hau E, Gee HE (2020) Molecular mechanisms of radiation-induced cancer cell death: A primer. *Front Cell Dev Biol* 8: 41.
 5. Kennedy AS, Coldwell D, Nutting C, Murthy R, Wertman DE, et al. (2006) Resin 90Y-microsphere brachytherapy for unresectable colorectal liver metastases: Modern USA experience. *Int J Radiat Oncol Biol Phys* 65: 412-425.
 6. Salem R, Lewandowski RJ, Atassi B, Gordon SC, Gates VL, et al. (2005) Treatment of unresectable hepatocellular carcinoma with use of 90Y microspheres (TheraSphere): Safety, tumor response, and survival. *J Vasc Interv Radiol* 16: 1627-1639.
 7. Ali SM (2011) Radioembolization for hepatocellular carcinoma using TheraSphere®. *Saudi J Gastroenterol* 17: 215-217.
 8. Murthy R, Eng C, Krishnan S, Madoff DC, Habbu A, et al. (2007) Hepatic yttrium-90 radioembolotherapy in metastatic colorectal cancer treated with cetuximab or bevacizumab. *J Vasc Interv Radiol* 18: 1588-1591.
 9. Posham R, Biederman DM, Patel RS, Kim E, Tabori NE, et al. (2016) Transradial approach for noncoronary interventions: A Single-center review of safety and feasibility in the first 1,500 cases. *J Vasc Interv Radiol* 27: 159-166.
 10. Dam LV, Geeraedts T, Bijdevaate D, Doormaal PJV, The A, et al. (2019) Distal radial artery access for noncoronary endovascular treatment is a safe and feasible technique. *J Vasc Interv Radiol* 30: 1281-1285. [CrossRef], [Google Scholar], [PubMed]
 11. Pua U, Sim JZT, Quek LHH, Kwan J, Lim GHT, et al. (2018) Feasibility study of "snuffbox" radial access for visceral interventions. *J Vasc Interv Radiol* 29: 1276-1280.
 12. Liu LB, Cedillo MA, Bishay V, Ranade M, Patel RS, et al. (2019) Patient experience and preference in transradial versus trans femoral access during trans arterial radioembolization: A randomized single-center trial. *J Vasc Interv Radiol* 30: 414-420.
 13. Cooper CJ, El-Shiekh RA, Cohen DJ, Blaesing L, Burket MW, et al. (1999) Effect of transradial access on quality of life and cost of cardiac catheterization: A randomized comparison. *Am Heart J* 137: 430-436.
 14. Satti SR, Vance AZ, Golwala SN, Eden T (2017) Patient preference for transradial access over transfemoral access for cerebrovascular procedures. *J Vasc Interv Radiol* 28: 1-5.
 15. Bishay VL, Biederman DM, Ward TJ, van der Bom IMJ, Patel RS, Kim E, et al. (2016) Transradial approach for hepatic radioembolization: Initial results and technique. *AJR Am J Roentgenol* 207: 1112-1121.
 16. Yamamoto K, Natsuaki M, Morimoto T, Shiomi H, Watanabe H, et al. (2020) Transradial vs. transfemoral percutaneous coronary intervention in patients with or without high bleeding risk criteria. *Circ J* 84: 723-732.
 17. Gabr A, Ali R, Al Asadi A, Mora R, Mouli S, et al. (2019) Technical aspects and practical approach toward same-day y90 radioembolization in the management of hepatocellular carcinoma. *Tech Vasc Interv Radiol* 22: 93-99.
 18. Thakor AS, Alshammari MT, Liu DM, Chung J, Ho SGF, et al. (2017) Transradial access for interventional radiology: Single-centre procedural and clinical outcome analysis. *Can Assoc Radiol J* 68: 318-327.
 19. Zarea AM, Ahmed NT, Elsaman SEA (2021) Comparison between modified Allen's test and Barbeau test for the assessment of hands' collateral circulation before arterial puncture among critically ill patients. *Int J Africa Nurs* 15: 100338.
 20. Pant S, Umesh S, Asokan S (2020) A Novel approach to acquire the arterial pulse by finger plethysmography using fiber bragg grating sensor. *IEEE Sens J* 20: 5921-5928.
 21. Pizov R, Eden A, Bystritski D, Kalina E, Tamir A, et al. (2010) Arterial and plethysmographic waveform analysis in anesthetized patients with hypovolemia. *Anesthesiology* 113: 83-91.
 22. Python.org.
 23. Jupyter and the future of IPython-IPython.
 24. SciPy.org
 25. Iezzi R, Pompili M, Posa A, Annicchiarico E, Garcovich M, et al. (2017) Transradial versus transfemoral access for hepatic chemoembolization: Inpatient Prospective single-center study. *J Vasc Interv Radiol* 28: 1234-1239.
 26. Rao SV (2015) Transradial angiography and intervention: An Issue of interventional cardiology clinics. Elsevier Health Sciences.
 27. Kim Y, Ahn Y, Kim MC, Sim DS, Hong YJ, et al. (2018) Gender differences in the distal radial artery diameter for the snuffbox approach. *Cardiol J* 25: 639-641.
 28. Aykan AC, Hatem E, Kalaycıoğlu E, Aykan DA, Gökdeniz T, et al. (2015) Prediction of radial artery diameter in candidates for transradial coronary angiography: Is Occupation a factor? *Turk Kardiyol Dern Ars* 43: 450-456.
 29. Kis B, Mills M, Hoffe SE (2016) Hepatic radioembolization from transradial access: Initial experience and comparison to transfemoral access. *Diagn Interv Radiol* 22: 444-449.
 30. Mitchell MD, Hong JA, Lee BY, Umscheid CA, Bartsch SM, et al. (2012) Systematic review and cost-benefit analysis of radial artery access for coronary angiography and intervention. *Circ Cardiovasc Qual Outcomes* 5: 454-462.