

Distal Posterior Treatment of Cerebral Artery Aneurysm

Jennifer Joel*

Department of Radiology, St Georges, University of London, UK

Image Article

Aneurysm of the distal back cerebral vein is an exceptional and inciting substance to treat on account of its characteristics, significant actual region and enveloping complex neuro anatomic plans. Treatment decisions of distal PCA aneurysms integrate cautious cut-out, pulmonary veno-occlusive disease (PVO) and endovascular treatment. Among these, endovascular the board with stream diverter stents has been continuously utilized actually with incredible outcomes. In this survey, we depict our specific discernments in the treatment of a P3 aneurysm utilizing Pipeline embolization device (PED).

Though distal back cerebral stock course aneurysms are intriguing substances, they present a treatment challenge in light of their significant anatomic region, complex enveloping neuro anatomic plans, higher pace of fusiform and gigantic saccular aneurysms. Saccular aneurysms are more plausible dismantling in starting which is temperamental with higher speed of dilatation and channel, despite relationship with other vasculopathies like vasculitis, AVMs and Moyamoya. Of the open organization decisions, endovascular treatment has transformed into the mainstay of treatment. Late advancement in stream diverters

has provoked extending use of these devices in the treatment of various aneurysms including PCA. In this audit, we depict our particular notes in the off-mark use of Pipeline embolization contraction in the treatment of distal PCA aneurysms (Figure 1).

Aneurysms of the PCA address an interesting and an inciting component to treat. They will for the most part have unequivocal characteristics when diverged from cerebral aneurysms elsewhere including inclination to incorporate proximal sections (P1 and P2), higher recurrence of fusiform and gigantic saccular aneurysms, saccular aneurysms are more plausible dismantling in starting which are unstable with higher speed of dilatation and release, despite relationship with other vasculopathies like vasculitis, AVMs and Moyamoya [1-4].

Acknowledgement

None

Conflict of Interest

None

References

1. Goehre F, Jahromi BR, Hernesniemi J, Elsharkawy A, Kivisaari R, et al. (2014) Characteristics of posterior cerebral artery aneurysms: an angiographic analysis of 93 aneurysms in 81 patients. *Neurosurgery* 75: 134-144.
2. Kobkitsuksakul C, Somboonnitiphol K, Apirakkan M, Lueangapong P, Chanthanaphak E (2020) Dolichoectasia of the internal carotid artery terminus, posterior communicating artery, and posterior cerebral artery: The embryonic caudal ramus internal carotid segmental vulnerability legacy. *Interv Neuroradiol* 26: 124-130.
3. Hou K, Lv X, Yu J (2022) Endovascular Treatment of Posterior Cerebral Artery Trunk Aneurysm: The Status Quo and Dilemma. *Front Neurol* 12: 746525.
4. Ciceri EF, Klucznik RP, Grossman RG, Rose JE, Mawad ME (2001) Aneurysms of the posterior cerebral artery: classification and endovascular treatment. *AJNR Am J Neuroradiol* 22: 27-34.

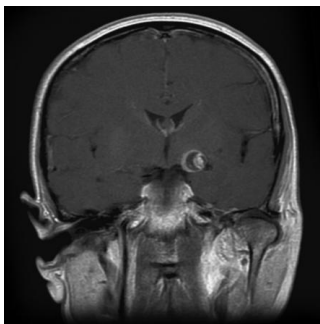


Figure 1: Cerebral aneurysm.

*Corresponding author: Jennifer Joel, Department of Radiology, St Georges, University of London, UK, E-mail: jennifer.joel@gmail.com

Received: 04-Oct-2022, Manuscript No. roa-22-78678; Editor assigned: 06-Oct-2022, PreQC No. roa-22-78678 (PQ); Reviewed: 20-Oct-2022, QC No. roa-22-78678; Revised: 24-Oct-2022, Manuscript No. roa-22-78678 (R); Published: 31-Oct-2022, DOI: 10.4172/2167-7964.1000409

Citation: Joel J (2022) Distal Posterior Treatment of Cerebral Artery Aneurysm. *OMICS J Radiol* 11: 409.

Copyright: © 2022 Joel J. This is an open-access article distributed under the terms of the Creative Commons Attribution License, which permits unrestricted use, distribution, and reproduction in any medium, provided the original author and source are credited.