

Locally Advanced Breast Cancer Status: Experience at the Sultan Qaboos Comprehensive Cancer Care and Research Centre

Adil Aljarrah^{1*}, Adugba E Aboje⁵, Nidhal Al Harrasi¹, Mohammed Alazri¹, Usama Al Ameri¹, Badriya S. Al-Qassabi², Marwa Alriyami³ and Khalid AlBimani⁴

¹Department of Surgery, Sultan Qaboos University Hospital Muscat, Sultanate of Oman

²Departments of Radiology, Sultan Qaboos University Hospital Muscat, Sultanate of Oman

³Departments of Pathology, Sultan Qaboos University Hospital Muscat, Sultanate of Oman

⁴Department of medicine- oncology division, Sultan Qaboos University Hospital Muscat, Sultanate of Oman

Abstract

Infiltrating syringomatous adenoma of the nipple (SAN) is a very rare benign tumour of the breast. It's often present with a lump in areolar/ nipple complex (ANC), and can occur in women of all ages. The clinical and radiology finding are suggestive of breast cancer. It is known to cause local infiltration, but according to the literature reviews, there has been no reported case of metastasis. Surgical excision of the lump is the curative management. We present a case report of 43 years old female, who presented with history of left breast pain and mass. She had triple assessment, and showed to have infiltrating syringomatous adenoma of the nipple. She underwent lump excision. Infiltrating syringomatous adenoma of the nipple should be ruled out from the deferential diagnosis of areolar and nipple lumps to avoid misdiagnosis and unnecessary management.

Keywords: Breast cancer; Infiltrating Syringomatous Adenoma; Nipple

Introduction

Syringomatous adenoma is one of the rare benign breast tumor that first described by Rosen in 1983 [1] known to show local infiltrative proliferation but does not metastasize [2]. The tumor usually occurs in women between 11 to 76 years with a mean age of presentation of 40 years [3]. This is case report of 43-year-old female who underwent local excision of left nipple areola complex after a confirmed diagnosis of Syringomatous adenoma.

Case Report

This is a case of 43 years old female who presented to the breast clinic with two months history of left breast pain. She was initially seen in a private clinic where they found a large mass in left upper quadrant of the breast. However, the mass resolved following the treatment with oral medication which was prescribed from the same clinic. She is not known to have any medical conditions. In history, the patient denied having risk factors for breast pathology. Age of Menarche was at 13 years. She is married with 6 children's, all were spontaneous vaginal delivery and breastfed, age of first pregnancy at age of 18 years old, denies taking contraceptive hormone, no family history for a breast, ovarian or other malignancies. Physical examination showed thickening of the left nipple, rest of examination was unremarkable, she was assessed with triple assessment (clinical examination, imaging and histopathology)

X ray mammography was done and was reported as a heterogeneously dense fibro glandular tissue seen in both breasts. However, the right breast showed 3 foci of punctate macro calcifications seen in the outer lower quadrant and having a benign morphology. While in left breast, there was an irregular and dense mass seen in the inner upper breast. It is the posterior fat/fibro glandular interface. It persisted on the compression views but became more is dense to the surrounding. It measures 1 cm x 0.9 cm. Also, there was heterogeneous macro calcification seen in the left nipple at the lower aspect.

Bilateral breast ultrasound was done. Left breast showed several scattered cysts. Corresponding to the site of palpable abnormality there

is a cyst at 1 o'clock. There was an oval shaped macro lobulated lesion seen deep at 11:30. It measures 9 mm x 3.8 mm x 9.3 mm. No internal vascularity was detected. The micro calcifications are seen in the nipple inferiorly and no retro areolar mass seen. While in right breast, Small scattered cysts are detected. Axillary lymph nodes were looking benign in both breasts

Surgical biopsy (Wedge biopsy) was done: The pathology of the wedge biopsy taken from the left nipple by the surgeon revealed infiltrating adnexal tumor, favouring infiltrating Syringomatous adenoma of the nipple. The deep margins of biopsy where involved.

Ultrasound guided core biopsy of left breast was taken at 11 o'clock lesion and reported as A fibro adenoma.

Ultrasound guided placement of hookwire: Preliminary ultrasound revealed a focal hypoechoic lesion at 11 o'clock position in left breast. The hook wire was deployed across the lesion. No immediate complications were encountered.

Patient was admitted for left nipple areolar complex resection and left fibroadenoma excision. Operation was uneventful. Patient discharged on the second day

Discussion

Syringomatous adenoma is one of the rare benign breast tumor that was first described by Rosen in 1983 [1] known to show local infiltrative proliferation but does not metastasize [2].

***Corresponding author:** Adil Aljarrah, Department of Surgery, Sultan Qaboos University Hospital Muscat, Sultanate of Oman, Tel: 0096899446622; E-mail: aljarrah.adil@gmail.com

Received: 04-Oct-2022, Manuscript No: JCD-22-64289, **Editor assigned:** 06-Oct-2022, PreQC No: JCD-22-64289(PQ), **Reviewed:**20-Oct-2022, QC No: JCD-22-64289, **Revised:** 25-Oct-2022, Manuscript No: JCD-22-64289(R), **Published:** 01-Nov-2022, DOI: 10.4172/2476-2253.1000155

Citation: Aljarrah A, Aboje AE, Harrasi NA, Alazri M, Ameri UA, et al. (2022) Locally Advanced Breast Cancer Status: Experience at the Sultan Qaboos Comprehensive Cancer Care and Research Centre. J Cancer Diagn 6: 155.

Copyright: © 2022 Aljarrah A. This is an open-access article distributed under the terms of the Creative Commons Attribution License, which permits unrestricted use, distribution, and reproduction in any medium, provided the original author and source are credited.

Clinical features

The typical clinical presentation is unilateral single firm breast mass that causes itching, pain, nipple discharge, inversion or ulceration [1]. Because of its clinical presentation of nipple ulceration and crusting, SAN might be mistaken with Paget disease, prompting unnecessary mastectomy [4].

The tumor usually occurs in women between 11 to 76 years with a mean age of presentation of 40 years [3]. The diagnosis of SAN can be difficult with nipple adenomas and low-grade adenosquamous carcinomas as top differential [1,2]. However, Nipple duct adenoma is well circumscribed usually ulcerates and does not invade the underlying tissue [4]. Low-grade adenosquamous carcinomas usually show an adenoma-like structure derived from salivary gland duct. Thus, these carcinomas can be differentiated from their sites of origin [5].

Imaging

On imaging SAN appears as ill-defined with heterogeneous internal echoes on ultrasonography [2, 6].

SAN usually appears as a high-density mass in the sub areolar region with an irregular outline, spicule formation, and micro calcification foci on mammogram. SAN is more obvious in MRI than MMG. In fact, the imaging findings often resemble those of malignant tumors, thus tissue study is needed to distinguish between SAN and carcinoma [3].

Pathological features

Grossly, SAN is a firm tumor from 1 to 3 cm in diameter size. Cut section shows an ill-defined tumor with small cystic spaces around the nipple. The SAN tumor microscopically, has an infiltrating pattern characterized by branching cords of cells forming glandular structures. The tumor cells infiltrate the stroma and usually invade the per neural region and smooth muscle bundle [6,7]. The surrounding breast tissue might appear normal or show hyperplastic changes. Syringomatous adenoma of the nipple does not involve the overlying skin or nipple epidermis. On histological study Syringomatous adenoma of the nipple appears similar to nipple adenoma a benign variant of intraductal papilloma associated with serous or bloody nipple discharge. In which Squamous metaplasia may be present in both SAN and nipple adenoma. Microscopically, the nipple adenoma shows epithelial hyperplasia arising from a lactiferous duct displacing the nipple stroma. On the other hand, nipple Syringomatous adenoma displays stromal infiltration [5]. The followings are the diagnostic histopathological criteria of SAN (1) location in dermis and sub cutis of nipple or areola; (2) irregular, compressed, or comma-shaped tubules infiltrating into smooth muscle bundles and/or nerves; (3) presence of myoepithelial cells around the tubules; (4) presence of cysts lined by stratified squamous epithelium and filled with keratinous material; and (5) absence of mitotic activity and necrosis [3] (Figure 1).

Management

The management of SAN is complete local excision of the nipple areola complex to achieve histologically negative margins with the risk of recurrence high if not totally excised. Studies found that with complete local excision no did not show evidence of recurrence has reported on a follow-up period of 1 to 6 years. Hence, close follow up to detect local recurrence is considered necessary [5,8]. Fortunately, most of the recurrences were managed with local re-excision. Although SAN shows local infiltration and recurrence, it is not known to metastasize [6,9].

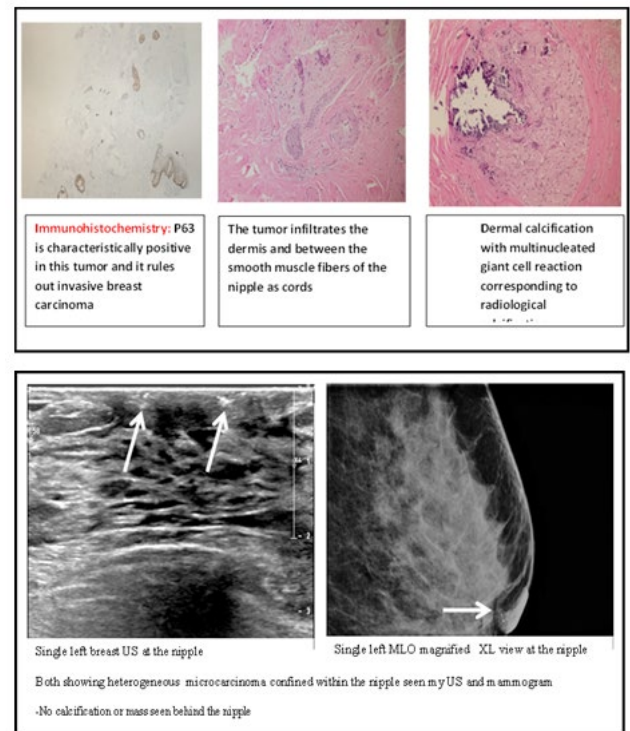


Figure 1: Diagnostic Histopathological results of SAN.

If a patient wishes to undergo Nipple-sparing resection this option can be considered for its excellent cosmetic results. However, careful postoperative follow up is necessary as recurrence period range from 1.5 months to 4 years 5 months.

Conclusion

We reported the case of 43 years old woman with SAN. Patient underwent uneventful left NAC EXCISION.

Conflict of Interest

The Authors declare no conflict of interest in this study.

References

- Rosen PP (1983) Syringomatous adenoma of the nipple. Am J Surg Pathol 7: 739-745.
- Carter E, Dyess DL (2004) Infiltrating syringomatous adenoma of the nipple: a case report and 20-year retrospective review. Breast J 10: 443-447.
- Oo KZ, Xiao PQ (2009) Infiltrating syringomatous adenoma of the nipple: Clinical presentation and literature review. Arch Pathol Lab Med 133: 1487-1489.
- Ishikawa S, Sako H, Masuda K, Tanaka T, Akioka K, et al. (2015) Syringomatous adenoma of the nipple: a case report. J Med Case Rep 9: 256.
- Rosen PP (2001) Syringomatous adenoma of the nipple. In Rosen's Breast Pathology 111-114. (Lippincott, Williams & Wilkins, Philadelphia).
- Jones MW, Norris HJ, Snyder RC (1989) Infiltrating syringomatous adenoma of the nipple: a clinical and pathological study of 11 cases. Am J Surg Pathol 13: 197-201.
- Slaughter MS, Pomerantz RA, Murad T, Hines JR (1992) Infiltrating syringomatous adenoma of the nipple. Surgery 111: 711-713.
- Eusebi V, Mai K, Taranger-Charpin A (2003) Tumours of the nipple. In: Tavassoli FA, Deville P, eds Pathology & Genetics of Tumours of the Breast and Female Genital Organs WHO 104-105.
- Suster S, Moran CA, Hurt MA (1991) Syringomatous squamous tumors of the breast. Cancer 67: 2350-2355.