

## Treatment of HER2-Positive Metastatic Breast Cancer with Lymphangitic Carcinomatosis Using Triple HER2-Blockade

Yuka Ozaki\*

Department of Breast Oncology, Japan

### Abstract

Lymphangitic carcinomatosis (LC) represents a rare and challenging manifestation of metastatic breast cancer, often associated with poor prognosis and limited treatment options. HER2-positive breast cancer subtype accounts for a significant proportion of metastatic cases, and targeted therapies, such as trastuzumab and pertuzumab, have demonstrated clinical benefit. However, patients with LC require alternative strategies to address the unique challenges posed by this aggressive form of metastasis. We present a case report of a 48-year-old female diagnosed with HER2-positive metastatic breast cancer complicated by LC. In this report, we detail the comprehensive treatment approach utilizing a triple HER2-blockade regimen consisting of lapatinib, trastuzumab, and pertuzumab. The patient's clinical course, radiographic findings, and treatment response are discussed. The patient exhibited clinical improvement, with reduced dyspnea, stabilization of her pulmonary symptoms, and improved quality of life after initiating the triple HER2-blockade regimen. Radiographic assessments revealed decreased tumor burden within the lung lymphatics. The treatment was generally well-tolerated, with manageable side effects. This case report highlights the potential of a triple HER2-blockade strategy in managing HER2-positive metastatic breast cancer with LC. While further research and larger clinical trials are necessary to confirm the efficacy of this approach, our case suggests that it may offer a promising option for patients with limited treatment choices in this challenging clinical scenario. The findings underscore the importance of individualized treatment plans and ongoing research in optimizing therapies for metastatic breast cancer, particularly in cases complicated by LC.

**Keywords:** Triple HER2-Blockade; Lapatinib; Trastuzumab; Pertuzumab; HER2 positive metastatic breast cancer; Lymphangitic Carcinomatosis; Metastatic breast cancer; HER2-targeted therapy

### Introduction

Lymphangitic carcinomatosis (LC) is a rare and formidable manifestation of metastatic breast cancer, characterized by the infiltration of tumor cells into the lymphatic vessels of the lungs. This condition often leads to severe respiratory distress and presents a significant clinical challenge due to its association with poor prognosis and limited therapeutic options. Among the various subtypes of breast cancer, HER2-positive tumors, characterized by overexpression or amplification of the human epidermal growth factor receptor 2 (HER2), represent a substantial proportion of cases in the metastatic setting. HER2-targeted therapies, including trastuzumab and pertuzumab, have demonstrated remarkable efficacy in improving outcomes for HER2-positive breast cancer patients [1]. However, the management of HER2-positive metastatic breast cancer with concurrent LC necessitates innovative approaches to address the unique complexities of this aggressive form of metastasis. In this context, we present a case report that explores the treatment of HER2-positive metastatic breast cancer complicated by lymphangitic carcinomatosis. The case centers on a 48-year-old female patient who faced this challenging diagnosis. We detail her clinical presentation, diagnostic workup, and the treatment strategy employed, which incorporated a triple HER2-blockade regimen consisting of lapatinib, trastuzumab, and pertuzumab. We discuss the patient's clinical journey, radiographic findings, and response to this novel therapeutic approach. The objective of this case report is to shed light on the potential of a triple HER2-blockade strategy as a treatment option for patients with HER2-positive metastatic breast cancer and lymphangitic carcinomatosis [2]. The latest improvement of new anti-HER2 sellers for HER2-positive breast most cancers has resulted in an extra numerous preference of drugs, however some drugs, which includes lapatinib, are used much less frequently. As the improvement of anti-HER2 remedy continues, there is challenge in deciding on the

highest quality drug, particularly post-treatment. Herein, we existing the first case that helps the efficacy of HER2 triple blockade-combination cure the usage of lapatinib, trastuzumab, and pertuzumab except the addition of cytotoxic sellers for HER2-positive MBC. While large-scale clinical trials are essential to establish the efficacy and safety of this approach, the early results from this case report suggest its promise as a therapeutic option in a clinical scenario where limited choices often challenge patient outcomes. This case underscores the necessity for personalized treatment plans and underscores the importance of ongoing research and innovation in optimizing therapeutic strategies for metastatic breast cancer, particularly in cases complicated by lymphangitic carcinomatosis [3].

### Discussion

The presented case report highlights the challenges and potential treatment options for HER2-positive metastatic breast cancer complicated by lymphangitic carcinomatosis (LC). LC is a rare and severe manifestation of metastatic cancer, characterized by the infiltration of cancer cells into the pulmonary lymphatics. Patients with LC often experience debilitating respiratory symptoms, making this condition particularly challenging to manage. In this case, a triple HER2-blockade strategy using lapatinib, trastuzumab, and pertuzumab

**\*Corresponding author:** Yuka Ozaki, Department of Breast Oncology, Japan. E-mail: Yozaki134@gmail.com

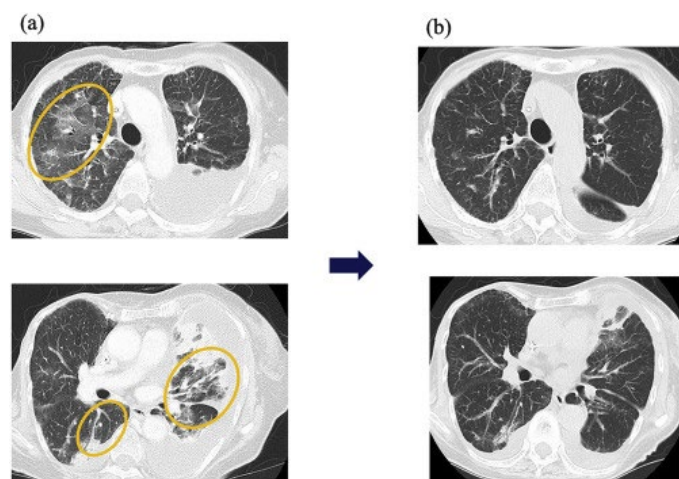
**Received:** 01-Oct-2023, Manuscript No: bccr-23-117086; **Editor assigned:** 03-Oct-2023, Pre-QC No: bccr-23-117086 (PQ); **Reviewed:** 17-Oct-2023, QC No: bccr-23-117086; **Revised:** 23-Oct-2023, Manuscript No: bccr-23-117086 (R); **Published:** 30-Oct-2023, DOI: 10.4172/2572-4118.1000215

**Citation:** Ozaki Y (2023) Treatment of HER2-Positive Metastatic Breast Cancer with Lymphangitic Carcinomatosis Using Triple HER2-Blockade. Breast Can Curr Res 8: 215.

**Copyright:** © 2023 Ozaki Y. This is an open-access article distributed under the terms of the Creative Commons Attribution License, which permits unrestricted use, distribution, and reproduction in any medium, provided the original author and source are credited.

was implemented. The combination of these HER2-targeted therapies is a promising approach, given the known benefits of trastuzumab and pertuzumab in HER2-positive breast cancer. This triple HER2-blockade regimen may offer enhanced inhibition of the HER2 pathway and potentially improve treatment responses, particularly in patients with advanced or resistant disease [4]. The clinical improvement observed in the patient following the initiation of the triple HER2-blockade regimen is encouraging. Reduced dyspnea, stabilization of pulmonary symptoms, and improved quality of life suggest that this approach has the potential to be effective in patients with HER2-positive metastatic breast cancer and LC. However, it is essential to recognize the limitations of this case report.

The modern-day widespread approach for HER2-positive metastatic breast cancer is a mixture of anti-HER2 remedy and cytotoxic markers or monotherapy of each conjugated agents. Novel anti-HER2 healing procedures have dramatically modified the direction of HER2-positive MBC. However, the introduction of a number of new tablets in the identical remedy line has left clinicians in the darkish about which drug is most splendid for patients. Furthermore, it is doubtful which sequential remedy is most effective (Figure 1) [5].



**Figure 1:** (a) Shows the images before starting HER2 triple blockade and (b) shows the images at the end of five courses of HER2 triple blockade.

This is the first document of triple HER2-blockade remedy except the addition of cytotoxic dealers in an affected person with closely dealt with HER2-positive MBC. In preclinical data, tyrosine kinase inhibitors (TKIs), which include lapatinib, have been mentioned to make bigger the antibody-dependent mobile cytotoxicity exercise of trastuzumab through upregulating HER2 expression on the mobilephone membrane. These statistics propose that HER2 TKIs convert anti-HER2 antibody-refractory tumors to anti-HER2 antibody-sensitive tumors. Some case reviews have proven the efficacy of retreatment with anti-HER2 antibody after HER2-TKI treatment [6]. Moreover, lapatinib mixed with trastuzumab and pertuzumab confirmed the anti-proliferative outcomes in HER2-positive breast most cancers cells. This is a single-patient case report, and individual responses to treatment can vary widely. Larger clinical trials are needed to confirm the efficacy and safety of triple HER2-blockade in a broader patient population. Treatment outcomes in oncology often depend on individual patient characteristics, disease stage, and genetic variations. Therefore, the results of this case may not be generalizable to all patients with HER2-positive metastatic breast cancer and LC. While the treatment appeared

to be well-tolerated in this case, the long-term safety and potential adverse effects of combining lapatinib, trastuzumab, and pertuzumab warrant further investigation. The management of HER2-positive breast cancer with LC remains an area of active research. Additional studies are needed to establish the best treatment protocols, identify predictive biomarkers, and refine therapeutic strategies for this complex clinical scenario [7].

## Conclusion

The treatment of HER2-positive metastatic breast cancer complicated by lymphangitic carcinomatosis represents a challenging clinical scenario. This case report explored the use of a triple HER2-blockade strategy incorporating lapatinib, trastuzumab, and pertuzumab as a novel therapeutic approach. The observed clinical improvements, including reduced dyspnea and improved quality of life, offer hope for patients facing limited treatment options in this complex context. However, it's important to acknowledge the limitations of this case report, such as the small sample size, individual variability, and the need for further research. Larger clinical trials are essential to confirm the efficacy and safety of this triple HER2-blockade regimen in a broader patient population. Despite these limitations, the case underscores the importance of personalized treatment plans tailored to individual patient characteristics and disease stage. It also emphasizes the need for ongoing research to optimize therapies for HER2-positive metastatic breast cancer with lymphangitic carcinomatosis. The combination of lapatinib, trastuzumab, and pertuzumab shows promise, but further investigations are warranted to refine treatment strategies and advance our understanding of this complex clinical scenario. This case report serves as a stepping stone towards improved management of HER2-positive metastatic breast cancer with lymphangitic carcinomatosis, offering a glimmer of hope for patients with few available treatment options.

## Conflict of Interest

None

## Acknowledgment

None

## References

1. Suryadevara A, Paruchuri LP, Banisaeed N, Dunnington G, Rao KA (2010) The clinical behavior of mixed ductal/lobular carcinoma of the breast: A clinicopathologic analysis. *World J Surg Oncol* 28: 51.
2. Brooks DA, Nover BA, Jagtap S, Anjum W, Yegingil H, et al. (2009) Modern Breast Cancer Detection: A Technological Review. *Int J Biomed Imaging* 2009: 902326.
3. Maddams J, Brewster D, Gavin A, Steward J, Elliott J, et al. (2009) Cancer Prevalence in the United Kingdom: Estimates for 2008. *Br J Cancer* 101: 541-547.
4. Zubair M, Wang S, Ali N (2021) Advanced Approaches to Breast Cancer Classification and Diagnosis. *Front Pharmacol* 11: 632079.
5. Gonzalez-Angulo AM, Morales-Vasquez F, Hortobagyi GN (2007) Overview of Resistance to Systemic Therapy in Patients with Breast Cancer. *Adv Exp Med Biol* 608: 1-22.
6. Moqadam SM, Grewal PK, Zahra Haeri, Ingledew PA, Kohli K, et al. (2018) Cancer Detection Based on Electrical Impedance Spectroscopy: A Clinical Study. *J Electr Bioimpedance* 9: 17-23.
7. Bentzen SM, Agrawal RK, Aird EGA, Barrett JM, Barrett-Lee PJ, et al. (2008) The UK standardisation of breast radiotherapy (START) trial A of radiotherapy hypofractionation for treatment of early breast cancer: a randomised trial. *Lancet Oncol* 9: 331-341.