



The Hidden Consequences of Pulmonary Artery Hypertension in a Young Adult: A Case Study with Tb Sequelae

Prof. Srinivas Verma M¹, Dr. Ishani Deshmukh², Dr. Anju Singh Kaurav³ and Dr. Kaushilya Kaurav^{4*}

¹Department of Respiratory Medicine Index Medical College Hospital & Research Centre City Indore, State-Madhya Pradesh, India

²Associate Professor, Department of Respiratory Medicine Index Medical College Hospital & Research Centre City Indore, State-Madhya Pradesh, India

³PG Student, Department of Pathology at Ruxmaniben Deepchand Gardi Medical College Ujjain Charitable Hospital & Research Centre

⁴PG Student II year, Department of Respiratory Medicine Index Medical College Hospital & Research Centre City Indore, State-Madhya Pradesh, India

Abstract

This case study delves into the diagnostic challenges and comprehensive management of a 28-year-old previously healthy young adult who presented with exertional dyspnea, recurrent syncope, chest pain, generalized fatigue, and a history of tuberculosis (TB). After extensive evaluation, the patient was diagnosed with Idiopathic Pulmonary Artery Hypertension (IPAH), compounded by TB sequelae. This rare and life-altering dual diagnosis underscores the importance of early recognition, complex treatment strategies, and improvements in quality of life, genetic considerations, and a multidisciplinary approach to managing IPAH in young adults with TB sequelae. The case also highlights the resilience of individuals facing significant health challenges and emphasizes the need for ongoing research and awareness to improve the care and outcomes of individuals with these serious conditions.

Keywords: Tuberculosis; Genetic; TB sequelae

Introduction

Pulmonary Artery Hypertension (PAH) is a rare and debilitating condition characterized by elevated blood pressure in the pulmonary arteries, leading to increased strain on the right side of the heart. While PAH is more commonly associated with older individuals and those with underlying medical conditions, it can also affect young, otherwise healthy adults. This case study explores the journey of a 28-year-old young adult who presented with a constellation of symptoms ultimately leading to a diagnosis of Idiopathic Pulmonary Artery Hypertension (IPAH), complicated by the sequelae of tuberculosis (TB) (Figure 1).

Case presentation

Patient complaint

A 28-year-old male with no significant medical history presented with a six-month history of exertional dyspnea, recurrent syncope (fainting episodes), chest pain, generalized fatigue, and a past history of treated tuberculosis. These symptoms had been progressively worsening, significantly impacting his daily life and overall well-being.

Diagnostic challenge

The patient's age and history of TB posed a diagnostic challenge. His symptoms were initially attributed to post-TB complications or the sequelae of the infection. However, given their persistence and severity, further evaluation was necessary [1].

Diagnosis: After extensive evaluation, the following dual diagnosis was established:

Idiopathic pulmonary artery hypertension (IPAH): Right heart catheterization confirmed the presence of severe pulmonary artery hypertension, with a mean pulmonary artery pressure significantly exceeding 25 mm Hg at rest. In the absence of other underlying conditions, the patient was diagnosed with IPAH.

Tuberculosis sequelae: Chest imaging revealed evidence of prior TB infection with fibrotic changes in the lung tissue, suggesting the presence of TB sequelae [4].

Investigations

Echocardiography: This imaging study revealed severe right ventricular hypertrophy and dilatation, as well as tricuspid regurgitation, all indicative of the profound impact of PAH on the heart.

Right heart catheterization: Confirming the diagnosis of IPAH and quantifying the severity of pulmonary hypertension, this procedure played a pivotal role in the patient's evaluation [2].

Genetic testing: Given the patient's young age and the potential hereditary nature of PAH, genetic testing was conducted to assess for genetic mutations associated with IPAH.

Treatment

The patient's treatment plan encompassed a multidisciplinary approach, addressing both his physical and emotional well-being.

PAH-specific medications: The patient was initiated on PAH-specific medications aimed at lowering pulmonary artery pressures and improving cardiac function. This included the administration of a prostacyclin analog, Epoprostenol (Flolan), via continuous intravenous infusion, which achieved potent vasodilation in the pulmonary arteries. Additionally, he was prescribed endothelin receptor antagonists like Bosentan (Tracleer) to reduce pulmonary vascular resistance and a phosphodiesterase-5 (PDE-5) inhibitor, Sildenafil (Revatio), to further lower pulmonary artery pressures [3].

***Corresponding author:** Dr. Kaushilya Kaurav, PG Student II year, Department of Respiratory Medicine Index Medical College Hospital & Research Centre City Indore, State-Madhya Pradesh, India, E-mail: kaushilyakaurav@gmail.com

Received: 04-Oct-2023, Manuscript No: jprd-23-115758, **Editor assigned:** 06-Oct-2023, PreQC No: jprd-23-115758 (PQ), **Reviewed:** 18-Oct-2023, QC No: jprd-23-115758, **Revised:** 23-Oct-2023, Manuscript No: jprd-23-115758, **Published:** 30-Oct-2023, DOI: 10.4172/jprd.1000156

Citation: Srinivas Verma M, Deshmukh I, Kaurav AS, Kaurav DK (2023) The Hidden Consequences of Pulmonary Artery Hypertension in a Young Adult: A Case Study with Tb Sequelae. J Pulm Res Dis 7: 156.

Copyright: © 2023 Srinivas Verma M, et al. This is an open-access article distributed under the terms of the Creative Commons Attribution License, which permits unrestricted use, distribution, and reproduction in any medium, provided the original author and source are credited.

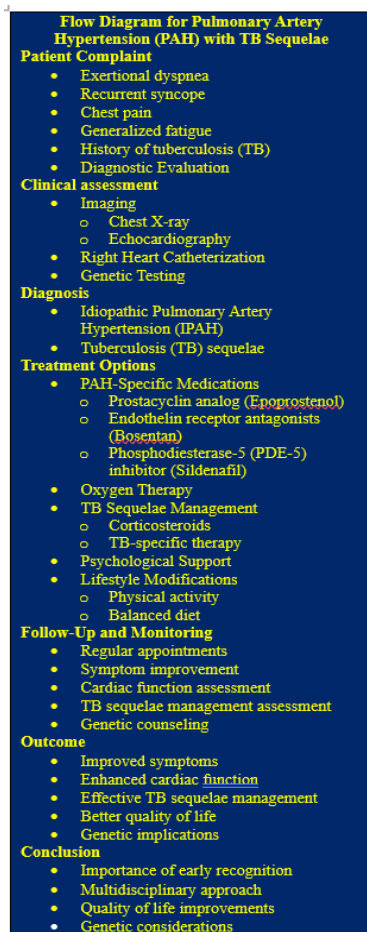


Figure 1: Flow diagram diagnosis of Idiopathic pulmonary artery hypertension (IPAH), complicated by the sequelae of Tuberculosis (TB).

Tb sequelae management: The presence of TB sequelae required ongoing monitoring and management to prevent exacerbations and complications. The patient was prescribed a course of corticosteroids to manage inflammation and fibrotic changes in the lung tissue. Additionally, he received TB-specific therapy for a short duration to ensure that any latent TB infection was effectively treated.

Oxygen therapy

Supplemental oxygen was prescribed to ensure adequate oxygenation, particularly during exertion and sleep, alleviating his symptoms and improving overall oxygen delivery to his tissues.

Physical activity and lifestyle modifications

The patient was encouraged to remain physically active within his limitations and to maintain a balanced diet to support his overall health. These lifestyle adjustments were essential in managing both IPAH and TB sequelae.

Psychological support

Recognizing the emotional toll of a dual diagnosis at a young age, the patient and his family received psychological support to cope with the psychological and emotional aspects of his condition, fostering a more holistic approach to his care.

Regular follow-up

Close monitoring of the patient's clinical status, cardiac function, and response to therapy was carried out through regular follow-up appointments with his healthcare team, ensuring timely adjustments to his treatment plan as needed.

Result

Over the course of treatment and follow-up:

Symptom improvement: The patient experienced a noticeable reduction in exertional dyspnea, chest pain, and syncope. His energy levels improved, enabling him to engage in daily activities more comfortably.

Cardiac function: Follow-up echocardiography revealed a reduction in right ventricular hypertrophy and dilatation, indicating a decreased strain on the right side of his heart and improved cardiac function.

Tb sequelae management: The patient's TB sequelae were effectively managed, with reduced inflammation and fibrotic changes noted in follow-up imaging.

Improved quality of life: The patient's overall quality of life significantly improved as he became accustomed to managing his dual diagnosis and its associated challenges.

Genetic considerations: The patient and his family received genetic counseling to understand the implications of the genetic mutation associated with IPAH, shedding light on the potential risk for other family members.

Conclusion

This case underscores the striking impact of Idiopathic Pulmonary Artery Hypertension on a young adult, further complicated by TB sequelae. It emphasizes several crucial points:

Early recognition: Despite his age and TB history, the presence of PAH must be considered in individuals with exertional dyspnea and syncope, as early diagnosis and intervention are critical.

Complex treatment: The management of IPAH with TB sequelae requires a combination of PAH-specific medications, oxygen therapy, lifestyle modifications, psychological support, and targeted TB management, highlighting the importance of a multidisciplinary approach.

Quality of life: With appropriate treatment and support, young adults like the patient can experience improvements in their symptoms and overall quality of life, even with the added complexity of TB sequelae.

Genetic considerations: Genetic testing and counseling play a crucial role in understanding the genetic basis of IPAH and its potential implications for family members.

This case study exemplifies the resilience of individuals facing significant health challenges and underscores the need for ongoing research and awareness to improve the care and outcomes of individuals with these rare but serious conditions. It highlights the importance of a holistic and multidisciplinary approach to managing complex cardiac conditions like IPAH in young adults with TB sequelae.

Acknowledgement

I extend my gratitude to the dedicated healthcare team, the patient and their family, and the valuable support from my educational

institution, which collectively made this case study possible. Your contributions were invaluable.

References

1. Chatterjee K, Anderson M (2016) Cardiology: An Illustrated Textbook. JP Medical Ltd 12600.
2. Hayes GB (2015) Pulmonary Hypertension: A Patient's Survival Guide. CreateSpace Independent Publishing Platform.
3. Khan FA, Chaudhary A (2019) Idiopathic Pulmonary Arterial Hypertension: A Comprehensive Review. Springer.
4. Wayne LG, Sohaskey SLC (2009) Tuberculosis: A Comprehensive Clinical Reference. ASM Press.