

5 Year-old Boy with a Hearth Murmur and Fever

Riksta Dijkers*, de Vries ACH and Maarten H Lequin

University Medical Center Groningen, Groningen, Netherlands

Abstract

A 5 year old boy was admitted to the emergency ward. Physical examination revealed a heart murmur and fever. During his stay on the emergency ward oxygen saturation progressively worsened. A cardiac ultrasound showed an occlusion of the right pulmonic artery and severe narrowing of the left pulmonic artery. Computed Tomography Angiography (CTA) confirmed the diagnosis. Pathology examination of the retrieved thrombus during emergency thoracotomy revealed a fungus cast from Zygomycete; *Rhizopus microsporus*. The patient was treated with Posaconazole and high dose of liposomal Amphotericin B. The patient was fully recovered forty-five days after admittance to the emergency ward.

Keywords: Pulmonary embolus; Zygomycete; Paediatric; Computed tomography angiography

Case Report

A 5 year old boy was recently diagnosed with Myelodysplastic Syndrome Refractory Cytopenia (MRC), for which bone marrow transplantation was needed. He was admitted to the emergency ward because of fever and a need for oxygen with unknown cause while awaiting the transplantation. Physical examination revealed normal breath sounds and a systolic heart murmur; temperature was 39.8 degrees Celsius. An ultrasound of the heart was performed in the work-up revealing a thrombus filling the right pulmonic artery completely and reducing the lumen of the left pulmonic artery for 80%. A Computed Tomography Angiography (CTA) was performed to confirm the diagnosis and extent of a thrombus in the pulmonic artery. Indeed, diagnosis of an embolus in the pulmonary trunk was confirmed with complete occlusion of the right pulmonic artery and significant obstruction (>75%) of the left pulmonic artery (Figure 1). The thrombus had a low attenuation and did not show any enhancement on the CTA. The pulmonary vascular structures in the right lung showed a smaller calibre compared to the left side. No abnormalities were observed in the lung parenchyma, especially no focal densities or pleural fluid. No atrial and/or ventricular septum defect or persistent ductus Botalli were present. Retrospectively, the plain radiographs of the chest showed an increasing heart size and a reduction of the vascular calibre over the right lung field over the previous few months, suggesting a slow development of the thrombus over time, finally resulting in a progressive occlusion of the pulmonary trunk.

At first the patient was treated with Voriconazol and broad spectrum antibiotics (cotrimoxazol, ciprofloxacin, vancomycin, ceftazidim) because of the high suspicion of an infected thrombus, most probably due to an *Aspergillus* infection.

The patient underwent an emergency thoracotomy on-pump for thrombectomy revealing a brown beige gelatinous thrombus (Figure 2). Postoperatively, the patient was moved to the intensive care unit. No hypothermia was employed postoperatively. Anticoagulation was not initiated because of persistent thrombopenia with bleeding tendency.

Pathology examination revealed branching Y-shaped and 90 degree angle fungus hyphen suspected for angioinvasive fungus (Figure 3). DNA analysis revealed Zygomycete; *Rhizopus microsporus*. Therefore, treatment was changed to Posaconazole (4 × 10 mg/kg per day orally, adjusted depending on blood levels) and high dose of liposomal Amphotericin B (10 mg/kg per day intravenously).

The patient was fully recovered forty-five days after admittance to the emergency ward. He then was transferred from the ICU to another

University Hospital for bone marrow transplantation. Treatment with Posaconazole and liposomal Amphotericin B was continued until bone marrow transplantation had been performed. Prophylactic antibiotics were also continued (cotrimoxazol and ciprofloxacin).

Discussion

Immune compromised patients, such as patients with a haematological malignancy, neutropenia or patients after bone marrow or solid organ transplantation are predisposed to fungal infections. Most commonly these patients develop *Candida* and *Aspergillus* infections. Zygomycosis is a rare opportunistic infection caused by fungi of the Zygomycetes classification. These are fungi belonging to the Mucoraceae family, also known as mucormycosis. Zygomycetes are characterized by the production of a coenocytic (aseptate) vegetative hyphae and the formation of sexual spores in a variety of fungal

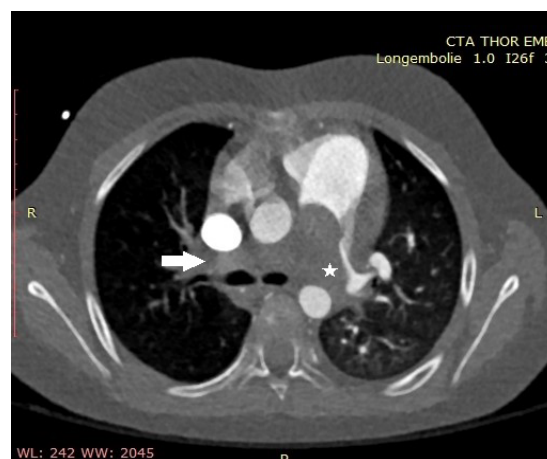


Figure 1: Computed Tomography Angiography showing pulmonic artery.

*Corresponding author: Riksta Dijkers, Department of Radiology, University Medical Center Groningen, Groningen, Netherlands, Tel: 0031503616161; E-mail: r.dijkers@umcg.nl

Received May 09, 2016; Accepted May 25, 2016; Published May 30, 2016

Citation: Dijkers R, de Vries ACH, Lequin MH (2016) 5 Year-old Boy with a Hearth Murmur and Fever. J Pulm Respir Med 6: 351. doi:10.4172/2161-105X.1000351

Copyright: © 2016 Dijkers R, et al. This is an open-access article distributed under the terms of the Creative Commons Attribution License, which permits unrestricted use, distribution, and reproduction in any medium, provided the original author and source are credited.

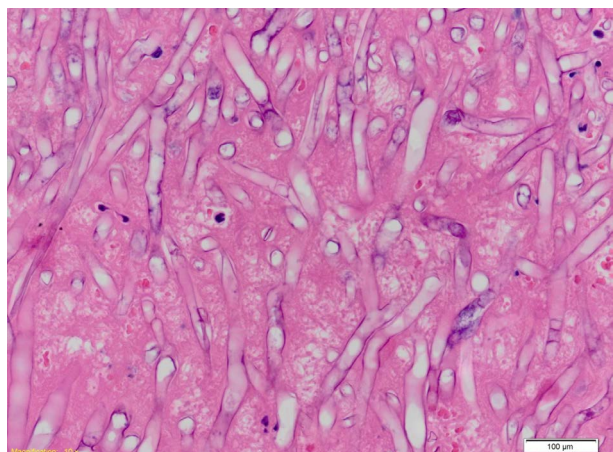


Figure 2: The patient underwent an emergency thoracotomy on-pump for thrombectomy revealing a brown beige gelatinous thrombus.



Figure 3: Pathology examination revealed branching Y-shaped and 90 degree angle fungus hyphen suspected for angioinvasive fungus.

structures [1-3]. Mucormycosis causes an acute angioinvasive infection primarily in immunocompromised patients [3].

The rhino-cerebral form of mucormycosis is most common followed by pulmonary, cutaneous and subcutaneous, gastrointestinal and disseminated form [3,4]. It is transmitted by inhalation, percutaneously or by ingestion of spores. Invasive zygomycosis is associated with angioinvasive disease, which can lead to thrombosis and infarction [5]. Other types of infections that have been described are meningoencephalitis, necrotizing fasciitis and osteomyelitis [6,7].

In neutropenic patients zygomycosis infections can disseminate rapidly and have a fatal course up to 100% [8,9]. The thrombus in our patient was a gelatinous cast of pure fungus almost completely filling the pulmonary trunk. But showed only relatively mild hypoxia. This was probably due to the slow progressive obstruction and changing perfusion of the lung, which also explains the difference in vascular calibre of the lungs. In our opinion, some submillimeter canals, which are not detectable with CTA, might be present through the fungus cast. These submillimetre canals could allow passage of deoxygenated erythrocytes through the thrombus and hence reach alveoli where they can exchange CO₂ and accept O₂. However, we did not perform further experiments to confirm this hypothesis.

Survival rates of zygomycosis are extremely low, both in immune compromised as well as in immune competent patients [7,10,11].

Detection of zygomycosis is difficult because blood cultures, sputum cultures and bronchial washings are seldom positive [12]. Invasive procedures are, therefore, mostly needed for diagnosis. In our patient the invasive thoracotomy was both therapeutic as well as diagnostic. First choice treatment is with Amphotericin B and Posaconazole because of high resistance to Voriconazole. Therefore, in our case therapy was switched from Voriconazole to high dose of Amphotericin B and Posaconazole. However, resistance to the latter drugs may also occur [13].

Conclusion

We showed an unusual case of a patient presenting with fungal infection with a thrombus cast in the pulmonary trunk. Early diagnosis and correct treatment is essential for survival since zygomycetes, although uncommon, are highly fatal and show resistance to the most common anti-fungal drug Voriconazole.

References

1. Kwon-Chung KJ (2015) Taxonomy of Fungi Causing Mucormycosis and Entomophthoromycosis (Zygomycosis) and Nomenclature of the Disease: Molecular Mycologic Perspectives. *Clin Infect Dis* 54: S8-S15.
2. Kwon-Chung KJ (1994) Phylogenetic spectrum of fungi that are pathogenic to humans. *Clin Infect Dis* 19 Suppl 1: S1-7.
3. Alvarez E, Sutton DA, Cano J, Fothergill AW, Stchigel A, et al. (2009) Spectrum of zygomycete species identified in clinically significant specimens in the United States. *J Clin Microbiol* 47: 1650-1656.
4. Bonifaz A, Vázquez-González D, Tirado-Sánchez A, Ponce-Oliviera RM (2012) Cutaneous zygomycosis. *Clin Dermatol* 30: 413-419.
5. van Well GT, van Groeningen I, Debets-Ossenkopp YJ, van Furth AM, Zwaan CM (2005) Zygomycete infection following voriconazole prophylaxis. *Lancet Infect Dis* 5: 594.
6. Auxiliadora-Martins M, Alkmim-Teixeira GC, Machado-Viana J, Nicolini EA, Martins-Filho OA, et al. (2010) Meningoencephalitis caused by a zygomycete fungus (*Basidiobolus*) associated with septic shock in an immunocompetent patient: 1-year follow-up after treatment. *Braz J Med Biol Res* 43: 794-798.
7. Meis JF, Kullberg BJ, Pruszczyński M, Veth RP (1994) Severe osteomyelitis due to the zygomycete *Apophysomyces elegans*. *J Clin Microbiol* 32: 3078-3081.
8. Binder C, Rüchel R (2000) Case report. Mixed systemic mycosis with fatal outcome in a patient with acute myeloblastic leukaemia. *Mycoses* 43: 59-63.
9. Darrisaw L, Hanson G, Vesole DH, Kehl SC (2000) *Cunninghamella* infection post bone marrow transplant: case report and review of the literature. *Bone Marrow Transplant* 25: 1213-1216.
10. van de Glind GJ, Gidding CE, Verlaet CM, Duthoi K, Backx AP, et al. (2010) Acute Cardiac Failure due to Intra-Atrial Mass Caused by Zygomycetes in an Immunocompromised Paediatric Patient. *Case Rep Med* 2010: 241791.
11. Fonollosa A, Segura A, Ruiz-Marcellan C, Diaz J, Garcia-Arumi J (2008) An unusual case of fungal chorioretinitis in an immunocompetent individual. *Ocul Immunol Inflamm* 16: 242-243.
12. Hata DJ, Buckwalter SP, Pritt BS, Roberts GD, Wengenack NL (2008) Real-time PCR method for detection of zygomycetes. *J Clin Microbiol* 46: 2353-2358.
13. Vyzantiadis TA, Kioumi A, Papadakis E, Braimi M, Dermitzakis E, et al. (2009) Rhino-cerebral zygomycosis resistant to antimycotic treatment: a case report. *Mycoses* 52: 87-90.