

A Case of Lung Adenocarcinoma with Metastasis to the Breast

Fatemeh Zahedi and Hoda Mahdavi*

Department of Radiation Oncology, Isfahan University of Medical Sciences, Isfahan, Iran

Abstract

The breast is a rare site of metastasis from cancers that seldom occurs late in the natural history of a malignancy. It causes a diagnostic challenge when it is an early presentation of cancer. Here, we report a case with an incidental breast mass. Further evaluation of the histology revealed a contralateral lung adenocarcinoma. The metastatic deposit of the breast responded well to systemic therapy and therefore the patient was selected for aggressive local therapy of the primary site. The aim of the present study is to report a rare case of metastatic lung adenocarcinoma with limited metastasis that was diagnosed as a non-primary breast neoplasm and was treated with chemotherapy, surgery, and consolidative radiotherapy with a curative intent.

Keywords: Lung adenocarcinoma; Metastasis; Breast neoplasm

Introduction

Lung cancer is the leading cause of adult cancer mortality [1]. Sites of metastasis from non-small cell lung cancers (NSCLC) are commonly liver, brain, kidney, and abdominal lymph nodes, but a variety of different sites of metastasis such as the breast have been reported [2]. The incidence of subclinical or clinical involvement of breasts from known cancers has a range of 0.4% to 6.6% depending on whether hematologic malignancies are included or not [3-5]. The source of metastases to the breast are commonly hematologic malignancies, and melanomas [5-7]. Metastasis from lung adenocarcinoma to the breast is reported frequently in the literature and can mimic triple negative breast cancer, thus for an effective management, careful clinical and pathological differentiations diagnosis is required [8]. Various management strategies are used for stage IV NSCLCs with metastasis. But this condition generally occurs late in the natural history of cancers when curative treatment is not possible. Aggressive local therapy is considered appropriate in selected patients with limited metastases [9] that is potentially curative. Here, a rare case of lung adenocarcinoma with limited metastases to the contralateral breast was treated with a curative intent with combination chemotherapy, surgery, and consolidative radiotherapy. The treatment strategy resulted in a good response but the patient died of lung complications.

Case Report

The case is a 45 years old women who was referred to our clinic with an abnormal breast ultrasonography. Signs for systemic malignancy including respiratory tract, bone or brain symptoms were negative. She did not have any complaints before performing the ultrasonography imaging and did not report feeling lump, or having any abnormal discharge on breast self-examination. She was a known case of systemic lupus erythematosus that was silent and she did not take immune suppressive medication by the time of referral. She also had a history of hyperthyroidism and she was taking thyroid medications. She did not smoke nor consumed alcohol. She had a family history of breast cancer of her sister at age 48 who had received curative treatment. Her ECOG performance status was scored 1 and her physical examination was unremarkable. Her laboratory tests were normal.

The ultrasonography imaging was requested after an abnormal screening and diagnostic mammogram. The imaging demonstrated a hypo-echoic elliptical mass in the upper lateral quadrant of her right breast with a maximum diameter of 25 millimeters with no identifiable pathologic lymph nodes. The radiologist suggested a BIRADS 4a lesion.

She underwent a core needle biopsy from the breast mass that

contained adenocarcinoma with a fairly sharp border from breast tissue. The histology was unusual for primary breast cancer hence an Immunohistochemistry (IHC) examination was performed. Immunostaining for ER, PR, HER-2/neu, GCDFFP-15, CK20, mamoglobin, Calretinin, WT1, CDX2, and thyroglobulin were negative and CK7 was positive nuclear staining for thyroid transcription factor 1 (TTF-1) was strong. Ki67 was positive it about 5% to 10% of the tumor cells. Consequently, the paraffin block was referred for Napsin A staining for the possibility of a lung primary that was positive (Figure 1). A correlation with lung imaging was recommended. A lung CT scan of the patient revealed a 44*30 mm nodule with irregular borders in the upper lobe of the left lung. A CT guided core needle biopsy was performed. The tissue block was referred for EGFR mutation and test result showed deletion in exon 19 of EGFR gene that is interpreted to having good response to TKI inhibitor drugs.

A staging whole body PET-CT scan from the patient was performed that showed the hypermetabolic lung mass, adenopathy of left hilar, left

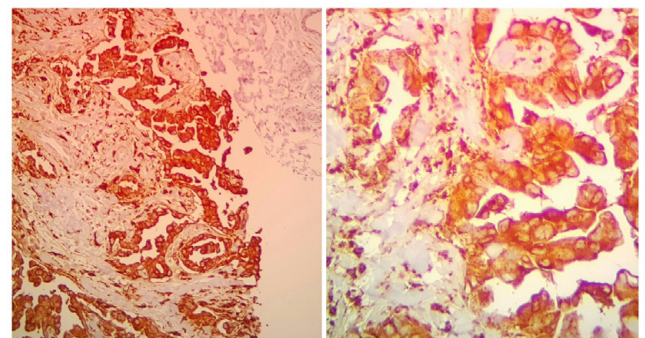


Figure 1: Napsin A diffuse cytoplasmic staining.

*Corresponding author: Hoda Mahdavi, Department of Radiation Oncology, Isfahan University of Medical Sciences, Isfahan, Iran. Tel: +98 31 3792 3071; E-mail: hoda.mahdavi@gmail.com

Received: October 12, 2016; Accepted: January 25, 2017; Published: January 30, 2017

Citation: Zahedi F, Mahdavi H (2017) A Case of Lung Adenocarcinoma with Metastasis to the Breast. *Oncol Cancer Case Rep* 3: 122.

Copyright: © 2017 Zahedi F, et al. This is an open-access article distributed under the terms of the Creative Commons Attribution License, which permits unrestricted use, distribution, and reproduction in any medium, provided the original author and source are credited.

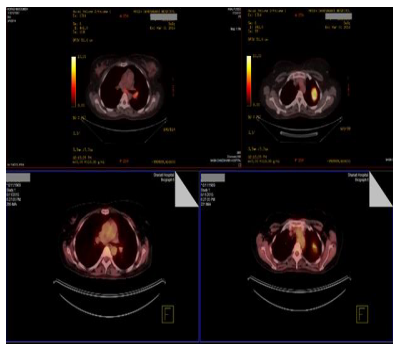


Figure 2: PET-CT scans of the patient at the beginning (above) and at end of combination chemotherapy (below).

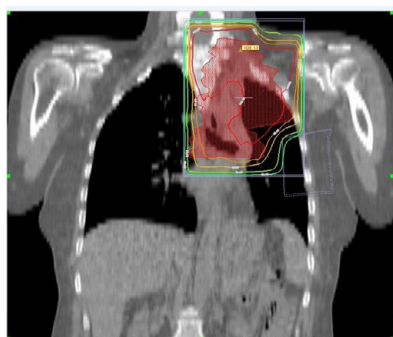

Figure 3: A coronal section of the post-operative external beam radiotherapy plan.

sub carinal, left mediastinal, and left supraclavicular lymph nodes. An FDG avid soft tissue density inside the right breast was also evident. No other metastatic sites were indicated. The tumor was clinically staged as T2aN3M1b (Stage IV).

The patient received chemotherapy with Erlotinib and Bevacizumab and response to treatment was inspected with PET-CT imaging with 3-4 month intervals. 9 months after initiating the treatment there were no traces of breast mass uptake on PET-CT but lymph nodes of lung hilum and mediastinum were still metabolically active. Chemotherapy was continued with the same regimen. After another 4 months PET-CT showed stable disease of the lung (Figure 2). The disease responded well to chemotherapy thus a surgical consultation was requested to evaluate the possibility of a curative surgery that was approved by the thoracic surgeon. No treatment for the breast was recommended. The upper left lobe of the lung and mediastinal lymph nodes were dissected and pathology revealed a central mass of moderately differentiated adenocarcinoma with a maximum diameter of 3 cm. The 2 hilar and 3 paraesophageal lymph nodes were free from tumoral involvement. A focal cartilage destruction was reported inside the resected specimen but distant from the tumoral mass and was considered a secondary change. A multidisciplinary decision suggested local conformal chemoradiation. The radiotherapy plan delivered 59 grays/31 fractions to the tumor bed and 45 grays/25 fractions to hilar, mediastinal, and supraclavicular nodes. The mean dose to the combined lung was 20.1 Gys, V5=27%, and V20 was calculated 20% that was acceptable (Figure 3). The patient received concurrent Erlotinib with radiotherapy. The patient had esophagitis symptoms while receiving radiotherapy but symptomatic management was effective. She was fine in short follow up after completion of the radiotherapy and 4 weeks later Bevacizumab

was started as maintenance therapy. After 3 weeks from restarting Bevacizumab the patient arrived to the emergency with massive hemoptysis. She deteriorated rapidly and ultimately died.

Discussion

Metastasis from cancers of non-breast origin is not usually expected because there is a general concept that fibrous areas of the breast tissue have deprived blood supply. In contrary metastasis to the breast has been reported quite often. Most cases are reported in younger women and therefore has been linked to effects of estrogen on stroma and vascularity of the breast parenchyma. However, no clear predisposing factors have been identified for metastases to the breast. Since 1965 to 2014, 94 NSCLC tumors with metastasis to the breast are reported in the literature that included 30 cases of lung adenocarcinomas [4,5,8,10]. Metastasis to the breast is supposed to have poor prognoses [11]. Late hematogenous dissemination [11], and lymphatic dissemination from nodes of the mediastinum, supraclavicle, and intercostal regions are described as routes for metastasis from lungs to ipsilateral breasts. Retrograde spreading from the pleural space has also been hypothesized but not proven [12]. This typically presents as a painless solitary mass and mimics an early stage breast cancer. Hence, systemic assessment is not performed unless there is a high suspicion from clinical and pathological data [13]. Two thirds of cases of NSCLC metastasis to the breast presented metachronously and most were ipsilateral to the lung primary [7,12]. This case had a synchronous, contralateral breast metastasis at presentation, not very late in her natural history.

Metastatic lesions to the breast appear with a variety of unspecific radiologic findings, and cannot be easily differentiated from benign lesions [11,14]. Metastatic deposits to the breast are described as sharply circumscribed lesions from normal tissue in pathologic examination and lack elastosis, however, adenocarcinomas lack specific histological features [15]. Nevertheless, specific IHC staining helps for making a correct diagnosis and avoids an unnecessary breast surgery [11-13].

Metastases to the breast from lung cancer are all hormone receptor negative with a few exceptions. GCDPF-15 is expressed in 45% to 53% of breast carcinomas and 5.2% to 15% of lung adenocarcinomas. mammaglobin stains positive in 48% to 72.1% of adenocarcinomas of the breast but is negative in lung adenocarcinomas. TTF-1 is a well-established specific biomarker indicating a lung cancer primary and is positive in 68% to 80% of lung adenocarcinomas [7,15,16]. The combination of Napsin-A and TTF-1 staining raises the specificity for diagnosing lung adenocarcinoma and makes differentiation from thyroid, breast and other adenocarcinomas and lung malignancies [17,18]. This staining was used as a complimentary tool for diagnosis.

Stage IV NSCLC has a poor prognosis with an estimated 5-year survival of 6% to 7%. Treatment of stage IV lung cancer is based on systemic chemotherapy with a palliative intent in patients with acceptable performance, with or without radiotherapy. Surgery is not usually chosen unless the primary tumor remains indolent in its course [7]. Oligometastasis is relatively common in NSCLC and had an incidence of 26% to 55% in clinical studies. This entity may have a more favorable outcome [19-21]. It is not clear if the observed prolonged survival is due to treatment of all metastasis or the indolent nature of the disease [22]. Patients with good performance status, long disease free intervals and limited metastasis may be selected for curative treatment. Synchronous metastasis is among the factors that are associated with worse survival [23]. In reported cases of metastasis to the breast management strategies were not uniform in terms of the selected treatment modality and systemic drug combinations. A review

indicated that 36% of reported cases received chemotherapy alone. Twenty percent of the patients received chemotherapy in addition to surgery and 20% had received radiotherapy of the lung primary in their treatment course [7]. Reported cases of metastasis to the breast from lung primary survived around 2 months from diagnosis [11] and about 80% of patients with breast metastasis from the lung died within the first year [13]. There have been reports of long term survival from metachronous breast metastasis from adenocarcinoma of the lung after management with a curative intent [24].

Few reports of EGFR mutated cases of lung adenocarcinomas with metastasis to the breast have been described and one case had a rapid and objective response of the primary and metastatic breast lesion to Aftinib, a TKI drug [8]. Our case received a combination of Erlotinib and bevacizumab that is identified superior to single agent Erlotinib in terms of progression free survival, but has a higher risk of grade 3 and 4 bleeding complications [25]. This combination was initially tolerated well and metabolically active lesions of the breast responded completely to chemotherapy. However, the patient eventually developed hemoptysis and died with a pattern of respiratory failure 31 months from the initial diagnosis.

Conclusion

Metastases from lung adenocarcinomas to the breasts are rare but lung adenocarcinomas can metastasize to almost any organ. It seems crucial to adhere to recommendations for differentiating primary adenocarcinomas from metastatic lesions that leads to an effective treatment. Furthermore, conditions of limited metastases that can be managed with curative intent as well as selection of drug combinations and treatment modalities should also be defined. This report suggests that an aggressive local therapy with newer combination chemotherapy agents can result in a good response. However, in selected patients with advanced lung cancer aggressive local therapy may be indicated after trading off the treatment outcome against complications of therapy.

References

- Forman D, Ferlay J, Stewart B, Wild C (2014) The global and regional burden of cancer. *World cancer report* 16-53.
- Quint LE, Tummala S, Brisson LJ, Francis IR, Krupnick AS, et al. (1996) Distribution of distant metastases from newly diagnosed non-small cell lung cancer. *The Annals of thoracic surgery* 62: 246-250.
- Bohman L, Bassett L, Gold R, Voet R (1982) Breast metastases from extramammary malignancies. *Radiology* 144: 309-312.
- Amichetti M, Perani B, Boi S (1990) Metastases to the breast from extramammary malignancies. *Oncology* 47: 257-260.
- Lee SH, Park JM, Kook SH, Han BK, Moon WK (2000) Metastatic tumors to the breast: Mammographic and ultrasonographic findings. *J Ultrasound Med* 19: 257-262.
- Vergier B, Trojani M, De Mascarel I, Coindre JM, Le Treut A (1991) Metastases to the breast: Differential diagnosis from primary breast carcinoma. *J Surg Oncol* 48: 112-116.
- Mirrieles JA, Kapur JH, Szalkucki LM, Harter JM, Salkowski LR, et al. (2014) Metastasis of primary lung carcinoma to the breast: a systematic review of the literature. *J Surg Res* 188: 419-431.
- Dansin E, Carnot A, Servent V, Daussay D, Robin YM, et al. (2015) EGFR-Mutated Breast Metastasis of Lung Adenocarcinoma: A Case Report. *Case Rep Oncol* 8: 164-168.
- Ettinger DS, Wood DE, Akerley W, Bazhenova LA, Borghaei H, et al. (2016) NCCN guidelines insights: Non-small cell lung cancer. *J Natl Compr Canc Netw* 14: 255-264.
- Nielsen M, Ørnvold K, Andersen Ja, Henriksen Fw, Kristensen Pb, et al. (1981) Metastases to the breast from extramammary carcinomas. *Acta Pathol Microbiol Scand A* 89: 251-256.
- Vizcaino I, Torregrosa A, Higuera V, Morote V, Cremades A, et al. (2001) Metastasis to the breast from extramammary malignancies: A report of four cases and a review of literature. *Eur Radiol* 11: 1659-1665.
- Huang HC, Hang JF, Wu MH, Chou TY, Chiu CH (2013) Lung adenocarcinoma with ipsilateral breast metastasis: A simple coincidence? *J Thoracic Oncol* 8: 974-979.
- Babu KS, Roberts F, Bryden F, McCafferty A, Downer P, et al. (2009) Metastases to breast from primary lung cancer. *J Thoracic Oncol* 4: 540-542.
- Paulus D, Libshitz H (1982) Metastasis to the breast. *Radiologic Clinics of North America* 20: 561-568.
- Maounis N, Chorti M, Legaki S, Ellina E, Emmanouilidou A, et al. (2010) Metastasis to the breast from an adenocarcinoma of the lung with extensive micropapillary component: A case report and review of the literature. *Diagn Pathol*. 5: 1.
- Park SY, Kim BH, Kim JH, Lee S, Kang GH (2007) Panels of immunohistochemical markers help determine primary sites of metastatic adenocarcinoma. *Arch Pathol Lab Med* 131: 1561-1567.
- Turner BM, Cagle PT, Sainz IM, Fukuoka J, Shen SS, et al. (2012) A new marker for lung adenocarcinoma, is complementary and more sensitive and specific than thyroid transcription factor 1 in the differential diagnosis of primary pulmonary carcinoma: Evaluation of 1674 cases by tissue microarray. *Arch Pathol Lab Med* 136: 163-171.
- Zhu B, Dalal S, Kamp DW, Lin X (2014) Warranting investigation of primary lung adenocarcinoma in patients with an extrapulmonary malignancy and lung nodules due to high frequency. *Am J Clin Pathol* 141: 429-436.
- Rusthoven KE, Hammerman SF, Kavanagh BD, Birtwhistle MJ, Stares M, et al. (2009) Is there a role for consolidative stereotactic body radiation therapy following first-line systemic therapy for metastatic lung cancer? A patterns-of-failure analysis. *Acta Oncol* 48: 578-583.
- Yano T, Okamoto T, Haro A, Fukuyama S, Yoshida T, et al. (2013) Local treatment of oligometastatic recurrence in patients with resected non-small cell lung cancer. *Lung cancer* 82: 431-435.
- Parikh RB, Cronin AM, Kozono DE, Oxnard GR, Mak RH, et al. (2014) Definitive primary therapy in patients presenting with oligometastatic non-small cell lung cancer. *Int J Radiat Oncol Biol Phys* 89: 880-887.
- Yano T, Haro A, Yoshida T, Morodomi Y, Ito K, et al. (2010) Prognostic impact of local treatment against postoperative oligometastases in non-small cell lung cancer. *J Surg Oncol* 102: 852-855.
- Ashworth AB, Senan S, Palma DA, Riquet M, Ahn YC, et al. (2014) An individual patient data meta-analysis of outcomes and prognostic factors after treatment of oligometastatic non-small-cell lung cancer. *Clin Lung Cancer* 15: 346-355.
- Yoon MY, Song CS, Seo MH, Kim MJ, Oh TY, et al. (2010) A case of metachronous metastasis to the breast from non-small cell lung carcinoma. *Cancer Res Treat* 42: 172-175.
- Kato T, Seto T, Nishio M, Goto K, Atagi S, et al. (2014) Erlotinib plus bevacizumab (EB) versus erlotinib alone (E) as first-line treatment for advanced EGFR mutation-positive non-squamous non-small cell lung cancer (NSCLC): An open-label randomized trial. *ASCO Annual Meeting Proceedings*.