

# A Novel Mutation of the PEX16 Gene in a Patient with Slowly Progressive Zellweger Syndrome

Melike Ersoy<sup>1\*</sup>, Burak Tatlı<sup>2</sup> and Serdar Ceylaner<sup>3</sup>

<sup>1</sup>Department of Pediatrics, Division of Pediatric Metabolism, Bakirkoy, Dr. Sadi Konuk Education and Research Hospital, Istanbul, Turkey

<sup>2</sup>Department of Pediatrics, Division of Pediatric Neurology, Istanbul Medical Faculty, Istanbul, Turkey

<sup>3</sup>Intergen Genetics Center, Ankara, Turkey

## Abstract

Zellweger syndrome (ZS) disorders are autosomal recessive peroxisomal biogenesis diseases mainly characterized by neonatal onset severe neurodevelopmental delay, profound hypotonia, craniofacial dysmorphism, hepatic dysfunction, polyneuropathy and loss of hearing and vision. There is a wide genetic heterogeneity that while most ZS disorders are rapidly progressive and incurable, and patients rarely survive through their first birthday, many patients have late-onset and mild ZS phenotypes. Human PEX16 is an integral membrane protein first isolated by Honsho and plays a central role in peroxisomal membrane biogenesis. According to the few existing reports, the severity and the natural course of PEX16-mutated patients are unclear, and therapy has not been discussed. Herein and based on existing research, we report and discuss the case of a young female diagnosed with slowly progressive ZS involving a novel PEX16 mutation.

**Keywords:** Zellweger syndrome; PEX16 gene; Peroxisomal biogenesis diseases; Very long-chain fatty acids; Docosahexaenoic acid

## Introduction

The peroxisome is a single-membrane-bound organelle containing enzymes that catalyze various metabolic pathways, including the  $\beta$ -oxidation of very long-chain fatty acids (VLCFAs), the synthesis of ether lipids, such as plasmalogens, and bile acid metabolism [1]. Peroxisomes are formed through two distinct pathways: the growth and fission of mature peroxisomes and de-novo synthesis at the endoplasmic reticulum (ER) [2]. Inborn errors of peroxisomes are classified into two broad categories: peroxisome biogenesis disorders (PBDs) and single enzyme deficiencies [3,4].

Traditionally, PBDs include: Zellweger (cerebrohepato)renal syndrome (ZS), the most severe phenotype; neonatal adrenoleukodystrophy (NALD), the phenotype with intermediate severity; and infantile Refsum disease (IRD), the least severe phenotype. PBDs are caused by mutations of PEX genes involved in the biogenesis and the function of peroxisomes and are characterized by deficiencies of multiple peroxisomal enzymes and, in some cases, by the absence of or the reduction in the number of peroxisomes. Mild-to-severe and early-to-late presentations, due to genetic heterogeneity, are observed in patients with PBDs [5-7].

Peroxisomes may form through two pathways: one pathway involves the PEX11-mediated division of pre-existing peroxisomes, and the other pathway involves the PEX16-mediated formation of peroxisomes in the absence of pre-existing peroxisomes. PEX16 expression allows for the synthesis of peroxisomes from phospholipids and matrix proteins [8] (Figure 1).

Human PEX16 is an integral membrane protein believed to function at endoplasmic reticulum and first act upon the peroxisomal membrane assembly. Honsho et al. [9] isolated the human PEX16 cDNA, which encoded a peroxisomal protein containing 336 amino acids. Together, PEX3, PEX16, and PEX19 constitute an important set of peroxins generally referred to as the early peroxins because of their essential roles in the initial steps of peroxisome biogenesis [10] (Figure 2). Moreover, PEX16 seems to play a key role as a receptor responsible for the integration of peroxins (PEX3 and PEX19) into the ER.

For many other inherited metabolic diseases, disease severity is thought to be related to the nature of the gene mutation and its

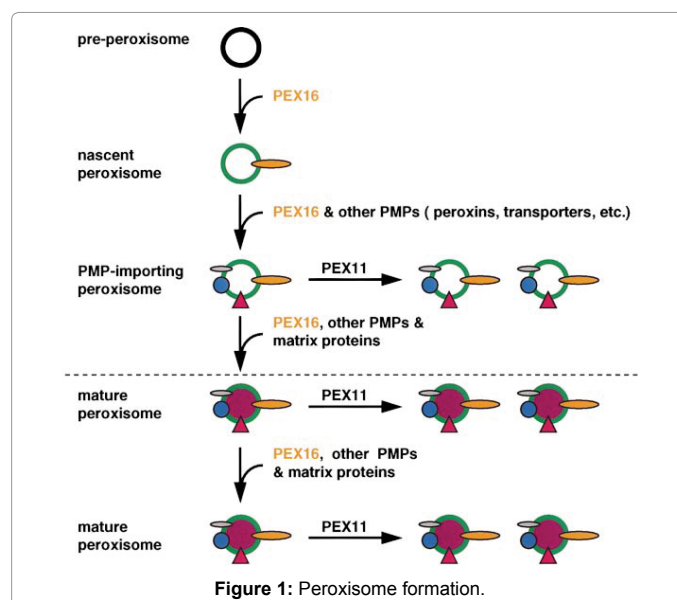


Figure 1: Peroxisome formation.

resulting impact on protein function. Similarly, ZS results from defects in peroxins, and its severity could be related to the nature of the PEX gene mutation and the resulting impact on peroxin function [10,11].

In an unprecedented case, a patient with a PBD had a homozygous nonsense mutation in the PEX16 gene [9]. The identified cases were published in early reports of PEX16-defective patients with severe clinical presentations [12]. However, recently reported cases showed

**\*Corresponding author:** Melike Ersoy, Department of Pediatrics, Division of Pediatric Metabolism, Bakirkoy, Dr. Sadi Konuk Education and Research Hospital, Istanbul, Turkey, Tel: +90 212 414 75 11; E-mail: [zeynepcey@hotmail.com](mailto:zeynepcey@hotmail.com)

**Received** July 08, 2016; **Accepted** August 13, 2016; **Published** August 20, 2016

**Citation:** Ersoy M, Tatlı B, Ceylaner S (2016) A Novel Mutation of the PEX16 Gene in a Patient with Slowly Progressive Zellweger Syndrome. J Clin Case Rep 6: 854. doi: [10.4172/2165-7920.1000854](https://doi.org/10.4172/2165-7920.1000854)

**Copyright:** © 2016 Ersoy M, et al. This is an open-access article distributed under the terms of the Creative Commons Attribution License, which permits unrestricted use, distribution, and reproduction in any medium, provided the original author and source are credited.

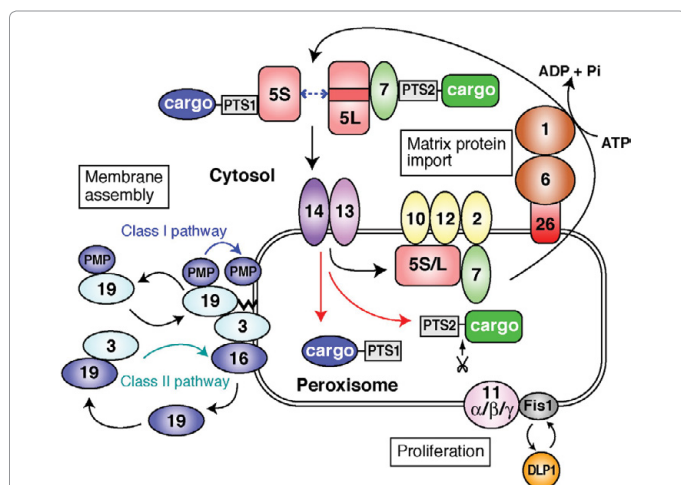


Figure 2: Function of PEX16, PEX3, and PEX19 in the peroxisome pathway.

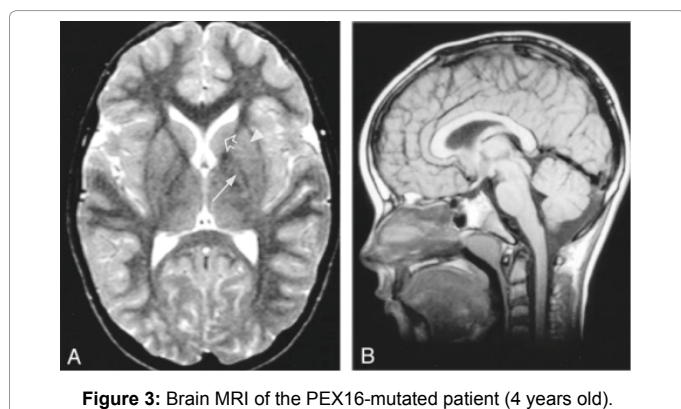


Figure 3: Brain MRI of the PEX16-mutated patient (4 years old).

a nearly identical mild and slowly progressive clinical course [13-15]. Here, we report the clinical presentation, disease course and therapy in a slowly progressive female ZS patient with a novel PEX16 gene mutation.

### Case Report

The patient, a two-year-old Turkish female, presented with mild neuromotor retardation and walking difficulty when admitted to the hospital. She is the first child of consanguineous parents. She was born at term by caesarean section after an uncomplicated pregnancy; birth weight was 3100 g. She showed normal development for the first year of life but then stopped acquiring new skills and lost her ability to walk independently at 24 months due to spasticity and mild ataxia. Except for three-fold elevated transaminase levels, her biochemistry was normal. Lipid levels were at low-normal levels. At follow-up, the transaminases failed to function normally. Speech and other cognitive functions deteriorated slowly over time. At 4 years of age, she developed nystagmus, hyperreflexia, clonus, and extensor plantar responses. At 5 years old, she developed progressive dysarthria with involuntary movements, such as tremors and abnormal head-eye saccades. Excitement or fear amplified these observed clinical presentations. Bilateral symmetric axonal sensorimotor polyneuropathy was determined by electromyography. A brain MRI showed widespread white matter changes on a background pattern of global delay in myelin maturation and cerebral atrophy (Figure 3). Peripheral nerve velocity studies of the lower limbs also suggested demyelination and peripheral

and central nervous system involvement. However, metabolic screening studies showed only mild abnormalities, such as mildly increased VLCFAs. PEX genes including PEX16 gene sequence analysis was performed by using the MiSeq next generation sequencing (NGS) platform, an FDA-approved diagnostic system (Illumina, San Diego, CA, USA). We found a novel (c.953-1\_974del23ins5) homozygous mutation in the PEX16 gene, which causes a splicing defect. After analyzing this variation with the human splicing finder software, we inferred that it could be responsible for a severe splicing alteration. This defect is an indel mutation, and its effects span the final nucleotide of the intron 10 to the first nucleotides of exon [11]. This gene domain is necessary for interacting with PEX19. The patient received supportive therapy, starting with 30 mg/kg/day docosahexaenoic acid (DHA, 22:6 $\omega$ 3). At the end of 18 months, neuromotor examination and MRI findings remained unchanged, though notably, elevations in VLCFAs remained at low levels.

### Discussion

Although further clarification will be required, PEX16 is essentially involved in peroxisome biogenesis [16]. The published cases of PEX16 mutations show different clinical signs with different severities. Ebberink et al. identified 5 different homozygous mutations in the PEX16 gene from 6 patients, including 2 siblings, with a relatively mild form of ZS that were characterized by early-childhood onset of progressive spastic paraparesis and ataxia with progressive leukodystrophy and brain atrophy on brain MRI [12,13].

A floppy female newborn with generalized paucity of limb movements and hyporeflexia was examined by Salpietro et al. [17]. She had liver and cardiac involvement and coarse facial features, including a flattened, wide nasal bridge and a high arched palate. She lacked effective suckling and required a nasogastric feeding tube. Brain MRI at 2 months revealed a generally reduced bulk of white matter and underdevelopment of the inferior cerebellar vermis. She also presented with mitochondrial dysfunction. Plasma VLCFAs levels were elevated, thereby supporting the ZS diagnosis. The infant died at 8 months after progressive deterioration of her cardiac, respiratory and neurological functions.

The 25 patients with cerebellar and/or vermis atrophy in childhood, who were not diagnosable solely by clinical examination, were diagnosed using whole exome sequencing by Ohba et al. [14]. A one-year-old patient had compound heterozygous PEX16 mutations.

Using exome sequencing, Bacino et al. [15] identified an 18-year-old male patient with a progressive neurodegenerative phenotype that had a homozygous PEX16 mutation, suggesting an atypical ZS presentation. This patient's peroxisomal biochemical abnormalities were subtle, such that plasma VLCFAs initially failed to provide a diagnosis. This case suggests that VLCFA levels could be an insufficient marker for the disease.

To our knowledge, the patient described herein is the first PEX16-mutated ZS case with a novel mutation and an atypical mild slowly progressive phenotype, including solely elevated VLCFAs levels, brain white matter abnormalities and polyneuropathy; thus, these observations support the claim that the identified PEX16 mutations can cause a relatively mild phenotype [16,17].

Furthermore, because of defective myelination (hypodemyelination), which could represent one of the clinical factors responsible for ZS, our patient has been supplemented with DHA. This therapy could prolong patient lifespan and quality of life in these types

of mild and slowly progressive ZSs [18]. Although DHA treatment may not halt ZS progression, administering DHA in these slowly progressive ZS patients could prove useful.

## Conclusion

According to published research, patients with PEX16 gene mutations do not possess a unique phenotype. Despite the small number of reported cases, the generalized, expected severe clinical course is not a consistent phenotype in PEX16-mutated patients. Current evidence does not support a correlation between genotype and phenotype. However, the mild and slowly progressive types of ZS can be difficult to diagnose with routine analysis, and they may require genetic evaluation. DHA administration for mild phenotypes could be a supportive therapeutic choice.

## References

1. Waterham HR, Ebberink MS (2012) Genetics and molecular basis of human peroxisome biogenesis disorders. *Biochim Biophys Acta* 1822: 1430-1441.
2. Kim PK, Mullen RT (2013) PEX16: a multifaceted regulator of peroxisome biogenesis. *Front Physiol* 4: 241.
3. van den Bosch H, Schutgens RB, Wanders RJ, Tager JM (1992) Biochemistry of peroxisomes. *Annu Rev Biochem* 61: 157-197.
4. Wanders RJ, Waterham HR (2006) Biochemistry of mammalian peroxisomes revisited. *Annu Rev Biochem* 75: 295-332.
5. Sacksteder KA, Gould SJ (2000) The genetics of peroxisome biogenesis. *Annu Rev Genet* 34: 623-652.
6. Steinberg SJ, Dodt G, Raymond GV, Braverman NE, Moser AB, et al. (2006) Peroxisome biogenesis disorders. *Biochim Biophys Acta* 1763: 1733-1748.
7. Wanders RJ, Waterham HR (2005) Peroxisomal disorders I: biochemistry and genetics of peroxisome biogenesis disorders. *Clin Genet* 67: 107-133.
8. Weller S, Gould SJ, Valle D (2003) Peroxisome biogenesis disorders. *Annu Rev Genomics Hum Genet* 4: 165-211.
9. Honscho M, Tamura S, Shimozawa N, Suzuki Y, Kondo N, et al. (1998) Mutation in PEX16 is causal in the peroxisome-deficient Zellweger syndrome of complementation Group D. *Am J Hum Genet* 63: 1622-1630.
10. Schliebs W, Kunau WH (2004) Peroxisome membrane biogenesis: the stage is set. *Curr Biol* 14: R397-399.
11. Crane DI, Maxwell MA, Paton BC (2005) PEX1 mutations in the Zellweger spectrum of the peroxisome biogenesis disorders. *Hum Mutat* 26: 167-175.
12. Honscho M, Hiroshige T, Fujiki Y (2002) The membrane biogenesis peroxin Pex16p. Topogenesis and functional roles in peroxisomal membrane assembly. *J Biol Chem* 277: 44513-44524.
13. Ebberink MS, Csanyi B, Chong WK, Denis S, Sharp P, et al. (2010) Identification of an unusual variant peroxisome biogenesis disorder caused by mutations in the PEX16 gene. *J Med Genet* 47: 608-615.
14. Ohba C, Osaka H, Iai M, Yamashita S, Suzuki Y, et al. (2013) Diagnostic utility of whole exome sequencing in patients showing cerebellar and/or vermis atrophy in childhood. *Neurogenetics* 14: 225-232.
15. Bacino C, Chao YH, Seto E, Lotze T, Xia F, et al. (2015) A homozygous mutation in PEX16 identified by whole-exome sequencing ending a diagnostic odyssey. *Mol Genet Metab Rep* 5: 15-18.
16. Kim PK, Mullen RT, Schumann U, Lippincott-Schwartz J (2006) The origin and maintenance of mammalian peroxisomes involves a de novo PEX16-dependent pathway from the ER. *J Cell Biol* 173: 521-532.
17. Salpietro V, Phadke R, Saggari A, Hargreaves IP, Yates R, et al. (2015) Zellweger syndrome and secondary mitochondrial myopathy. *Eur J Pediatr* 174: 557-563.
18. Martinez M, Ichaso N, Setien F, Durany N, Qiu X, et al. (2010) The 4-desaturation pathway for DHA biosynthesis is operative in the human species: differences between normal controls and children with the Zellweger syndrome. *Lipids Health Dis* 9: 98.