

Babesiosis as a Male Infertility Risk Factor

Ali Shalizar Jalali^{1*} and Bijan Esmaeilnejad²

¹Department of Basic Sciences, Faculty of Veterinary Medicine, Urmia University, Urmia, Iran

²Department of Pathobiology, Faculty of Veterinary Medicine, Urmia University, Urmia, Iran

Editorial

Babesiosis as an emerging zoonotic disease is caused by infection with hemoparasites of the protozoan genus *Babesia* which are the second most common blood-borne parasites of mammals after the trypanosomes [1]. *Babesia*, the first recognized arthropod-borne pathogen of vertebrates, was discovered originally by the Romanian bacteriologist Victor Babeş as a cause of febrile bovine hemoglobinuria or red water fever at the end of the 19th century [2].

The first case of human babesiosis has been reported in 1957 near Zagreb, Croatia in a splenectomized young farmer and subsequently several *Babesia* species have been documented to involve in human infections in United States, Europe, China, Taiwan, Korea, Japan, India, Egypt, South Africa, Brazil and Mexico [3-10]. Up to now, over 100 species of *Babesia* have been recorded, infecting many mammalian and some avian species making this disease a global health threat [11].

It is well known that hemolytic anemia as a major clinical manifestation of this infection progression can lead to blood supply disruption, tissue hypoxia and eventually cell death [12]. Moreover, erythrocytes adherence to the microvasculature endothelium can also lead to excessive pro-inflammatory cytokine release and intensification of tissue hypoxia [13]. It is noteworthy to mention that blood reperfusion can also result in cell membrane damages and tissue devastation through reactive oxygen species over-generation and neutrophil infiltration [14,15]. Also, it should be borne in mind that activated neutrophils play critical roles in reactive oxygen species, proteases and elastases production resulting in endothelial cell dysfunctions and injuries as well as microvasculopathies [16]. Additionally, hemolysis and hemolytic anemia associated iron overload in tissues can augment oxidative damages, demolish essential macromolecules and exacerbate cytopathies [17].

On the other hand, it is well established that blood flow reduction is associated with testicular germ cell degeneration as well as spermatogenesis impairment [18]. It was also found that testicular ischemia induced oxidative stress triggers leukocyte activation causing increased microvascular permeability, edema and parenchymal cell death [19,20]. Further, hemolytic anemia-induced free iron concentration increase may also lead to testicular failure and male infertility [21].

In line with that, previous reports have shown that experimental babesiosis evoked hemolytic anemia causes remarkable histostructural disorganizations along with functional disorders in the rats' liver and kidney [22]. Furthermore, it has been revealed that experimental *Borrelia crocidurae* inoculation leads to pre- and post-capillary blood vessels blockage in rats' testicular tissue and causes testicular seminiferous tubules damages *via* disruption of normal testicular

blood flow [23]. Accordingly, previous epidemiological reports have implied that higher rates of protozoan parasitic infections in infertile patients can highlight the non-negligible association of protozoan parasitic diseases and fertility disorders [24,25].

On the whole, it seems that *Babesia* infection as a male infertility risk factor can lead to spermatogenesis disturbances and orchopathy (Figure 1) probably through testicular microcirculatory disruption and blood flow reduction along with oxidative stress, inflammatory reactions and germ cells apoptosis induction. Accordingly, comprehensive universal programs are urgently needed to promote general awareness about the hidden features of babesiosis and manage this emerging infectious zoonosis.

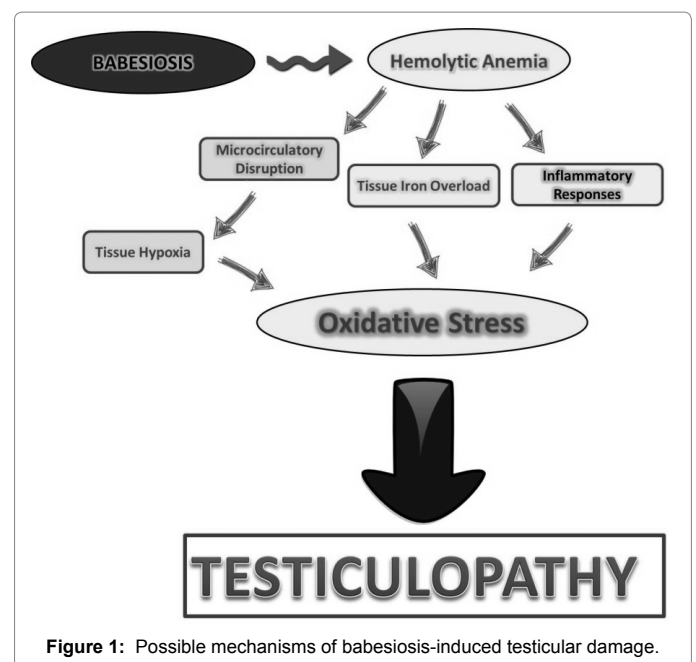


Figure 1: Possible mechanisms of babesiosis-induced testicular damage.

*Corresponding author: Ali Shalizar Jalali, Histology and Embryology Research Laboratories, Department of Basic Sciences, Faculty of Veterinary Medicine, Urmia University, Urmia, Iran, Tel: 00984431942593; Fax: 00984432771926; E-mail: a.shalizar@urmia.ac.ir

Received August 16, 2017; Accepted September 08, 2017; Published September 15, 2017

Citation: Jalali AS, Esmaeilnejad B (2017) Babesiosis as a Male Infertility Risk Factor. J Vet Med Health 1: e101.

Copyright: © 2017 Jalali AS, et al. This is an open-access article distributed under the terms of the Creative Commons Attribution License, which permits unrestricted use, distribution, and reproduction in any medium, provided the original author and source are credited.

References

1. Hunfeld KP, Hildebrandt A, Gray JS (2008) Babesiosis: recent insights into an ancient disease. *Int J Parasitol* 38: 1219-1237.
2. Nelson DA, Bradley JK, Arya R, Ianosi-Irimie M, Marques-Baptista A, et al. (2009) Babesiosis as a rare cause of fever in the immunocompromised patient: a case report. *Cases J* 2: 7420.
3. Skrabalo Z, Deanovic Z (1957) Piroplasmosis in man; report of a case. *Doc Med Geogr Trop* 9: 11-6.
4. Gorenflot A, Moubri K, Precigout E, Carcy B, Schetters TP (1998) Human babesiosis. *Ann Trop Med Parasitol* 92: 489-501.
5. Bush JB, Isaacson M, Mohamed AS, Potgieter FT, de Waal DT (1990) Human babesiosis - a preliminary report of 2 suspected cases in South Africa. *S Afr Med J* 78: 699.
6. Michael SA, Morsy TA, Montasser MF (1987) A case of human babesiosis (preliminary case report in Egypt). *J Egypt Soc Parasitol* 17: 409-410.
7. Shih CM, Liu LP, Chung WC, Ong SJ, Wang CC (1997) Human babesiosis in Taiwan: asymptomatic infection with a *Babesia microti*-like organism in a Taiwanese woman. *J Clin Microbiol* 35: 450-454.
8. Kim JY, Cho SH, Joo HN, Tsuji M, Cho SR, et al. (2007) First case of human babesiosis in Korea: detection and characterization of a novel type of *Babesia* sp. (K01) similar to ovine babesia. *J Clin Microbiol* 45: 2084-2087.
9. Saito-Ito A, Tsuji M, Wei Q, He S, Matsui T, et al. (2000) Transfusion-acquired, autochthonous human babesiosis in Japan: Isolation of *Babesia microti*-like parasites with hu-RBC-SCID mice. *J Clin Microbiol* 38: 4511-4516.
10. Marathe A, Tripathi J, Handa V, Date V (2005) Human babesiosis - a case report. *Indian J Med Microbiol* 23: 267-269.
11. Levine ND (1988) Progress in taxonomy of the Apicomplexan protozoa. *J Protozool* 35: 518-520.
12. Vannier E, Gewurz BE, Krause PJ (2008) Human babesiosis. *Infect Dis Clin North Am* 22: 469.
13. Krause PJ, Daily J, Telford SR, Vannier E, Lantos P, et al (2007) Shared features in the pathobiology of babesiosis and malaria. *Trends Parasitol* 12: 605-610.
14. Jalali AS, Behfar M, Najafi G, Nourian A, Shahkarimi M, et al. (2016) The suppressive effects of simvastatin on fertility impairment induced by experimental unilateral testicular ischemia-reperfusion in mice. *Caspian J Reprod Med* 2: 11-15.
15. Wei SM, Yan ZZ, Zhou J (2009) Curcumin attenuates ischemia-reperfusion injury in rat testis. *Fertil Steril* 91: 271-277.
16. Lee VM, Quinn PA, Jennings SC, Ng LL (2003) Neutrophil activation and production of reactive oxygen species in pre-eclampsia. *J Hypertens* 21: 395-402.
17. Lesnefsky EJ (1994) Tissue iron overload and mechanisms of iron-catalyzed oxidative injury. *Adv Exp Med Biol* 366: 129-146.
18. Wei SM, Yan ZZ, Zhou J (2011) Protective effect of rutin on testicular ischemia-reperfusion injury. *J Pediatr Surg* 46: 1419-1424.
19. Collard CD, Gelman S (2001) Pathophysiology, clinical manifestations, and prevention of ischemia-reperfusion injury. *Anes* 94: 1133-1138.
20. Jalali AS, Behfar M, Nourian A (2016) Testicular torsion treatment as a male reproductive health concern. *J Trauma Treat* 5: 329.
21. Piperno A, Rivolta MR, D'Alba R, Fargion S, Rovelli F, et al. (1992) Preclinical hypogonadism in genetic hemochromatosis in the early stage of the disease: evidence of hypothalamic dysfunction. *J Endocrinol Invest* 15: 423-428.
22. Hamoda AF, Radwan M, Rashed R, Amin A (2014) Toxic effect of babesiosis in cattle and chemotherapeutic treatment in Egypt. *Am J Infect Dis Microbiol* 2: 91-96.
23. Shamaei-Tousi A, Collin O, Bergh A, Bergström S (2001) Testicular damage by microcirculatory disruption and colonization of an immune-privileged site during *Borrelia crociduræ* infection. *J Exp Med* 193: 995-1004.
24. Shiadeh MN, Niyati M, Fallahi S, Rostami A (2016) Human parasitic protozoan infection to infertility: a systematic review. *Parasitol Res* 115: 469-477.
25. Martínez GF, Regadera J, Mayer R, Sanchez S, Nistal M (1996) Protozoan infections in the male genital tract. *J Urol* 156: 340-349.