

## Be Pointed Study of the Relation of Molar and Incisors Hypomineralization Incidence in Patients of Ehlers-Danlos

Ana Paula Penitente<sup>1</sup>, Idirberto Jose Zotarelli Filho<sup>1,2\*</sup>, Taylane Soffener Berlanga de Araújo<sup>1,2</sup>, Fábio Pereira Linhares de Castro<sup>1,2</sup>, Maira Regina De Souza<sup>1</sup>, Andreia Borges Scriboni<sup>1</sup> and Elias Naim Kassir<sup>1,2</sup>

<sup>1</sup>Department of Odontology, University Center North Paulista, Brazil

<sup>2</sup>Department of Regenerative Medicine and Tissue Engineering, Universidade Estadual Paulista, Brazil

### Abstract

The hypomineralization is a pathology that has great clinical relevance, where the affected dental enamel presents areas of discoloration, with higher fracture risk, high risk caries and high sensitivity. The aim of work was to perform a survey of possible carriers of Ehlers-Danlos syndrome (EDS), through the Beighton test, which is attributed to a heterogeneous group of genetic amendments of the structure and collagen synthesis and connective tissue and be able to associate the relationship the incidence of MIH in this group. Because it is known that collagen is of paramount importance to dental development, and if occurs the interference by addition of destructive agents in their midst this will inhibit tooth morphogenesis. As the diagnostic of this syndrome in childhood is very difficult because children are more flexible, associate the detection of the presence of MIH may alert the investigation of Ehlers-Danlos syndrome, demonstrating the severity of structural anomalies, in this manner the early treatment can improve the quality of life of this population group.

**Keywords:** Ehlers-danlos; Hypomineralization; Collagen; Connective tissue

### Introduction

About 30% of adults are considered to have Joint Hypermobility [1]. The prevalence of hypermobility varies with age, gender, ethnicity and genetic factors, multifactorial. Women have a greater joint mobility, however, such mobility decreases with age [2-5]. Hereditary connective tissue diseases may be associated with Down's syndrome, Ehlers-Danlos (EDS) and Marfan [6]. The overall presentations of all types of EDS are about 1 in 5000 births worldwide [7].

The Molar and Incisor Hypomineralization (MIH) is considered a major clinical problem in northern Europe, this continent studies show that the prevalence varies from 3.6 to 25% [8]. Other continents also conducted studies to determine the magnitude of this condition in their populations in America was observed 40.2%, Asia 2.8% and Africa 13.7%. Studies in Brazil, specifically in Araraquara, the prevalence of MIH were 12.3% and Rio de Janeiro / Brazil the prevalence was 40.2% [9].

Viral infections (maternal rubella), some diseases that interfere with calcium metabolism (hypothyroidism, hypoparathyroidism and uncontrolled maternal diabetes) and hemolytic disease of the newborn can cause enamel defects, systemic order. A careful clinical examination is very important for the dentist to reach the correct diagnosis because the knowledge of dental enamel defects may contribute to the overall health of the patient [10].

Joint hypermobility is an important variable to be associated with oral evaluation of children. Children in preschool age (5 and 6 years) are mobile or even hypermobile by age, which can give a false positive diagnosis of EDS. However, at this age begins the eruption of permanent teeth and the presence of MIH can be indicative for early confirmation of the EDS, together with Beighton tests, making the surgeon dentist a very important supporting aiding in the detection of Ehlers Danlos [11].

The individual with excessive increase in joint mobility undergoes changes in your muscle strength and body posture. Monitoring the evolution of joint hypermobility in childhood and adolescence through longitudinal studies are needed to establish the resolution period of the

problem, since this period is prolonged or excessive may cause postural changes, pain and injury [12].

This work aims to carry out a quantitative survey of cases of MIH in possible carriers Ehlers Danlos, to prove the incidence of poor dental training in this group of society. For hypothesized that if the association is evident from these diseases may be known in the phase which initiated the process and thus facilitating the HA treatment and subsequent child's quality of life.

### Methods and Study Design

We conducted a literature review of current articles initially selected by the following criteria: articles available in full in electronic databases, Library Bireme Library of Medicine (PUBMED/MEDLINE) and Search Engine (Google). The literature search was performed from January to August 2014 was used to refine the search the following keywords: Ehlers Danlos hypomineralization, Collagen, Tissue.

Was held intraoral clinical examination to assess the presence of MIH, this test is only observational, which was conducted in 124 patients aged 6 to 17 in the city of Monson SP, besides this examination was performed the Beighton test to establish the EDS diagnosis or not. The data collected were recorded in clinical records and statistically evaluated by quantitative parametric test of Fisher, to see if this dental deformity is truly related to the syndrome.

**\*Corresponding author:** Idirberto José Zotarelli Filho, Department of Odontology, University Center North Paulista, Street Ipiranga, 3460, São José do Rio Preto SP, 15020-040, Brazil, Tel: +55 17 98166-6537; E-mail: [m.zotarelli@gmail.com](mailto:m.zotarelli@gmail.com)

**Received:** April 23, 2015; **Accepted:** June 05, 2015; **Published:** June 09, 2015

**Citation:** Penitente AP, Filho IJZ, Araújo TSBD, Linhares de Castro FP, De Souza MR, et al. (2015) Be Pointed Study of the Relation of Molar and Incisors Hypomineralization Incidence in Patients of Ehlers-Danlos. J Interdiscipl Med Dent Sci 3: 179. doi: [10.4172/2376-032X.1000179](https://doi.org/10.4172/2376-032X.1000179)

**Copyright:** © 2015 Penitente AP, et al. This is an open-access article distributed under the terms of the Creative Commons Attribution License, which permits unrestricted use, distribution, and reproduction in any medium, provided the original author and source are credited.

Subjects were divided into four different groups, where the GRI were placed young people who responded positively to 4 or more points of Beighton test in GR II young people considered not hypermobile, i.e., less than 4 points of hypermobility; in GR III young people were selected with joint hypermobility and who also had HIM and GR IV non-hypermobile but with MIH.

As the diagnosis of EDS in children is difficult due to high mobility they have, be able to associate a risk factor for further analysis in the diagnosis of Ehlers Danlos syndrome result in better quality of life for patients, and the detection of malformations tooth may be indicative for early diagnosis.

## Results

How to diagnose the syndrome in children is very difficult because children are more flexible, involve detecting the presence of IMH may alert the research Ehrls- Danlos syndrome, demonstrating the severity of structural abnormality, thus early treatment can- improving the quality of life of this population group. The Beighton score is a valid measure for joint hypermobility, based on detailed analysis of the range of motion of all major joints. Although Beighton score was shown to increase mobility in other joints is present does not apply in the test.

Thus, the result, of the 124 young Evaluated with the Beighton test and intra oral examination for molar and incisor hypomineralization (MIH), 57 male and 67 were female. The hypermobile index flexibly presented in this work high incidence, According to Table 1 and Figure 1. Thus, the MIH is present in more sedianos female, not showing the same factor in men, with this way need for more research to prove the incidence of MIH is related to Ehrlens-Danlos Syndrome (EDS) (Figures 1 and 2, Table 1).

As the diagnosis of EDS in children is difficult due to high mobility they have, be able to associate a risk factor for further analysis in the diagnosis of Ehlers Danlos syndrome result in better quality of life for patients, and the detection of malformations tooth may be indicative for early diagnosis.

## Discussion

Since 2001, MIH is attributed to an interruption in ameloblástica function throughout the period of transition and maturation of Amelogenesis [13-15]. The MIH involves one to four first permanent molars may be associated with permanent incisors also affected. There are several factors that can cause damage to ameloblasts, such as nutritional deficiencies (vitamins A, C and D), fever and exanthematous diseases (measles, chicken pox and scarlet fever), congenital syphilis, hypocalcemia (in this case, hypoplasia is related to the occurrence of tetany, caused by low calcium level in the blood), trauma at birth, too much fluoride and idiopathic factors. Many clinical studies have shown that even with careful history and withdrawals in some cases the enamel hypoplasia are of unknown origin [16].

In general it can be stated that any nutritional deficiency or severe systemic disease may be capable of producing enamel hypoplasia, since

Groups (GR)	N° Participants	Qualification EDS
GR I	13	Hypermobile
GR II	84	Not Hypermobile
GR III	12	Hypermobile with MIH
GR IV	15	Not hypermobile with MIH

• MIH = Molar and Incisor Hypomineralization; EDS = Ehlers – Danlos Syndrome

Table 1: Number of individuals evaluated in this study.

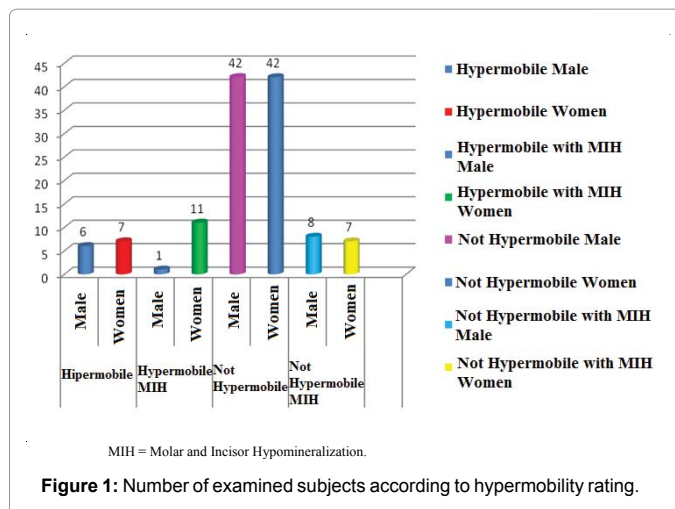


Figure 1: Number of examined subjects according to hypermobility rating.

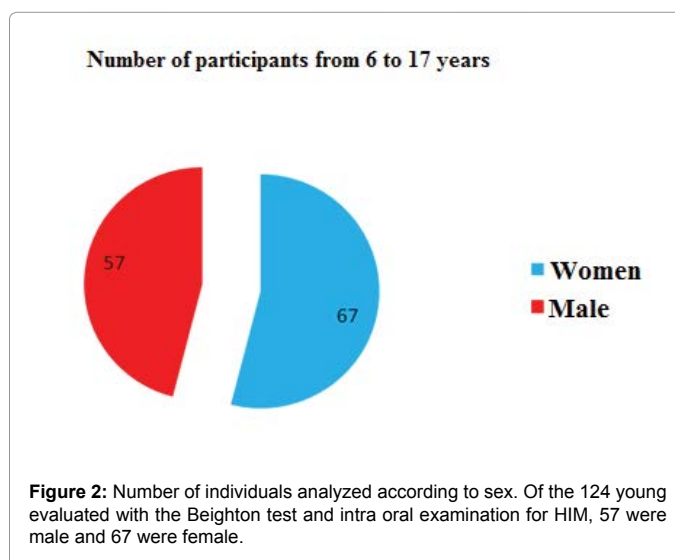


Figure 2: Number of individuals analyzed according to sex. Of the 124 young evaluated with the Beighton test and intra oral examination for HIM, 57 were male and 67 were female.

the ameloblasts are among the most sensitive cell groups of the body with respect to metabolic function. However, enamel hypoplasia only appears if the injury occurs at the time when the teeth are developing, or more specifically, during enamel formation phase [7]. The enamel hypoplasia caused by systemic diseases often occurs. The type and shape of the dysplasia are dependent on the state of development of the affected teeth, as well as the time duration (acute or chronic) and the intensity influence [17].

In the classic type, patients have joint hypermobility; extremely fragile, soft, hyperextensibility skin, scars hemosiderotic, Pseudotumors and skin. In the case study light microscopy revealed normal thickness skin with collagen fibers loosely organized and rare organized packages, Elastic tissue was present and disorganized. According to Bonato [18] reveals that tooth enamel is remodeladora origin, and that once formed is continuously recorded after changes in its surface during its formation. Further, defective training in Bonato defines as dental hypoplasia, which may be genetic, environmental, and systemic or local.

In the study by Roberts et al. [19], were studied 41 patients with source 72 orthopedic diseases. This study aimed to determine the need

for morbidity, the orthopedic point of view shows the EDS, the study lasted five years, the patients studied were all treated in outpatient orthopedic and trauma pediatric hospital José Martí, Sancti Spiritus, Cuba between July 2001 and July 2006, with a diagnosis of EDS; the frequency was close to 1.7 illnesses per patient without significant predominance of females. One of the most important perinatal history was the presence of various degrees of hip dysplasia [20].

The existence of other orthopedic conditions was not significant. At the end of the investigation were included 41 patients who met the eligibility criteria. Skin biopsy was done in 3 cases, by light microscopy, which showed the predominant involvement as reducing the quantity and disorganization of the fiber bundles and the incidence of EDS was higher in women than in men (24 of 41 patients).

According to Bravo [21], collagen form the extracellular matrix, one of its features is to give strength to the tissues. Hereditary disorders affect collagen production that affect the skeletal muscle, and other organs. The EDS is one of the inherited changes in collagen production.

In studies Létourneau et al. [22], patients with EDS have extraoral manifestations such as, presence of scar on his chin and forehead, a history of repeated dislocations of ATM, epicanthal folds, hypertelorism, narrow curved nose, thinning hair and hypermobility of the skin. Further, Ferreira et al. [23] stated that sedianos beyond similar orofacial characteristics such as narrow jaw, midface hypoplasia, present fragility of the oral mucosa, high canines, and deep occlusal fissures in premolars and molars, and periodontitis [24].

According to Oliveira in the Brazil the average rate of permanent teeth decayed, missing and filled - PTD in a given population for children 12 years old in 2010 was 2.8, parallel, some students record a higher PTD in children with enamel defects [25,26]. According to Arun et al. [27], the oral manifestation associated with hypermobility syndrome may include the absence of lip frenula and lower lingual, fragile oral mucosa, periodontal defects, malformation in the anatomy of the tooth crown dental fractures, lacerations roots or stunted, aberrant dentinal tubules, vascular lesions and pulp denticles, hypermobility of the temporomandibular joint and ready movement of teeth in response to orthodontic treatment [28,29].

Based on study Létourneau et al. [22], explains that the radiographic examination often reveals pulp narrowing and short and deformed roots. The language is very flexible. Approximately 50% of people with the syndrome can touch the end of your nose with your tongue (Gorlin's sign), compared to 8-10% of the population. The palate is commonly vaulted. Therefore, according to Bicca et al. [30], collagen is a structural protein found in large quantities in all animals; the central pathogenesis of Ehlers-Danlos syndrome results from defects in collagen, wherein the disorder results in different frame EDS. It comprises a group of inherited connective tissue disorders characterized by hypermobility. Further, according to Bravo [21], which describes the EDS diagnosis may be suspected by the presence of recurrent and significant bruising, tendon rupture, sprains and subluxation of the fingers hypermobility, typical face, and especially in organs break history family.

Based on Gonçalves [31] established a research aimed to survey the prevalence of molar and incisor hypomineralization (MIH) and knowledge of possible etiologic factors, consisted of 108 children of the third and fourth year of Antonio Feijo Grouping schools located in Ponte de Lima. We conducted observations intra - oral, and a questionnaire mothers, children observed 7.4% had MIH, the prenatal period was no case of MIH, and the peri-natal period had 6 cases of MIH, post - Christmas 8 cases of MIH, completing the research that

children with medical problems in the first four years of life and took antibiotics have a higher possibility of MIH, is the most common problem in the post - natal period, requiring further studies [32].

By Létourneau et al. [22] the oral examination is of great importance in establishing a diagnosis of EDS. The dentist should perform treatment observing precautions appropriate for the condition of patients with EDS. Therefore, according to Crisóstomo et al. [33], the pathophysiology of EDS is a dysfunction in collagen synthesis, causing defects in this process as both the structure and secretion of this protein. Collagen fibers in the dermis may be disorganized and elastic fibers present irregularities in size and orientation.

Pérez [34] reports that collagen plays an important role in dental development, since it is interrupted can stop tooth morphogenesis. Ribeiro et al. [35] report that dental tissue is composed of collagen matrix of organic and inorganic calcium salts. According to Lopes [36], the ameloblasts are enamel-forming cells in the tooth germ that are extremely sensitive to stimuli, factors that contribute to enamel defects. These by Gonçalves [31] describes be precursor to obtain a hypoplastic enamel.

Based on Lopes [37] conducted a study aimed to investigate the prevalence of hypomineralization molar incisor in a group of students in the age group of 6 to 12 years of municipal schools of the city of Manacapuru [38,39]. The study was conducted in 5 municipal schools of the city of Manacapuru - Amazonas - Brazil, A total of 1820 children were examined and 28 cases of MIH were identified. The prevalence of MIH, this group of children was 1.53%, a total of 96 teeth were affected. The average number of teeth in children affected with MIH was 3.42; of which 72.91% were the first permanent molars and 27.08% permanent incisors. Completing a low percentage, and may have been due to the high number of missing teeth, decayed and restored in these children of Manacapuru, or the peculiar socio-cultural characteristics of the region, for example, low air pollution.

According to Sadashivamurthy et al. [40], developmental enamel defects are generally prevalent, afflicting more than 10% of the population, with several consequences, including dental pain, imperfect morphogenesis and increased risk of caries. In studies of Crombie et al. [41], estimates of the prevalence of MIH vary in the literature, it varies within 3-50% in the general population according to studies. These variations may reflect a lag in indices reviews and standardized methodology to diagnose MIH.

## Conclusion

It follows that the hypermobile index flexibly performed in high incidence and the MIH is present in more sedianos female, not showing the same factor in males. Thus, it is necessary more research to prove that the incidence of MIH is in fact related to EDS.

## Acknowledgement

The work was financially supported by the Unipos of Sao Jose do Rio Preto - Brazil. We appreciate the support of Famerp and Base Hospital of Sao Jose do Rio Preto - Brazil, also Duke University (Durham, NC, USA) in the field of research and statistical studies.

## References

1. Hakim AJ, Cherkas LF, Grahame R, Spector TD, MacGregor AJ (2004) The genetic epidemiology of joint hypermobility: a population study of female twins. *Arthritis Rheum* 50: 2640-2644.
2. Cavenaghi S, Folchine AER, Marino LHC, Lamari NM (2006) Prevalência de hipromobilidade articular e sintomas algícos em trabalhos industriais. *Arq ciênc saúde* 13: 66-70.

3. Lamari N, Marino LC, Cordeiro JÁ, Pellegrini AM (2007) Flexibilidade anterior do tronco adolescente após o pico da velocidade de crescimento em estatura. *Acta ortop Bras* 15: 25-29.
4. De Paiva TM, da Silva TCD (2009) A correlação entre hiper mobilidade articular e escoliose idiopática em mulheres. *Fisioter Mov Curitiba* 22: 77-85.
5. Santos EBP, Patrocínio SS (2010) Impacto da hiper mobilidade articular no gasto energético e na resistência ao exercício físico.
6. Verd Vallespir S, Mas de Salva J, Arboleda González L (1991) [Joint hypermobility in Palma school children]. *An Esp Pediatr* 35: 17-20.
7. Rodríguez GNG, Jorge ML, Castillo TP, Cabello JLL (2008) Síndrome de Ehlers Danlos, uma Ortopedia Pediátrica? *Pediatr Rev Cubana Havana* 80.
8. Basso AP, Ruschel HC, Gatterman A, Ardentghi TM (2007) Hipomineralização molar-incisivo- Revisão de Literatura. *Revista Odonto Ciênc, Porto Alegre* 22: 371-376.
9. Jeremias F (2010) Hipomineralização molar-incisivo:prevalência, severidade e etiologia em escolares de Araraquara. *Dissertação (Mestrado)*.
10. Ribas AO, Czylusniak GD (2004) Anomalias do Esmalte Dental: etiologia, diagnóstico e tratamento. *Publ. UEPG Ci. Biol. Saúde, Ponta Grossa* 10: 23-36.
11. Cavenaghi S, Marino LH, Oliveira PP, Lamari NM (2009) Joint hypermobility in patients with mitral valve prolapse. *Arq Bras Cardiol* 93: 307-311.
12. Neves JCJ, Cibinello FU, Vitor LGV, Beckner D, Siqueira CPCM, et al. (2013) Prevalência de hiper mobilidade articular em crianças pré-escolares. *Fisioter Pesq* 20: 158-164.
13. Gonçalves SBF (2011) Hipomineralização Incisivo Molar: Prevalência e Etiologia. Trabalho de conclusão de curso. Universidade Fernando Pessoa, Porto.
14. Brusco CL, Brusco CHE, Ruschel CH, Kramer FP (2008) Amelogenese imperfeita – cinco anos de acompanhamento. *RFO* 13: 60-64.
15. Couto FCA, Pupin AM, Dias AM, Dande VJ, Barbosa D, et al. (2012) Amelogenese imperfeita: revisão da literature. *Revista Eletrônica Acervo Saúde* 1: 34-40.
16. Shafer WG, Hine MK, Levy BM (1987) Distúrbios do Desenvolvimento das Estruturas Bucais e Parabucais. In: *Tratado de Patologia Bucal*. 4ed. Rio de Janeiro: Guanabara Koogan Cap 1: 02-79.
17. Waes HJM, Stöckl PW (2002) Odontopediatria. Porto Alegre. *Artmed* 385.
18. Bonato BVV (2010) Hipoplasia Dental: Revisão de Literatura, Trabalho de conclusão de curso. Universidade Federal do Rio Grande do Sul, Porto Alegre.
19. Rodríguez GNG, León JM, Castillo PT, Cabelo LLL (2008) Síndrome de Ehlers Danlos, uma Ortopedia Pediátrica Clínicos em Subregister *Pediatr Rev Cubana Havana* 80.
20. Vieira TR, Péret ACA, Filho LAP (2010) Alterações periodontais associadas às doenças sistêmicas em crianças e adolescentes. *Rev Paul Pediatr* 28: 237-243.
21. Bravo SJ (2008) Síndrome de Ehlers-Danlos Vascular (sedv), Antes Llamado Sed tipo IV, *Revista Chilena de Reumatología* 24: 6-11.
22. Létourneau Y, Pérusse R, Buihieu H (2001) Oral manifestations of Ehlers-Danlos syndrome. *J Can Dent Assoc* 67: 330-334.
23. Ferreira JO, Cardoso LC, Capelozza ALA, Faria R, Costa AR (2008) Odontogenic keratocyst and Multiple Supernumerary Teeth in a Patient With Ehlers-Danlos Syndrome--a Case Report and Review of the Literature. *Quintessence International* 39: 251-256.
24. Maldonado BV, Silva PGWF, Filho N, Queiroz MA (2010) Características Clínicas da Osteogênese Imperfeita do Tipo I e da Dentinogênese Imperfeita, *Pediatria, Faculdade de Odontologia de Ribeirão Preto da Universidade de São Paulo, Ribeirão Preto* 32: 223-230.
25. de Moraes AD, Baptista CA, Crippa JAS, Junior PL (2011) Tradução e validação do the five part questionnaire for identifying hypermobility para a língua portuguesa do brasil. *Rev bras Reumatol* 51: 1.
26. Oliveira GMV (2012) Impacto da hipomineralização molar-incisivo (hmi) e da cárie dentária na qualidade de vida de escolares de 8 a 12 anos no município de patrocínio paulista – SP. *Dissertação apresentada à Universidade de Franca, como exigência parcial para obtenção do título de Mestre em Promoção de Saúde*.
27. Arun T, Nalbantgil D, Sayinsu K (2006) Orthodontic treatment protocol of Ehlers-Danlos syndrome type VI. *Angle Orthod* 76: 177-183.
28. Domingues AA (2013) Estudo de Prevalência de Sinais e Sintomas de Disfunções Temporomandibulares em Praticantes de Ginástica Rítmica.
29. Smits-Engelsman B, Klerks M, Kirby A (2011) Beighton score: a valid measure for generalized hypermobility in children. *J Pediatr* 158: 119-123.
30. Bicca Ede B, Almeida FB, Pinto GM, Castro LA, Almeida Jr HL (2011) Classical Ehlers-Danlos syndrome: clinical, Histological and ultrastructural aspects. *An Bras Dermatol* 86: S164-S167.
31. Gonçalves SBF (2011) Hipomineralização Incisivo Molar: Prevalência e Etiologia. Trabalho de conclusão de curso. Universidade Fernando Pessoa, Porto.
32. Passos AI, Costa CMDJ, Melo MJ, Forte SDF, Sampaio CF (2007) Defeitos do esmalte: etiologia, características clínicas e diagnóstico Diferencial. *Rev Inst Ciênc Saúde* 25: 187-192.
33. Crisóstomo RM, Gondim, TJV, Benevides NA, Crisóstomo RM, Pessoa PGS (2010) Cervicoplastia na flacidez cutânea po síndrome de ehlers-danlos: relato de caso. *Rev Bras Cir Plást* 25: 556-558.
34. Pérez RJ (2010) Estudio y Prevalencia de los Defectos de Desarrollo del Esmalte em Población Infantil Granadina, Universidad de Granada, Facultad de Odontología, departamento de Estomatología, Granada.
35. Ribeiro GR, Marchesan AM, Silva GR, Neto SM, Pecora DJ (2010) Permeabilidade Dentinária do Terço Apical em Diferentes Grupos de Dentes. *Braz Dent J* 21.
36. Lopes RB (2010) Hipomineralização Molar-Incisivo em Crianças de Manacapuru – AM. Instituto de Ciências da Saúde – FUNORTE/SOEBRAS – Monografia - (Especialização em Odontopediatria) - Instituto de Ciências da Saúde – FUNORTE/SOEBRAS Núcleo Manaus.
37. Lopes DO, Pacheco JBC, Mangione JA, Reis MB (2005) Síndrome de Ehlers-Danlos Associada a Anomalias de Artérias Pulmonares e Sistêmicas. *Revista Brasileira Ecocardiografia* 18: 63-68.
38. Fernandes AS, Mesquita P, Vinhas L (2012) Hipomineralização Incisivo Molar: Uma Revisão da Literatura. *Revista Portuguesa de Estomatologia* 53: 258-62.
39. Jeremias F (2010) Hipomineralização molar-incisivo: prevalência, severidade e etiologia em escolares de araraquara. *dissertação apresentada ao programa de pós- graduação em ciências odontológicas, da faculdade de odontologia de araraquara, da universidade estadual paulista, para o título de mestre em ciências odontológicas; Araraquara*.
40. Sadashivamurthy P, Deshmukh S (2012) Missing links of Molar Incisor Hypomineralization: A review. *J. Int Oral Health* 4: 1-11.
41. Crombie FA, Manton DJ, Weerheijm KL, Kilpatrick NM (2008) Molar incisor hypomineralization: a survey of members of the Australian and New Zealand Society of Paediatric Dentistry. *Aust Dent J* 53: 160-166.

**Citation:** Penitente AP, Filho IJZ, Araújo TSBD, Linhares de Castro FP, De Souza MR, et al. (2015) Be Pointed Study of the Relation of Molar and Incisors Hypomineralization Incidence in Patients of Ehlers-Danlos. *J Interdiscipl Med Dent Sci* 3: 179. doi: [10.4172/2376-032X.1000179](https://doi.org/10.4172/2376-032X.1000179)