

Blood-Fluid level: A Sign of Oral Anticoagulant-Associated Intracerebral Hemorrhage in a Patient with Ischemic Stroke

Ismail Ibrahim Ismail*

Department of Neurology, IbnSina Hospital, Sulaibikhat Area, Shuwaikh Industrial Area, 90003, Kuwait

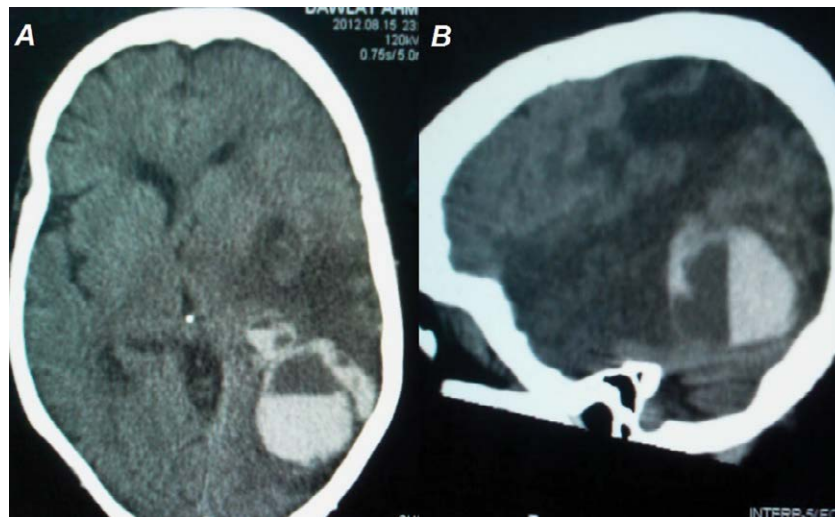


Figure 1: Non-enhanced CT Brain; (A) Axial view showing left temporo-parietal infarction complicated with ICH, mass effect and showing the classic sign of "Blood/fluid level". (B) Coronal view.

Keywords: Blood/fluid level; Sedimentation; Anticoagulant; Hemorrhage; Stroke

Description

A 65 year-old female patient with past medical history of diabetes mellitus, hypertension and ischemic heart disease presented with acute onset of right hemiplegia, right facial palsy and dysphasia. Urgent CT brain showed hypodensity involving the territory of the lower division of left middle cerebral artery denoting recent infarction. On admission the patient was found to have Atrial Fibrillation (AF) and LMW Heparin was started followed by Warfarin. One week after initiation of Warfarin the patient started to have headache, increased weakness with deterioration of the level of consciousness. Urgent NECT brain was done and showed hemorrhagic transformation, mass effect and "Blood-fluid level" (Figure 1). Her international normalized ratio (INR) was 3.5.

"Blood/fluid level" or "Sedimentation level" represents interface between the plasma and sedimented blood and is defined radiologically as presence of area of low computed tomography (CT) attenuation above and high CT attenuation below a discrete line of separation in an area of intraparenchymal hemorrhage. It is a rare and unique finding

denoting coagulopathy secondary to oral anticoagulant use. It has 59% sensitivity and 98% specificity for indicating underlying coagulopathy. It could be seen within the first 12 hours [1].

The incidence of oral anticoagulant-associated intracerebral hemorrhage (OAC-ICH) is increasing probably due to increased Warfarin use for the treatment of atrial fibrillation. Anticoagulant-associated intracerebral hemorrhage now accounts for nearly 20% of all intracranial hemorrhage. Among patients using warfarin for atrial fibrillation, the annual risk of ICH in trials is 0.3 to 1.0%. Predictors of potential anticoagulant-associated hemorrhage are increasing age, prior ischemic stroke, hypertension, leukoaraiosis, the early period of Warfarin use, higher intensity anticoagulation, and antiplatelet use in addition to anticoagulation [2].

Compared with other intracranial hemorrhage patients, anticoagulated patients have a greater risk of hematoma expansion, subsequent clinical deterioration and may be fatal in at least 50% of cases if untreated necessitating vigorous reversal of their coagulopathy. Most frequently, OAC-ICH are located in deep or lobar regions of the brain, although it may also occur in the cerebellum and brainstem. Early diagnosis and treatment of this condition may improve the 50% mortality in these patients [3].

*Corresponding author: Ismail II, Neurology Specialist, Department of Neurology, Alexandria University, IbnSina Hospital, Sulaibikhat Area, Shuwaikh Industrial Area, Kuwait, 90003, Tel: 96598871710; E-mail: dr.ismail.ibrahim2012@gmail.com

Received April 13, 2015; Accepted April 15, 2015; Published April 17, 2015

Citation: Ismail II (2015) Blood-Fluid level: A Sign of Oral Anticoagulant-Associated Intracerebral Hemorrhage in a Patient with Ischemic Stroke. J Neurol Disord 3: i111. doi:10.4172/2329-6895.1000111

Copyright: © 2015 Ismail II. This is an open-access article distributed under the terms of the Creative Commons Attribution License, which permits unrestricted use, distribution, and reproduction in any medium, provided the original author and source are credited.

References

1. Mittal MK, Burkholder DB, Wijidicks EF (2012) Blood-fluid level on computed tomography head: a sign of warfarin-associated intraparenchymal hemorrhage. Am J Emerg Med 30: 2079.
2. Cervera A, Amaro S, Chamorro A (2012) Oral anticoagulant-associated intracerebral hemorrhage. J Neurol. 259: 212-224.
3. Lauer A, Pfeilschifter W, Schaffer CB, Lo EH, Foerch C (2013) Intracerebral haemorrhage associated with antithrombotic treatment: translational insights from experimental studies. Lancet Neurol 12: 394-405.

Citation: Ismail II (2015) Blood-Fluid level: A Sign of Oral Anticoagulant-Associated Intracerebral Hemorrhage in a Patient with Ischemic Stroke. J Neurol Disord 3: i111. doi:[10.4172/2329-6895.1000i111](https://doi.org/10.4172/2329-6895.1000i111)

Submit your next manuscript and get advantages of OMICS Group submissions

Unique features:

- User friendly/feasible website-translation of your paper to 50 world's leading languages
- Audio Version of published paper
- Digital articles to share and explore

Special features:

- 400 Open Access Journals
- 30,000 editorial team
- 21 days rapid scholarly review process
- Quality, quick editorial, peer review and publication processing
- Indexing at PubMed (partial), Scopus, EBSCO, Index Copernicus and Google Scholar etc
- Sharing Option: Social Networking Enabled
- Authors, Reviewers and Editors rewarded with online Scientific Credits
- Better discount for your subsequent articles

Submit your manuscript at: <http://scholarscentral.com/>

