

# Can Combined Ultrasound and Laser Therapy Potentiate the Treatment of a Symptomatic Osteoarthritis? A Case Report

Ana Elisa Serafim Jorge<sup>1\*</sup>, Michele Luise de Souza Simão<sup>2</sup>, Ana Carolina Fernandes<sup>2</sup>, Aline Chiari<sup>2\*</sup>, Antonio Eduardo de Aquino Junior<sup>2\*</sup>, Anderson Luiz Zanchin<sup>3</sup> and Vanderlei S Bagnato<sup>2</sup>

<sup>1</sup>Physical Therapy Department, Federal University of São Carlos, São Carlos, São Paulo, Brazil

<sup>2</sup>Sao Carlos Institute of Physics, University of São Paulo, São Carlos, São Paulo, Brazil

<sup>3</sup>MMOptics, São Carlos, São Paulo, Brazil

**Corresponding authors:** Ana Elisa Serafim Jorge, Physical Therapy Department, Federal University of São Carlos, Rodovia Washington Lus, CEP:13565-905, São Carlos, São Paulo, Brazil, Tel: +55 (16) 3351 8345; E-mail: [anajorge@ufscar.br](mailto:anajorge@ufscar.br)

Aline Chiari, São Carlos Institute of Physics, University of São Paulo, PO Box 369, 13560-970, São Carlos, São Paulo, Brazil, Tel: +55 (16) 3373 9810; E-mail: [alinechiari@gmail.com](mailto:alinechiari@gmail.com)

Antonio Eduardo de Aquino Junior, São Carlos Institute of Physics, University of São Paulo, PO Box 369, 13560-970, São Carlos, São Paulo, Brazil, Tel: +55 (16) 3373 9810; E-mail: [antonioaquino@ifsc.usp.br](mailto:antonioaquino@ifsc.usp.br)

**Received date:** November 06, 2017; **Accepted date:** November 15, 2017; **Published date:** November 17, 2017

**Copyright:** © 2017 Jorge AES, et al. This is an open-access article distributed under the terms of the Creative Commons Attribution License, which permits unrestricted use, distribution, and reproduction in any medium, provided the original author and source are credited.

## Abstract

Osteoarthritis of the knee (KOA) is a chronic degenerative musculoskeletal disease associated with functional disability and chronic pain. Currently, physical modalities, such as ultrasound and Laser therapies, are usually prescribed in rehabilitation scenarios as an adjunctive treatment of symptomatic KOA. These therapies have demonstrated great potential to reduce pain and improve the functional capacity of patients with this disease.

Thus, the purpose of this case report was to show the effects of prototype equipment specially developed to perform the combined application of therapeutic ultrasound and laser therapy in the symptoms of knee osteoarthritis.

The present case reports the use of a prototype of equipment developed to perform the combined application of ultrasound and laser therapy. A 63-year-old woman with KOA for 12 years with painful complaints and worsening of functional capacity was submitted to 12 sessions using the prototype. After treatment, she observed a 95% reduction in pain and a decrease in the WOMAC questionnaire indexes related to pain, morning stiffness, and disability. In addition, to a 50% improvement in the sit and put test.

Like this, a single case study shows the efficacy of the combined US and laser therapy on pain and function in the treatment of the symptomatic KOA. The results analyzed, as well as the patient's report make it possible to show the effectiveness in the conjugated treatment and the new equipment.

**Keywords:** Osteoarthritis; Low-level laser therapy; Ultrasound therapy

## Introduction

Osteoarthritis (OA), a chronic degenerative musculoskeletal disease, affecting about 20% of the world population, with higher prevalence in women [1,2]. The knee OA (KOA) is the most common type of osteoarthritis of lower limbs characterized structurally by destruction of cartilage, and bone changes, as subchondral sclerosis and osteophytes. Due to its inflammatory characteristic, mainly of the synovial membrane, patients may present pain and functional disability, and consequently impaired quality of life [2,3]. In this context, pain is one of the main reasons for the patient to seek medical attention.

Prescribed pharmacological treatments for symptomatic KOA can lead to gastrointestinal irritation and dose dependence. The recommended non-pharmacological interventions are weight loss and physical exercise [4,5]. Moreover, physical modalities, such as US and

Laser therapies, are usually prescribed in rehabilitation scenarios as an adjunctive treatment of symptomatic KOA.

In 2010, in a Cochrane review, the effects of therapeutic ultrasound were shown to have great potential in reducing pain and improving the functional capacity of patients with this disease [6]. Similarly, laser therapy has been used to modulate pain. The studies are based on the anti-inflammatory effect of light as an explanation for the improvement of pain [7-9]. In this Context, the uses of technology as therapy excellent option of treatment propose in reason of necessity of decrease of medicine intake.

The aim of this brief report is to illustrate the effect of a combined therapeutic ultrasound and low-level laser treatment for symptomatic KOA. Besides, the prototype of equipment was specially development to promote the conjugated application (US and Laser), which can become a differential in treatment.

## Case Report


A 63-year-old woman, Caucasian, was admitted to our unit complaining of constant pain in the right knee with diagnosis of KOA

for 12 years. She presented, prior to the intervention, joint edema, and limited range of motion (ROM) caused by morning pain and stiffness. She also reported functional limitations in walking, sitting, lifting activities and performing leisure activities, like dancing.

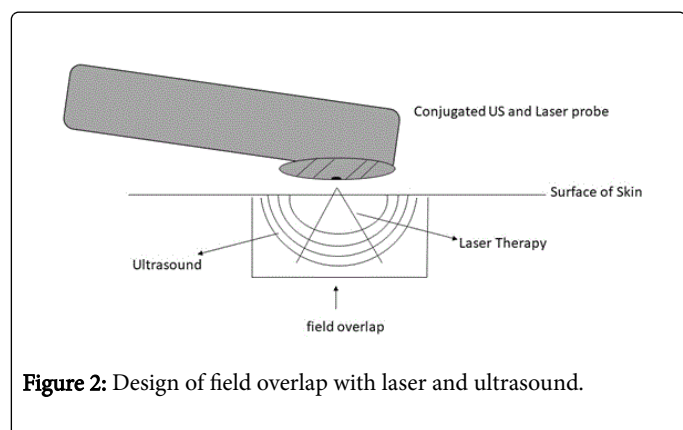
We collected information about her health status, including age, body mass index (BMI), time frame of OA diagnosis, comorbidities, and log of medication. Prior and right after the treatment, important outcome variables, e.g. pain and physical function, were assessed by a visual analogue scale (VAS) and the Western Ontario and McMaster Universities Osteoarthritis index (WOMAC) total score. Performance-based measure of function included the 30-second chair rise test. She signed a written consent prior to treatment.

### Equipment and intervention

It was used a conjugated ultrasound and laser therapy equipment developed by the Laboratory of Technological Support of the Institute of Physics of São Carlos, University of São Paulo (USP). In this specific prototype, the sound and light energy outputs were assembled on the same probe (Figure 1). This equipment possibility an interaction of ultrasound wave and laser beam (Figure 2).



**Figure 1:** A/B. Prototype of the equipment. A) Box with the panel control; B) Conjugated US and Laser probe.



**Figure 2:** Design of field overlap with laser and ultrasound.

The combined therapy was applied to both knees for a total of 12 sessions, 2 times per week. The application protocol was performed on the medial and lateral regions of the patient's knees. The probe was kept in circular constant movements at a 90 degree angle with the skin surface with gel and total contact in order to ensure an optimal energy delivery. Sound and light parameters: a 100 Hz-pulsed ultrasound, 1 MHz of frequency, duty cycle of 50%, and spatial average temporal average (SATA) intensity of 0.5 w/cm<sup>2</sup>. Laser therapy: wavelength of

808 nm and power of 100 mW. Both energies were concomitantly delivered for 12 minutes for each knee.

### Results and Discussion

Table 1 shows the outcome measures at the baseline and right after treatment, where is possible to observe an expressive improvement in pain and function, both evaluated by VAS and WOMAC scores.

Outcomes	Baseline	Post-treatment	Δ
VAS			
Pain	9.7	0.4	-95.90%
WOMAC			
Pain	14	3	-78.60%
Joint Stiffness	5	2	-60%
Function	51	22	-56.80%
Total Score	70	27	-61.40%
Timed Chair Rise Test (repetitions)	6	12	50%

**Table 1:** Baseline and post-treatment outcome measures: VAS for pain, WOMAC scores, and Timed Chair Rise test.

In this clinical case, VAS presented a decrease of 95.9% in pain, WOMAC partial scores presented a decrease of 78.6% in pain, decrease of 60% in knee stiffness, and decrease of 56.8% in disability, with a total score diminished in 61.4%. The great reduction of the mentioned pain parameters, positively guide the intervention. In addition, the performance-based test was improved by 50% of the patient's sit-to-stand capacity. The reduction of the previous parameters, points to the improvement of the quality of life of the patient, providing his return to daily activities.

Moreover, the patient reported that, right after the treatment, she had successfully returned to leisure activity without pain. Hence, this case report corroborates with the results of isolated US or laser treatments found in the literature, and adds evidence that this specific combined therapy benefits the treatment of KOA [10]. In this way, our results point to a quantified improvement far beyond the observed results in isolated traditional therapy (US or Laser).

Evidence found in the literature shows the efficacy of therapeutic ultrasound alone in individuals with KOA up to 21% in pain improvement using the modality in pulsed mode and low intensity [4,10]. In like fashion the LLLT alone modulates pain and its anti-inflammatory effect has been investigated in some studies [7,9]. Even though, the effect of these two modalities acting concomitantly has not been studied before, being a precursor of an innovative equipment.

This novel conjugated therapy provides clinically relevant benefits, especially due of field overlap between the ultrasound and laser therapy, thus elucidating a new approach on the management of OA.

### Conclusion

This single case study shows the efficacy of the combined US and laser therapy on pain and function in the treatment of the symptomatic KOA. The results analyzed, as well as the patient report

make it possible to show the effectiveness in the conjugated treatment and the new equipment.

### Ethical Approval

The study was approved by the Hospital Ethical Committee (resolution 466/2012).

### Funding

This work was supported in part by CNPq (INOF-INCT grant 573587/2008-6); FINEP (grant 01.13.0430-00) and São Paulo Research Foundation (FAPESP) grant 2013/07276-1 (CePOF).

### Conflicts of Interest

All authors confirm that there is no conflict of interest.

### References

1. Felson DT (2007) Osteoarthritis. In: Imboden, J; Hellmann, D; Stone, J. *Current Diagnosis & Treatment*. 2nd edtn. LANGE 44: 339-344.
2. Hochberg MC, Altman RD, Brandt KD, Clark BM, Dieppe PA, et al. (1995) Guidelines for the medical management of osteoarthritis. Part II. Osteoarthritis of the knee. *American College of Rheumatology. Arthritis Rheum* 38: 1541-1546.
3. Bennell KL, Hunter DJ, Hinman RS (2012) Management of osteoarthritis of the knee. *British Medical Journal* 345: e4934.
4. Loyola-Sánchez A, Richardson J, MacIntyre NJ (2010) Efficacy of ultrasound therapy for the management of knee osteoarthritis: a systematic review with meta-analysis. *Osteoarthritis and Cartilage* 18: 1117-1126.
5. Jorge RTB, Souza MC, Chiari A, Jones A, Fernandes Ada R, et al. (2015) Progressive resistance exercise in women with osteoarthritis of the knee: a randomized controlled trial. *Clin Rehabil* 29: 234-243.
6. Rutjes AWS, Nüesch E, Sterchi R, Jüni P (2010) Therapeutic ultrasound for osteoarthritis of the knee or hip. *Cochrane Database of Systematic Reviews* 20: CD003132.
7. Jang H, Lee H (2012) Meta-Analysis of pain relief effects by laser irradiation on joint areas. *Photomedicine and Laser Surgery* 30: 405-417.
8. Alfredo PP, Bjordal JM, Dreyer SH, Meneses SR, Zaguetti G, et al. (2012) Efficacy of low level laser therapy associated with exercises in knee osteoarthritis: a randomized double-blind study. *Clinical Rehabilitation* 26: 523-533.
9. Alfredo PP, Bjordal JM, Junior WS, Martins RÁBL, Stausholm MB, et al. (2017) Long-term results of a randomized, controlled, double-blind study of low-level laser therapy before exercises in knee osteoarthritis: laser and exercises in knee osteoarthritis. *Clin Rehabil*.
10. Rodriguez-Merchan EC (2016) Conservative treatment of acute knee osteoarthritis: A review of the Cochrane Library. *Journal of Acute Disease* 5: 190-193.