

## Change of the X-ray Beam Angle may Influence Ankle Image of Weight-bearing Anteroposterior View: Trial to Evaluate Ankle Joint on Standing Whole-leg Radiograph

Ryuhei Katsui<sup>1</sup>, Tadashi Fujii<sup>4\*</sup>, Katsuya Ito<sup>3</sup>, Akira Taniguchi<sup>2</sup> and Yasuhito Tanaka<sup>4</sup>

<sup>1</sup>Department of Orthopaedic Surgery, Heisei Memorial Hospital, Japan

<sup>2</sup>Nara Kashiba Center for Arthroplasty and Spine Surgery, Japan

<sup>3</sup>Department of Orthopaedic Surgery, Ishinkai Yao General Hospital, Japan

<sup>4</sup>Department of Orthopaedic Surgery, Nara Medical University Kaminaka 839, Kashiba, Nara 639-0265, Japan

\*Corresponding author: Tadashi Fujii, Department of Orthopaedic Surgery, Nara Medical University Kaminaka 839, Kashiba, Nara 639-0265, Japan, Tel: +81-745-77-8101; Fax: +81-745-78-5090; E-mail: [tadashifujii@gmail.com](mailto:tadashifujii@gmail.com)

Received date: January 15, 2016; Accepted date: March 25, 2016; Published date: March 29, 2016

Copyright: © 2015 Katsui R, et al. This is an open-access article distributed under the terms of the Creative Commons Attribution License, which permits unrestricted use, distribution, and reproduction in any medium, provided the original author and source are credited.

### Abstract

Upon evaluating the ankle joint structures by using standing whole-leg anteroposterior (AP) radiographs, the angle at which the X-ray beam is projected to the ankle joint, may distort the image. The accuracy and validity of the measurement of the ankle joint structure was investigated using weight-bearing AP radiographs obtained at several angles of X-ray beam projection for the clinical availability.

Three weight-bearing AP view radiographs of each limb were acquired upon projecting the X-ray beam cranially, and at 0°, 5°, and 10° to the ankle joint. The tibial anterior surface angle (TAS angle), tibial medial malleolus angle (TMM angle), and tibial bimalleolus angle (TBM angle) were measured on each weight-bearing AP view of the ankle joint. The measurements of the TAS, TMM, and TBM angles were then statistically compared.

The TAS angle did not change as the projected angle increased. No significant differences were observed between the groups. The TMM angle decreased gradually as the projected angle increased. A significant difference was observed between 0° and 10°. The TBM angle increased gradually as the projected angle increased. A significant difference was observed in the TBM angle between 0° and 5° as well as between 0° and 10°.

The TAS angle, which indicates varus/valgus deformity of the ankle joint, can be assessed with the projected angle of 10°.

**Keywords:** On standing whole-leg AP radiographs; Ankle joint; TAS; TMM; TBM

### Introduction

Standing whole-leg anteroposterior (AP) radiographs, beaming horizontally to the knee joint are used for the comprehensive analysis of the magnitude and cause of limb malalignment [1], and for assessing leg length discrepancy [2]. Standing whole-leg AP radiographs are often used to assess preoperative and postoperative alignment of the knee after arthroplasty and can be used to evaluate relationships among the hip, knee, and ankle joints.

Lee et al. [3] reported radiographic changes of the ankle joint upon examination of standing whole-leg AP radiographs acquired after total knee arthroplasty (TKA). They examined the tibial anterior surface angle (TAS angle) to assess radiographic changes of the ankle joint such as those observed in individuals with osteoarthritis.

In addition to the TAS angle, the tibial medial malleolus angle (TMM angle) and tibial bimalleolus angle (TBM angle) are used to assess radiographic changes of the ankle joint [4-8]. These angles were first reported in the Japanese literature by Katsui et al. [4] in 1980 and in the English literature by Takakura et al. [7] in 1995. The TAS angle

was described as the various position of the distal tibial joint surface, and TMM angle was defined as the distal opening of the joint surface of the medial malleolus on the AP view [7].

The TAS angle, the TMM angle, and the TBM angle, as indices of ankle joint structure, are usually evaluated using weight-bearing AP views of the ankle. However, standing whole-leg AP radiographs are also very useful for monitoring the longevity of total ankle arthroplasty related to malalignment. The evaluation of ankle joint alignment is important, not only for foot/ankle disorders, but for knee joint disorders. Information pertaining to the relationship between foot/ankle disorders and the longevity of TKA is scarce. Evaluation of the ankle on standing whole-leg AP radiographs enables visualization of interactions among adjacent joints of the leg.

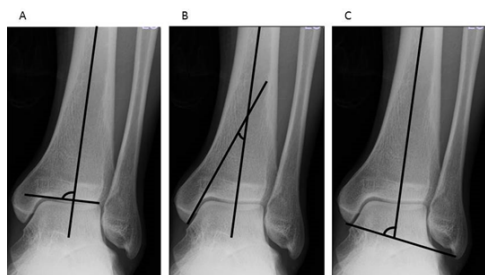
To the best of our knowledge, and based on a review of the literature, Lee et al. is the only group that has evaluated ankle joint structure by examining the TAS angle on standing whole-leg AP radiographs. However, when evaluating ankle joint structure using standing whole-leg AP radiographs, the X-ray beam has a projected angle, relative to the ankle joint, which may distort the image.

The purpose of this study is to evaluate ankle joint structure on standing whole-leg AP radiographs acquired at various angles of the X-ray beam and to validate the images for the clinical availability.

## Materials and Methods

In this study, we examined 60 limbs from 30 healthy volunteer subjects (20 male subjects, 10 female subjects; mean age, 28.9 years, age range, 22-48 years) who gave their consent for enrolment in this study.

There is a projected angle of 6-9° cranially relative to the ankle joint when evaluating the ankle joint structure by using standing whole-leg AP radiographs. Therefore, three weight-bearing AP radiographs of each limb were acquired with the X-ray beam angled cranially, at 0°, 5°, and, 10° relative to the ankle joint, simulating a standing whole-leg AP radiograph. The 2nd metatarsal bone should be parallel to x-ray beam and the ankle should be positioned at the flexion/dorsiflexion neutral position when taking the x-ray for the standardization. On each weight-bearing AP ankle joint radiograph, the TAS angle was calculated by measuring the angle between the distal 1/3rd of the tibial shaft and its distal joint surface. The TMM angle was calculated by measuring the angle between the distal 1/3rd of the tibial shaft and the joint surface of the medial malleolus. The TBM angle was calculated by measuring the angle between the distal 1/3rd of the tibial shaft and the axis between both malleolar tips (Figure 1). The distal 1/3rd of the tibial axis was defined as the line between the midpoint of the tibial shaft 8 cm and 13 cm above the tip of the medial malleolus [6].



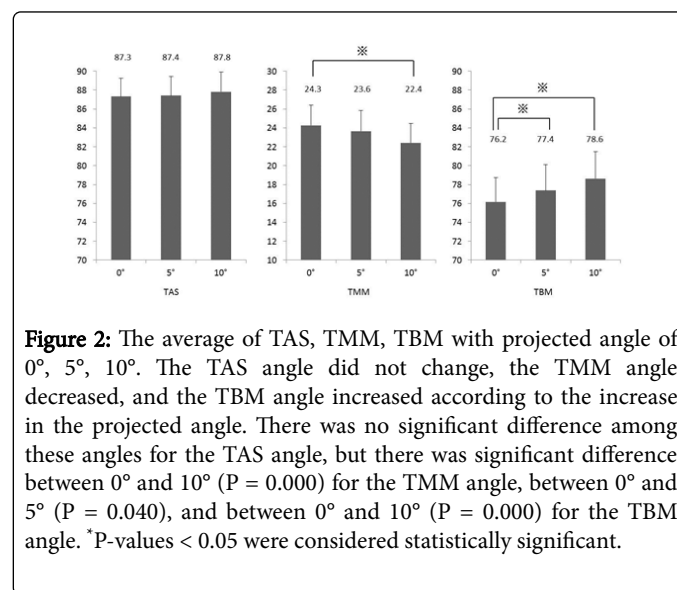
**Figure 1:** Definition of 3 indices of ankle joint image in anteroposterior view. A: The TAS angle is the angle between the distal 1/3rd of the tibial shaft and its distal joint surface. B: The TMM angle is the angle between the distal 1/3rd of the tibial shaft and the joint surface of the medial malleolar joint surface. C: The TBM angle is the angle between the distal 1/3rd of the tibial shaft and the axis between both malleolar tips.

Evaluations included the averages of the TAS angle, TMM angle, and the TBM angle for each projected angle. The one-way analysis of variance (ANOVA) and Dunnett's post-hoc procedure were used to analyze data collected in this study. Measurements were performed by three experienced orthopedic surgeons (RK, AN, YS). Intra and inter examiner reliability were also examined. We used the 1-way random-effects interclass correlation coefficient (ICC) model to calculate the intraobserver and test-retest agreement, and the 2-way random-effects ICC model to calculate the interobserver agreement. The interpretation of ICC values was based on criteria proposed by Landis and Koch [9], with ICC values of 0.00 to 0.20 represented slight agreement, 0.21 to 0.40 represented fair agreement, 0.41 to 0.60 represented moderate agreement, 0.61 to 0.80 represented substantial agreement, and over 0.80 represented almost perfect agreement. The

statistical software used was SPSS (Statistics Premium Grad Pack Shrinkwrap Version 22.0), and the level of statistical significance was set at  $p < 0.05$ . This study was approved by our hospital's ethics committee.

## Results

The mean TAS angles were  $87.3 \pm 1.9$  (mean  $\pm$  SD)°,  $87.4 \pm 2.0$ °, and  $87.8 \pm 2.1$ ° at the projected angles of 0°, 5°, and 10° respectively. The mean TMM angles were  $24.3 \pm 2.2$  (mean  $\pm$  SD)°,  $23.6 \pm 2.2$ °, and  $22.4 \pm 2.0$ ° at the projected angles of 0°, 5°, and 10° respectively. The mean TBM angles were  $76.2 \pm 2.6$  (mean  $\pm$  SD)°,  $77.4 \pm 2.7$ °, and  $78.6 \pm 2.9$ ° at the projected angles of 0°, 5°, and 10° respectively (Figure 2).



**Figure 2:** The average of TAS, TMM, TBM with projected angle of 0°, 5°, 10°. The TAS angle did not change, the TMM angle decreased, and the TBM angle increased according to the increase in the projected angle. There was no significant difference among these angles for the TAS angle, but there was significant difference between 0° and 10° ( $P = 0.000$ ) for the TMM angle, between 0° and 5° ( $P = 0.040$ ), and between 0° and 10° ( $P = 0.000$ ) for the TBM angle. \* $P$ -values  $< 0.05$  were considered statistically significant.

The TAS angle showed no change with an increase of projected angles (i.e., from 0° to 5° and 10°). Moreover, the angle measurements did not statistically differ among the radiographs acquired. The TMM angle decreased gradually as the projected angle of the X ray increased from 0° to 5° to 10°; a significant difference was observed between radiographs acquired at projected angles of 0° and 10°. The TBM angle increased gradually as the projected angle of the X-ray increased from 0° to 5° to 10°; a significant difference was observed both between 0° and 5° comparison group and between the 0° and 10° comparison group.

The intraclass correlation coefficient (ICC) for reliability was calculated. For intra-rater reliability, the ICCs for the TAS angle measured on radiographs acquired cranially and at 0°, 5°, and, 10° relative to the ankle joint were 0.633, 0.711, and 0.720, respectively. The ICCs for the TMM angle measured on radiographs acquired cranially, and at 0°, 5°, and, 10° relative to the ankle joint were 0.505, 0.537, and 0.560, respectively. The ICCs for the TBM angle measured on radiographs acquired cranially, and at 0°, 5°, and, 10° relative to the ankle joint were 0.916, 0.937, and 0.932, respectively. For the inter-rater reliability, the ICCs for the TAS angle measured on radiographs acquired cranially, and at 0°, 5°, and, 10° relative to the ankle joint were 0.454, 0.520, and 0.615, respectively. The ICCs for the TMM angle measured on radiographs acquired cranially, and at 0°, 5°, and, 10° relative to the ankle joint were 0.618, 0.618, and 0.698, respectively. The ICCs for the TBM angle measured on radiographs acquired cranially,

and at 0°, 5°, and 10° relative to the ankle joint were 0.859, 0.902, and 0.907, respectively (Table 1).

	Intraobserver reliability ICC (95% CI)	Intraobserver reliability ICC (95% CI)
TAS 0°	0.633 (0.457-0.761)	0.454 (0.176-0.651)
5°	0.711 (0.563-0.815)	0.520 (0.259-0.698)
10°	0.720 (0.576-0.821)	0.615 (0.399-0.760)
TMM 0°	0.505 (0.295-0.669)	0.618 (0.269-0.791)
5°	0.537 (0.334-0.692)	0.618 (0.320-0.781)
10°	0.560 (0.363-0.709)	0.698 (0.423-0.833)
TBM 0°	0.916 (0.864-0.948)	0.859 (0.784-0.911)
5°	0.937 (0.897-0.961)	0.902 (0.847-0.938)
10°	0.932 (0.889-0.953)	0.907 (0.850-0.943)

**Table 1:** Intra- and interobserver reliabilities.

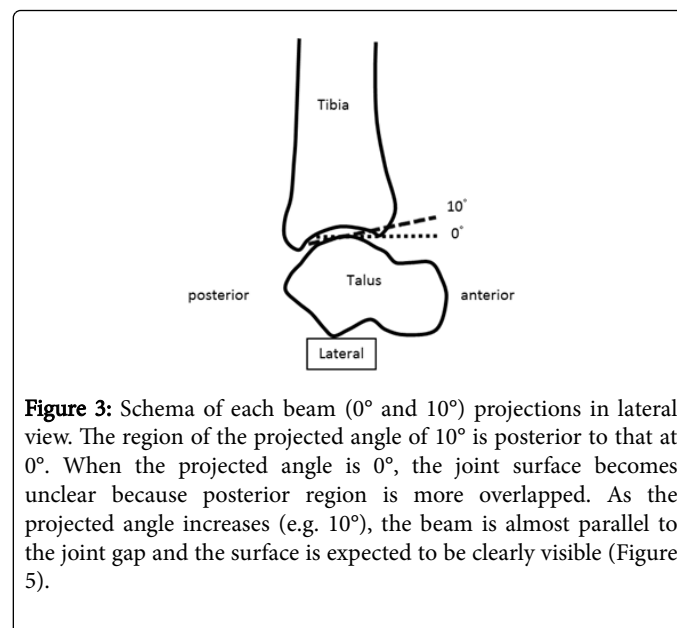
## Discussion

Standing whole-leg AP radiographs are useful for measuring lower limb alignment as they can be used to evaluate the relationships between the hip and the knee, the knee and the ankle, and even that between the hip and the ankle joints. The X-ray beam in a standing whole-leg AP radiograph is aimed horizontal to the knee joint, but to the ankle joint with 6-9° tilts, which may distort the ankle image. Our study focused on projection angle 6-9° that is an issue when evaluating the ankle joint on standing whole-leg AP radiographs. Three indices of ankle joint structures (i.e., TAS, TMM, TBM) were statistically compared in radiographs acquired from three different X-rays beam angles (i.e., 0°, 5°, 10°), simulating a standing whole-leg AP radiograph. Results showed that the TAS angle did not change with increases in the projected angle. However, the TMM angle became significantly smaller and the TBM angle became significantly larger as the projected angle increased.

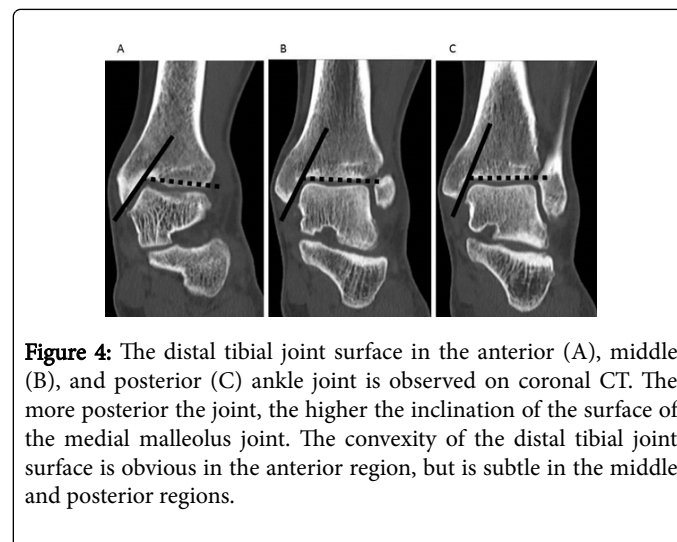
The TAS angle is an indicator of ankle joint varus deformity, and a decreased TAS angle is associated with the development of ankle osteoarthritis [4-6]. The depicted plafond and the associated TAS angle may change if the area of the tibial distal joint surface, which is tangential to the X-ray beam, is different (Figure 3). At the projected angle of 0°, the middle of the tibial distal joint surface is observed, and at the projected angle of 10°, the middle and slightly more posterior areas can be observed. When multi-planar reformation was used to examine the coronal plane of the anterior, middle, and posterior tibial distal joint surfaces by using computed tomography (CT), the tilt of the joint surface to the lateral, which is obvious in the anterior region, was decreased in the middle and posterior parts (Figure 4). The tilt and shape of the plafond observed at the projected angle of 0° were similar to those observed at the projected angle of 10°; the lateral inclination in the anterior region could not be identified at either projected angle. Consequently, the TAS angle did not change between these projected angles.

The TMM angle is an indicator of the distal opening of the joint surface of the medial malleolus, and the presence of TMM angle is associated with ankle osteoarthritis [4]. Furthermore, the increase corresponds to the severity of ankle osteoarthritis [5]. At the projected angle of 0°, the X-ray beam traverses the medial malleolar joint surface, and the joint surface is clearly visualized. However, the X-ray

beam can no longer traverse the medial malleolar joint surface as the projected angle increases, and the joint surface of the medial malleolus is gradually more difficult to be depicted from the tangential view (Figure 5). When the medial malleolar joint surfaces in the anterior, middle, and posterior regions of the plafond are observed on coronal CT scans, the more posterior the joint, the higher the inclination of the medial malleolus joint surface (Figure 4). The posterior region of the medial malleolar joint surface is substantially viewed, and the inclination increases due to an increase in the projected angle.



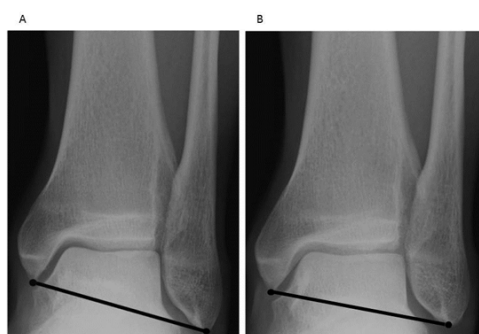**Figure 3:** Schema of each beam (0° and 10°) projections in lateral view. The region of the projected angle of 10° is posterior to that at 0°. When the projected angle is 0°, the joint surface becomes unclear because posterior region is more overlapped. As the projected angle increases (e.g. 10°), the beam is almost parallel to the joint gap and the surface is expected to be clearly visible (Figure 5).



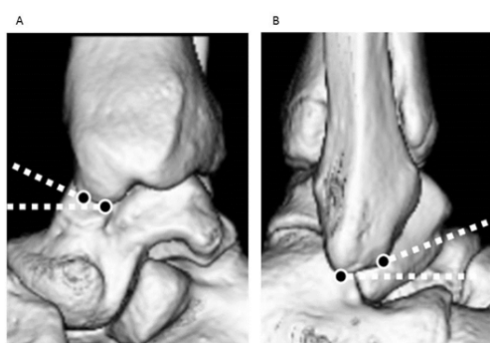
**Figure 4:** The distal tibial joint surface in the anterior (A), middle (B), and posterior (C) ankle joint is observed on coronal CT. The more posterior the joint, the higher the inclination of the surface of the medial malleolus joint. The convexity of the distal tibial joint surface is obvious in the anterior region, but is subtle in the middle and posterior regions.

The TBM angle is an indicator of ankle joint varus due to congenital or post-traumatic deformities such as severe tri-malleolar fracture. The true kinematic axis of the ankle joint is not the line connecting the medial and lateral malleolus; rather, it is a line that extends slightly anterior from the tip of the medial malleolus to slightly inferior to the tip of the lateral malleolus [5]. However, the kinematic axis of the ankle joint is usually represented by the tips of both malleoli as an index [10]. Geometrically, the placement tip of the medial malleolus is more anterior than the tip of the lateral malleolus. Therefore, the distance from the medial malleolus to the film is longer than the distance of the

lateral malleolus to the film. Thus, when the projected angle is increased, the medial malleolus seems to move more downward compared to the lateral malleolus, and the TBM angle increases. In addition, if the projected angle is increased and the tips of the medial and lateral malleoli are consequently viewed from above, the tangential depicted points of both malleoli shift anterosuperiorly. Based on these bone geometries, the anterosuperior shift of the point of the lateral malleolus is greater than that of the medial malleolus, as seen on the lateral view (Figure 6). Therefore, as the projected angle increases, it appears as if the tip of the lateral malleolus gradually approaches the level of the tip of the medial malleolus, then the TBM angle increase (Figure 5).



**Figure 5:** Ankle joint images in anteroposterior view with projected angles. The medial malleolar joint surface is described clearly at the projected angle of 0°; however, it becomes unclear at the projected angle of 10°. In contrast, the tibial distal joint surface is difficult to visualize at 0° because the overlapped posterior area of the joint surface may make the joint line unclear, but it is clear at the projected angle of 10°. As the projected angle increases, it appears as if the tip of the lateral malleolus gradually approaches the level of the tip of the medial malleolus, and the TBM angle increases.



**Figure 6:** Rendering images of the ankle based on CT. If the projected angle is increased, the tangentially depicted points of the medial (A) and lateral (B) malleolus shift anterosuperiorly. The anterosuperior shift of the point of the lateral malleolus is greater than that of the medial malleolus.

Based on the results, when the ankle joint is evaluated on standing whole-leg AP radiographs, the TMM and TBM angles should be discarded, but only the TAS angle should be assessed. There was no difference between the TAS angle reported in the past which we

understand [5-8] and our results. In a study by Knupp M et al. [11], the TAS angle value is higher than our results. The age of subjects is ranging from 22 to 78 years (43 males, 50 females) in their study, and the age of our study is younger and gender ratio is different. There might be racial variability in addition.

It is reported that chronic injuries of the lateral ligament cases and OA cases shows TAS angle lower than a healthy case. The decrease in the TAS angle is a factor involved ankle joint disorders [4,5] and the measurement of the TAS angle on standing whole-leg AP radiographs can be used to evaluate the relationship between ankle osteoarthritis and whole leg alignment.

Barg A et al. [12] also assessed how x-ray projection could affect the TAS angle, (they called MDTA in their paper), and they found the MDTA would be significantly changed after the x-ray angle changes  $\geq 5$  degrees. In their study, the cadaveric study demonstrated radiographic projection angle on the measurement of supramalleolar ankle alignment by digitally reconstructed radiographs. The reconstructed radiographs are free from the enlarged or distorted image that usually bothered on plain XP. This point is different from our study, which are more practical on clinical situation.

Unfortunately, high reliability for the measurement of the TAS angle, including intra-examiner and inter-examiner reliability, cannot be achieved if the ICC values are examined based on the criteria of Landis et al. [9]. We believe that these results reflect the difficulty of evaluating the TAS angle, especially at low projected angles. The ICC values for intra and inter examiner reliabilities were higher when the projected angle was increased, similar to standing whole-leg AP radiographs. The anterior opening of the ankle joint may anatomically cause low reliability. During imaging, the X-ray beam should be projected, as parallel as possible, to the joint, in order to visualize the joint clearly, but the overlapped posterior region of the joint surface may make the joint line unclear at lower projected angles (Figure 5).

There are two limitations in this study. The subjects were healthy normal adults. The results may therefore differ in patients with ankle osteoarthritis who may have severe varus. In addition, when standing whole-leg AP radiographs are acquired, the distance from the X-ray tube to the film varies between institutions, for example, 2 m, 2.2 m, and 2.8 m, which may also lead to some errors.

## Conclusion

We examined changes in ankle joint structure on weight-bearing AP views upon changing the projected angle of the x ray beam from 0° to 5° to 10° in 60 healthy volunteer limbs.

When the ankle joint was evaluated on standing whole-leg AP radiographs, even with an increased projected angle, the TAS angle did not change. However, as the projected angle increased, the TMM angle decreased and TBM angle increased.

We are convinced that the TAS angle can be assessed when the ankle joint is evaluated using standing whole-leg AP radiographs because the X-ray beam projected angle is 6-9° relative to the ankle joint.

## References

1. Sabharwal S, Zhao C, Mckeeon JJ, McClemens E, Edgar M, et al. (2006) Computed radiographic measurement of limb-length discrepancy. Full-length standing anteroposterior radiograph compared with scanogram. J Bone Joint Surg Am 88: 2243-2251.

2. Paley D (2002) Principles of deformity correction. Berlin: Springer.
3. Lee JH, Jeong BO (2012) Radiologic changes of ankle joint after total knee arthroplasty. *Foot Ankle Int* 33: 1087-1092.
4. Katsui T, Takakura Y, Kitada C (1980) Roentgenographic analysis for osteoarthritic of the ankle. *J Jpn Soc Surg Foot* 1: 52-57.
5. Monji J (1980) Roentgenological measurement of the shape of the osteoarthritic ankle (author's transl). *Nihon Seikeigeka Gakkai Zasshi* 54: 791-802.
6. Tanaka Y, Takakura Y, Hayashi K, Taniguchi A, Kumai T, et al. (2006) Low tibial osteotomy for varus-type osteoarthritis of the ankle. *J Bone Joint Surg Br* 88: 909-913.
7. Takakura Y, Tanaka Y, Kumai T, Tamai S (1995) Low tibial osteotomy for osteoarthritis of the ankle. Results of a new operation in 18 patients. *J Bone Joint Surg Br* 77: 50-54.
8. Sugimoto K, Samoto N, Takakura Y, Tamai S (1997) Varus tilt of the tibial plafond as a factor in chronic ligament instability of the ankle. *Foot Ankle Int* 18: 402-405.
9. Landis JR, Koch GG (1977) The measurement of observer agreement for categorical data. *Biometrics* 33: 159-174.
10. Sammarco GJ, Burstein AH, Frankel VH (1973) Biomechanics of the ankle: a kinematic study. *Orthop Clin North Am* 4: 75-96.
11. Knupp M, Ledermann H, Magerkurth O, Hinterman B (2005) The surgical tibiotalar angle: a radiologic study. *Foot Ankle Int* 26: 713-716.
12. Barg A, Amendola RL, Henninger HB, Kapron AL, Saltzman CL, et al. (2015) Influence of Ankle Position and Radiographic Projection Angle on Measurement of Supramalleolar Alignment on the Anteroposterior and Hindfoot Alignment Views. *Foot Ankle Int* 36: 1352-1361.