

## Chondrosarcoma of Second Toe Distal Phalanx-A Case Report

Gurumoorthy PG, Dinkar Rai BK\*, Arvind Kumar SM and Chaitra V

Department of Orthopaedics, PSG Institute of Medical Sciences and Research, Coimbatore, Tamil Nadu, India

\*Corresponding author: Dinkar Rai BK, Department of Orthopaedics, PSG Institute of Medical Sciences and Research, Coimbatore, Tamil Nadu, India, Tel: +91-9894140052; E-mail: dinakarrai@hotmail.com

Rec date: Jan 06, 2018; Acc date: Jan 31, 2018; Pub date: Feb 07, 2018

Copyright: © 2018 Gurumoorthy PG, et al. This is an open-access article distributed under the terms of the Creative Commons Attribution License, which permits unrestricted use, distribution, and reproduction in any medium, provided the original author and source are credited.

### Abstract

Chondrosarcoma is a relatively common primary malignant bone lesion. It is a malignant, relatively slow growing cartilage producing tumor. It forms approximately 10% of malignant primary bone tumors. However, it usually arises in long bones and truncal bones, whereas these tumors are uncommon in the hands and feet. The type are (A) Primary chondrosarcomas arises denovo from bone without any preexisting lesion. (B) Secondary chondrosarcomas when tumor arises from preexisting benign lesions of bone. Primary tumor is generally seen between 40 to 60 years of age. Secondary chondrosarcomas are more common in young adults.

**Keywords:** Chondrosarcoma; Tumor; Chondroblastoma; Bone; Neoplasm

### Pathology of Chondrosarcomas

#### Central type

It is a lobulated, translucent, bluish whitish cartilaginous mass with in medullary cavity. Endosteal aspect of cortex appears eroded and scalloped. Tumor spreads widely through medullary cavity, its extent is greater than it appears on X-rays. As tumor penetrates the cortex it is temporarily delimited by periosteum. New reactive new bone is formed at the periphery of sub periosteal mass there by thickening the cortex. This is seen in slow growing and less malignant tumors.

In rapidly growing tumors periosteum is penetrated easily, so no reactive new bone formation. When a firm greyish tanned tissue without lobular configuration is found, it represents most malignant type. On removing the closely investing periosteum, the tumor appears lobulated, bluish white, shiny, opalescent or semitranslucent mass of firm texture or rubbery consistency.

The cut surface exhibits specks of calcification that impart a gritty sensation on palpation, gelatinous or myxoid areas and ragged cavities. The degree of calcification is greater in slower growing tumors.

#### Microscopic appearance

Histological features of cartilage should be noted to diagnose presence of a cartilaginous tumor. A normal chondrocyte is ellipsoid, ovoid or round in shape, has slightly scalloped surfaces. It contain a central, oval, sometimes indented nucleus with regularly distributed abundant chromatin and indistinct nucleolus.

Sarcomatous chondrocytes and their nuclei vary greatly in size, shape, number of nuclei and nucleoli chromatin content. Histology shows signs of malignancy including hyper cellularity, plumpness of nuclei, double nuclei in more than occasional cells, pleomorphism of cells and nuclei, hyperchromatism and mitotic figures. Mitotic figures are rare in low and medium grade tumors but are readily found in high grade tumors.

### Radiological Features

#### Central tumors

The lesion is seen in metaphysis or diaphysis of a long tubular bone. Rarely it may occupy epiphysis at juxtraarticular area, where it may be mistaken for a giant cell tumor or chondroblastoma. The lesion is located in medullary cavity, it is large and ill defined. Countour of bone is enlarged or expanded. The cortex is focally or extensively eroded and thinned out. The inner cortex may have scalloped borders. Tumors will have specks of calcification and cotton whorl appearance. Slow growing tumors will show a greater of calcification where as highly malignant rapidly growing tumors will show little or no calcification and often destroys the cortex without expanding shaft. There is a associated soft tissue mass.

#### Low grade features

Dense calcification forming rings or specules with eccentric lobular growth of a soft tissue mass

#### High grade features

Faint amorphous calcifications with large non calcified areas and concentric growth of soft tissue mass.

This article presents the case of a 60-year-old woman with a chondrosarcoma in the distal phalanx of the left second toe. Radiography showed bony mass extending from the distal phalanx. Histologically, the tumor was classified as grade 1 chondrosarcoma [1-6].

### Case Report

- A 60 yrs old lady presented with pain and swelling of the left second toe for the past 1 year.
- Insidious onset and Gradually progressive
- No rest pain/night cries/constitutional features
- No other swellings in body

- k/c/o Type 2 diabetics and systemic hypertension for the past 2 yrs on regular medication

### Local examination (left 2<sup>nd</sup> toe)

- Irregular well defined Swelling over the distal phalanx 2 X 3cms.
- Minimal deep tenderness, No warmth.
- Heterogenous consistency ranging from firm to bony hard.
- Adherent to underlying soft tissues and Immobile.
- Non pulsatile, Non fluctuant and Opaque.
- ROM–full range (Figure 1).

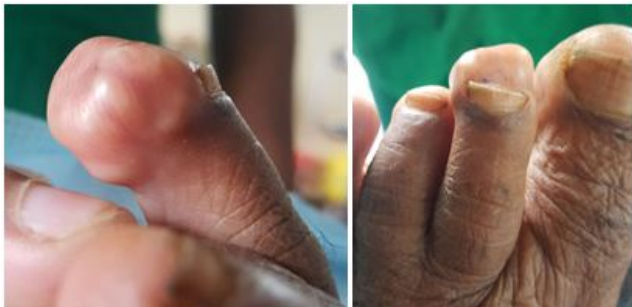

Figure 1: Local examination (left 2<sup>nd</sup> toe).

Figure 2 shows expansile chondroid matrix lesion involving the distal phalanx of the second toe not involving the articular surface and no soft tissue infiltration.

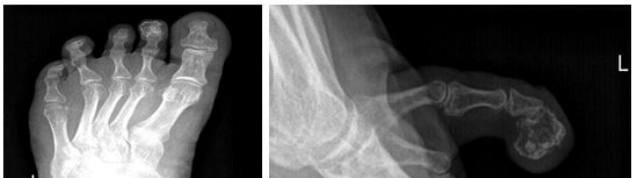

Figure 2: X-ray 2nd toe AP/Lateral.

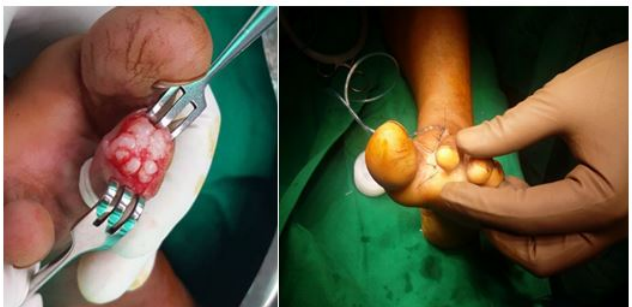

Figure 3: Plan.

### Plan

Patient was taken up for excision biopsy under local anesthesia and using Ray's amputation technique disarticulation of the second toe at MTP joint (Figure 3).

### Histologically

Sections show fragments of bone with an infiltrating neoplasm composed of nodules of cartilaginous tissue with varying cellularity (hypercellular). The chondrocytes have moderate amount of cytoplasm mildly atypical hyperchromatic nucleus and few showing prominent nucleoli. Binucleate and trinucleate chondrocytes are seen. The cartilaginous matrix appears thin and mucoid at places. The tumour seen permitting the cortical bone causing bone entrapment (Figure 4).

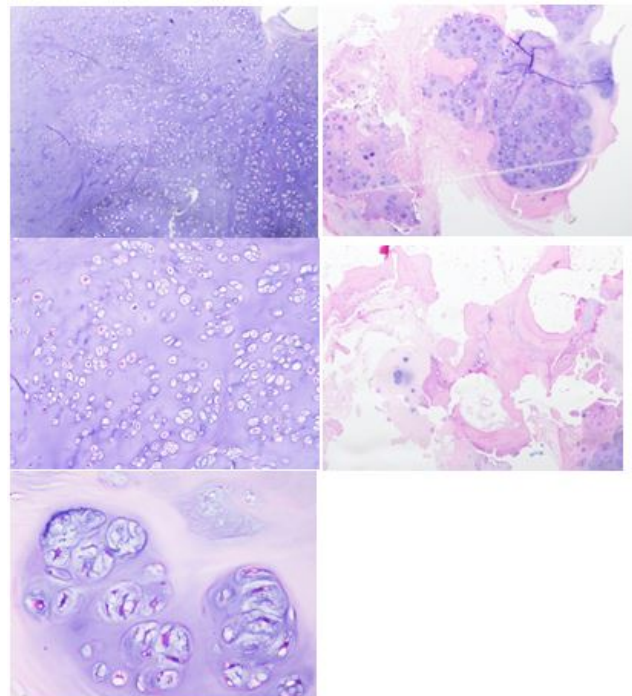


Figure 4: Histology.

### Discussion

Chondrosarcoma of the foot is rare. Correct classification of the grade of chondrosarcoma is extremely important because the prognosis and treatment are different for different stages and grades (Table 1). Evans et al. used their own grading system: low grade is a low-level malignancy, intermediate grade is moderately malignant, and high grade is highly malignant. The chondrosarcoma of the phalanx is rare but, when present, extirpation is necessary to prevent growth and spread. Therefore, every effort should be made to differentiate between enchondroma and chondrosarcoma in each case. Complete wide excision of the lesion and cartilage cap should not be violated during resection of chondrosarcoma arising out of osteochondroma as it will increase the risk of local recurrence.

**Prognosis:** Tumor arising in osteochondromas have excellent prognosis. Secondary chondrosarcomas arising in enchondromatosis have same prognosis as that of conventional chondrosarcomas [1-6].

Grade	Tumor	Symptoms	Prognosis	Treatment
Benign	Enchondroma Osteochondroma	Usually no symptoms	Excellent	Surveillance, intralesional excision if symptomatic
Malignant(Low grade)	Grade 1 Chondrosarcoma	60% are painful	Excellent	Controversial: Extended intralesional excision vs. wide resection
Malignant(Low grade)	Grade 2 Chondrosarcoma	Up to 80% are painful	Good	Wide resection
Malignant(intermediate grade)	Grade 3 Chondrosarcoma	Up to 80% are painful	Fair	Wide resection. Chemotherapy and radiation therapy in selected cases
Malignant(High grade)	De-differentiated Chondrosarcoma	Most are painful	Poor	Wide resection. Chemotherapy when possible in all cases. Radiation therapy in selected
Malignant(High grade)	Mesenchymal Chondrosarcoma	Pain and swelling	Fair-Poor	Wide resection. Chemotherapy in all cases.

**Table 1:** Classification [6].

## Conclusion

Phalangeal chondrosarcoma behaves as locally aggressive lesion and rarely metastasize. Curettage with local adjuvant and adequate follow-up can be tried as the first-line management, especially where amputation would lead to significant loss of function.

## References

1. Evans HL, Ayala AG, Romsdahl MM (1977) Prognostic factors in chondrosarcoma of bone. A clinicopathologic analysis with emphasis on histologic grading. *Cancer* 40: 818–831.
2. Masuda T, Otuka T, Yonezawa M, Kamiyama F, Shibata Y, et al. (2004) Chondrosarcoma of the distal phalanx of the second toe: A case report. *J Foot Ankle Surg* 43: 110-112.
3. Mondal SK (2012) Chondrosarcoma of the distal phalanx of the right great toe: Report of a rare malignancy and review of literature. *J Cancer Res Ther* 8: 123-125.
4. Patil S, De silva MVC, Crossan J, Reid R (2003) Chondrosarcoma of the bones of the feet. *J Foot Ankle Surg* 42: 290-295.
5. Ogose A, Unni KK, Swee RG, May GK, Rowland CM, et al. (1997) Chondrosarcoma of small bones of the hands and feet. *Cancer* 80: 50-59.
6. [http://www.mheresearchfoundation.org/files/MHERF\\_chondro.pdf](http://www.mheresearchfoundation.org/files/MHERF_chondro.pdf)