

# Comparison of Computer Tomography and 3D Rotational Angiography of the Left Atrium before Atrial Fibrillation Catheter Ablation; Radiation Exposure, Contrast Agent Consumption and Cost Effectiveness

Zdeněk Stárek<sup>1\*</sup>, František Lehar<sup>2</sup>, Jiří Jež<sup>2</sup>, Jiří Wolf<sup>2</sup>, Tomáš Kulík<sup>2</sup> and Alena Žbáňková<sup>2</sup>

<sup>1</sup>International Clinical Research Center, 1st Department of Internal Medicine–Cardioangiology, St. Anne's University Hospital Brno, Pekařská, Czech Republic

<sup>2</sup>Faculty of Medicine, Masaryk University, Kamenice, Czech Republic

\*Corresponding author: Zdeněk Stárek, International Clinical Research Center, 1st Department of Internal Medicine – Cardioangiology, St. Anne's University Hospital Brno, Pekařská 53, 656 91 Brno, Czech Republic, Tel: 543182187; Fax: 543182205; E-mail: Zdenek.starek@fnusa.cz

Received date: November 28, 2015; Accepted date: December 11, 2015; Published date: December 14, 2015

Copyright: © 2015 Stárek Z, et al. This is an open-access article distributed under the terms of the Creative Commons Attribution License, which permits unrestricted use, distribution, and reproduction in any medium, provided the original author and source are credited.

## Abstract

**Background:** Catheter ablation of complex atrial arrhythmias guided by 3D models of the left atrium (LA) derived from CT/MRI or 3D rotational angiography of the heart (3DRA) is currently a common practice. Our aim is to compare radiation dose, consumption of contrast agent and cost of these methods.

**Materials and methods:** Over the period from October 2011 to October 2014, either 3DRA or CT of the LA was performed in 314 patients referred to complex atrial arrhythmias ablation. 3DRA (157 patients) was done according to the LA protocol using the X-ray system Philips Allura FD 10, CT (157 patients) using 64-slice CT GE Light speed VCT. All procedures were monitored for average effective dose and dose of the contrast agent. For both methods, analysis of the financial costs was conducted.

**Results:** The average effective radiation dose for 3DRA was  $2.11 \pm 0.392$  mSv compared to  $10.52 \pm 2.093$  mSv for CT. The contrast agent consumption was 22.2 mg of iodine compared to 48.4 mg of iodine in CT. Total price per procedure is 123 € for 3DRA and 162 € for CT.

**Conclusion:** Consumption of the contrast agent and radiation burden for 3DRA of the left atrium is significantly lower than most currently used CT scan methods. The advantage of a lower X-ray dose and contrast agent compared to CT of the heart is relative and with new generations of CT devices, both methods will be comparable. Cost of the both methods is comparable; 3DRA is slightly less expensive than CT.

**Keywords:** Radiation risk; 3D cardiac rotational angiography of the left atrium; Computer tomography; Complex atrial arrhythmias; Catheter ablation of arrhythmias; Image integration

## Introduction

Atrial fibrillation is the most common supraventricular arrhythmia, and in recent years, catheter ablation of atrial fibrillation has become the most common ablation of all [1]. Complex ablation procedures are performed under the guidance of 3D electro anatomical mapping systems creating 3D non-fluoroscopic maps of the left atrium [2]. Currently, the two basic systems are being used (CARTO, Biosense Webster, and EnSite Velocity, St. Jude Medical).

Mapping of left atrium guided by 3D X-ray models of LA provides objective information on the real anatomy of the LA is currently common. The standard method used currently is contrast enhanced computer tomography (CT) of the left atrium. [3].

3D Rotational Angiography (3DRA) represents a new alternative to CT cardiac imaging. Images created by the rotational angiography of the heart are fully comparable with CT images [4-6]. The advantage of the cardiac rotational angiography is in the flexibility of creation of the model of the left atrium (3DRA can be provided periprocedurally at

time of ablation procedure), reduction of radiation dose and amount of the contrast agent.

Use of the final images in support of RFA is identical for both the CT and cardiac rotational angiography–support of creation of non-fluoroscopic 3D electro anatomic maps, direct fusion/integration with 3D electro anatomical mapping system, [3,5] and/or direct fusion/integration of a 3D model with live fluoroscopy [7].

Both methods, CT and 3DRA, have considerable burden of the patient with radiation and contrast agent and also their cost is not inconsiderable. The objective of this study is to compare radiation dose, consumption of contrast agent and cost of these methods on a large set of patients with 3DRA and CT of the left atrium.

## Materials and Methods

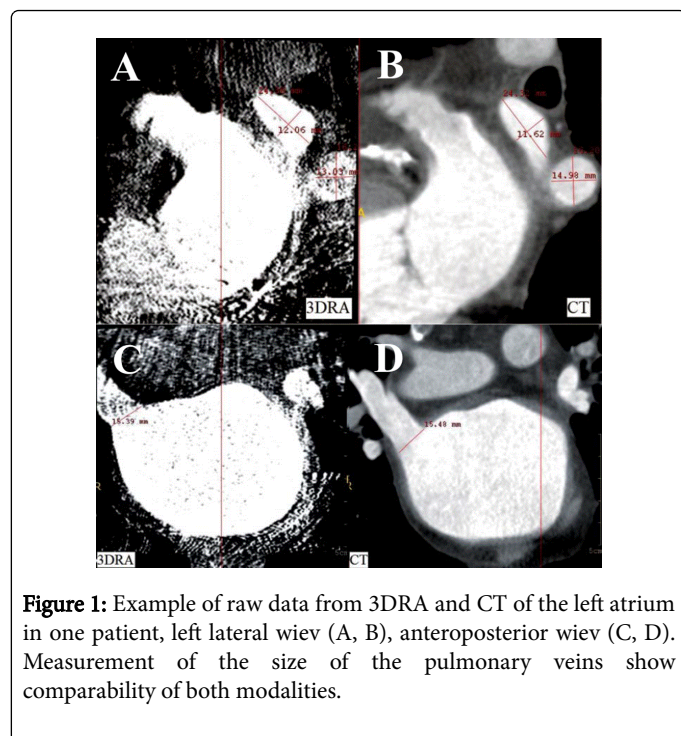
### Patient population

We performed a retrospective study enrolled 314 patients referred for catheter ablation of complex atrial arrhythmias between October 2011 and October 2014. All patients underwent either CT or 3DRA of the left atrium. Patients with a history of iodine allergy or with impaired renal function (MDRD/Modification of Diet in Renal Disease of less than 45 ml/s/1.73 m<sup>2</sup>) were excluded from the study.

## Rotational angiography imaging

In all procedures, imaging was carried out with X-ray system Allura Xper FD 10 (Philips Medical Systems Inc., Best, The Netherlands). The basic principle of the 3DRA is injection of contrast agent (Ultravist 370, Bayer Pharma AG, Berlin, Germany) to the atrium and acquiring the rotational image. After opacification of the left atrium and pulmonary veins, the C-arm was isocentrically rotated over 240° (120° right anterior oblique to 120° left anterior oblique) over 4.1 seconds with an X-ray acquisition speed of 30 frames per second. The patients were in a lying position during rotational imaging with natural position of the arms along the body and normal breathing. Pigtail catheter was introduced to the left atrium over the transeptal sheath Agilis NxT 8,5F. Left atrium isocentering was achieved from two X-ray projections AP and LL.

Cardiac output was significantly reduced with right ventricular stimulation at a frequency of 230 bpm with a significant drop in blood pressure, verified by the disappearance of the pulse waveform of the saturation sensor at the distal finger phalanx of the right upper extremity (Philips IntelliVue MP-20, Philips, Eindhoven, The Netherlands.) After this drop of saturation we initiated the application of the contrast agent (amount 60 ml, velocity of injection 15 ml/s) and with a delay of two seconds we commenced the rotation of C-arm [5]. Injection of contrast agent was carried out with standard power injector (Mark V, Medrad Inc., Indianola, PA, USA) [6]. Example of data from DRA and CT of the LA see Figure 1.



At the end of the rotational angiography, the data were automatically transported from the Allura X-ray System to the workstation EP Navigator (EP Navigator 3.1, Philips Healthcare, Best, The Netherlands). The 3DRA model of left atrium and pulmonary veins anatomy was automatically reconstructed using the standard algorithms of the EP Navigator Workstation.

## CT imaging

A CT scan was performed using the ECG nongated protocol on a 64-slice CT (GE Lightspeed VCT, General Electric, Fairfield, USA). CT parameters included: 120 kV, 800 mAs, collimation of  $63 \times 0.625$  mm, and spiral pitch factor of 0.98. Image reconstruction was performed on a  $512 \times 512$  pixel array. Contrast agent was administered through a peripheral vein (Ultravist 370, Bayer Pharma AG, Berlin, Germany). During the procedure, the patient had to have their arms up whilst holding the breath. The procedure was done a few days before catheterisation. The data was burned onto CD-ROM and during the procedure a 3D reconstruction of the left atrium using a workstation EP Navigator (EP Navigator 3.1, Philips Healthcare, Best, Netherlands) was created from acquired data.

## Radiation exposure, dose of contrast agent, cost effectiveness

For all 3DRA procedures we determined the average radiation dose (DAP-dose area product,  $\text{mGycm}^2$ ) and consumption of the contrast agent. For CT procedures average radiation dose was determined as a DLP (dose length product,  $\text{mGycm}$ ). The average radiation dose was converted to an effective dose (ED) using the appropriate converting factor. For 3D rotational angiography where the dose was measured in DAP units, 'dose area product' ( $\text{mGycm}^2$ ), a converting factor of  $0.18 \text{ mSv Gy}^{-1}\text{cm}^{-1}$  was used [8]. For CT, where the dose was given in units of DLP 'dose length product' ( $\text{mGycm}$ ), a converting factor of  $0.017 \text{ mSv mGy}^{-1}\text{cm}^{-1}$  was used [9]. In the same group of patients we compared the quantity of the contrast agent used. Given that in CT scans performed at another site, another type and concentration of contrast agent was used, the doses of the contrast agent were converted to mg of iodine.

Analysis of the financial costs was conducted by the economics department at the University Hospital of St. Anne, Brno and may represent conditions that apply in most hospitals in the Czech Republic in 2014. Technical fees and wages of individual workers (physicians, biomedical engineers, technicians and nurses) were included in the analysis. Technical fee includes the consumables and depreciation of individual devices. Consumables include, in particular, the contrast agent and other small supplies. Depreciation of equipment constituting the main part of the price of the performance was calculated from the cost of equipment and prices for service. For angiography, the Allura FD 10 service is included in the price of the device. In CT scan equipment, the price of the service is 93364 €/year. Lifetime of both devices is calculated at five years and depreciation is calculated for an eight-hour working week. Turnaround time for both technologies was set at 15 minutes. The prices are converted to Euros using the exchange rate as of November 2014 (27.58 CZK/€).

## Image integration, ablation procedures

The resulting 3DRA model of the left atrium was automatically integrated with the live fluoroscopy [7]. In the case of procedures guided by 3D electro anatomical mapping systems, we used 3D models of the LA as a guidance of creation of 3D electro anatomical map in form of synchronised projection of 3DRA model and 3D electro anatomical mapping system or direct fusion of 3D models with 3D electro anatomical map [3,5]. Ablation procedures were performed in a standard manner using irrigated tip catheter guided by 3D electro anatomical mapping system, EnSite Velocity (St. Jude Medical, St. Paul, MN, USA).

### Statistical analysis

Statistical analysis of clinical data set was performed using STATISTICA software (data analysis software system), StatSoft, Inc. (2013), version 12, www.statsoft.com. The statistical analysis was performed by the Kolmogorov-Smirnov test of normality and by the unpaired two sample Student's t-test. The significance level value for both types of statistical analysis was set to value 0.05.

### Results

In the period from March 2012 to October 2014 a total of 157 patients were examined with multislice CT of the heart with

segmentation of 3D model of left atrium. In the period from October 2011 to October 2014 a total of 157 of 3D rotational angiographies of the left atrium in patients prior to catheter ablation of complex atrial arrhythmias, in most cases atrial fibrillation, were performed.

Characteristics of patients are summarised in Table 1. 3DRA and CT group was without statistical significant differences. Nearly three-quarters of the patients were males with a mean age of 60 years and BMI almost 30. Most patients had no structural heart disease with normal left ventricle function and slightly enlarged left atrium.

Patients characteristics	3DRA of the left atrium	CT of the left atrium	
Number of patients	157	157	
Age	59,42 +/- 9,72	59,87 +/- 10,45	p=1,000
Males	117 (74,77%)	113 (71,52%)	p=0,626
EF of LV	57,26 +/- 7,04	57,11 +/- 8,18	p=1,000
Size of left atrium	44,23 +/- 5,25	44,82 +/- 5,73	p=1,000
Body mass index	29,82 +/- 9 ,14	29,49 +/- 8,29	p=1,000
Structural heart disease	29 (18,47%)	31 (19,75%)	p=0,679
Hypertension	94 (59,87%)	99 (63,06%)	p=0,224
Atrial fibrillation	143 (91,08%)	139 (88,53%)	p=0,254
Paroxysmal Afib	98 (68,53%)	98 (70,50%)	p=0,770
Persistent Afib	45 (31,47)	41 (29,50%)	p=0,784
Atypical left atrial flutter	12 (7,64%)	13 (8,28%)	p=0,240
Focal left atrial tachy	2 (1,27%)	3 (1,91%)	p=1,000

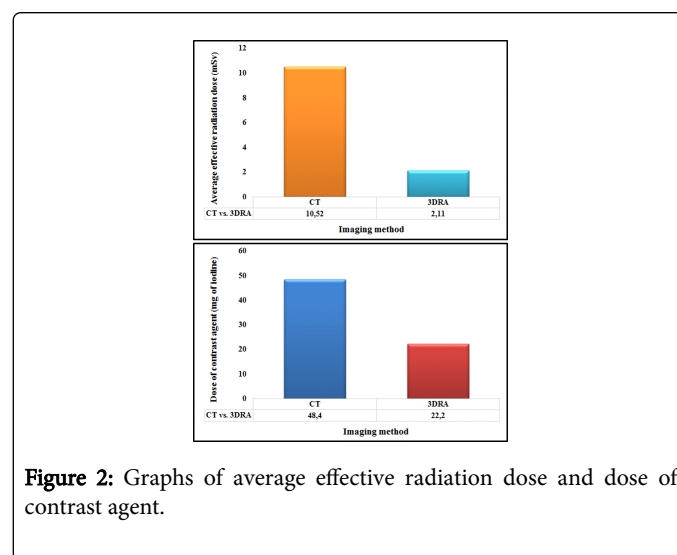
**Table 1:** Table of patient characteristics.

### Radiation exposure, dose of contrast agent, cost effectiveness

The average radiation dose (DAP-dose area product) for 3DRA of LA was 11746 +/-2178 mGycm<sup>2</sup>. The average radiation dose (DLP - dose length product) for CT of LA was 619 +/- 123 mGycm. Average consumption of contrast agent for 3DRA of LA was 60 ml, for CT of LA was 124.5 ml.

When comparing the average effective dose of radiation burden we showed a statistically significant reduction of radiation for 3DRA compared to the CT scan of the heart (2.11 ± 0.392 mSv vs. 10.52 ± 2.093 mSv resp., p<0.001) (Figure 2).

The average dose of the contrast agent used in 3DRA of the left atrium was 22.2 mg of iodine compared to 48.4 mg of iodine in CT imaging of the left atrium. Dose of the contrast agent in 3DRA was significantly lower (Figure 2).



**Figure 2:** Graphs of average effective radiation dose and dose of contrast agent.

Total price per procedure, including salaries of personnel is 123 € for 3DRA and 162 € for CT, the overall technical fee is 111 € for 3DRA and 151 € for CT (Table 2).

Financial costs/€	X-ray system Allura Xper FD 10+injector+workstation EP Navigator	CT GE Lightspeed VCT+injector+workstation HP WORKSTATION X28200
Purchase price	881 327	1 252 538
Maintenance and service/year	0	93 364
Total depreciation/15 min	22	42
Consumables	89	108
Total technical fee	111	151
Salaries	12	11
Total cost	123	162

**Table 2:** Table of cost 3DRA and CT of the left atrium.

### Catheter ablation guided by 3DRA and CT of the left atrium

All patients with the 3DRA model of left atrium were solved with the support of direct overlay 3D model and 2D fluoroscopy. Seven patients with CT model and nine patients with 3DRA model of the left atrium were ablated under the guidance of the 3D model of the left atrium directly fused with 3D electro anatomic map system. Rest of patients were ablated with the support of 3D EnSite Velocity maps creation with 3D model of the left atrium simultaneously displayed in the 3D electro anatomic mapping system.

### Discussion

The modern 3D X-ray imaging methods make the catheter ablations of complex atrial arrhythmias easier and safer and are commonly used in these procedures. Both used methods, CT and 3DRA, are expensive and have not inconsiderable burden of the patient with radiation and contrast agent.

In our cohort, we demonstrated a significantly lower radiation burden and consumption of contrast agent in 3DRA compared to CT. In published studies the effective dose for 3DRA was an average of 2.3 +/- 0.3 mSv compared to 19.5 +/- 3.1 mSv for CT models [6,10,11]. An explanation for the significantly higher dose for CT models of the left atrium vs. CT scanning in our patients is based on the methodology of CT scanning. In the cited studies there was always retrospective ECG gated CT, whereas in our cohort we used ECG nongated protocol leading to less radiation exposure to the patient. Thorning et al. [12] measured an average effective dose for retrospective ECG gated protocol of 13.45 mSv during the evaluation of pulmonary vein anomalies with CT, while for ECG nongated protocol was measured only 6.1 mSv. Even in the study of Ector et al. [13], the difference in average effective dose when using the retrospective ECG gated vs. nongated preprocedural cardiac CT was highly significant (3.17 mSv +/- 5.2 vs. 4.4 +/- 3 mSv; p<0.001).

Significantly lower consumption of the contrast agent for 3DRA in our cohort of patients correlate with published results. In the smaller studies comparing 3DRA and CT models of the left atrium, the average quantity of contrast agent used in 3DRA was almost half the amount of contrast agent used in CT (73 ml vs. 120 ml of contrast agent) [5,6,10,11,14,15].

A lower radiation dose and lower consumption of the contrast agent in 3DRA compared to the CT is relative, since there is intensive development of the most advanced CT imaging and the modern CT devices have significantly lower radiation burden and consumption of the contrast agent. In recent years, several studies have been published in which it was possible to decrease the radiation dose and consumption of contrast agent below the average of 3DRA. Blanke et al. [16] in 2010 published the results of CT of the left atrium in patients prior to catheter ablation using prospective ECG - triggered sequential dual-source CT scanner Somatom Definition, Siemens. The mean effective dose was 1.1 +/- 0.3 and 3.0 +/- 0.5 mSv (depending on tube voltage set on 100 and 120 kV according to BMI).

Yang et al. [17] described the first use of low dose 320-row CT Aquilion ONE, Toshiba for left atrium and pulmonary veins imaging. The effective dose was 1.90 ± 0.19 mSv, respectively 3.83 ± 0.31 mSv (tube voltage of 100 kV and 120 kV according to BMI). In addition to a significantly reduced effective dose less than half the amount of the contrast agent was used compared to older CT devices (40 and 50 ml according to BMI). At ECR 2014 (European Congress of Radiology 2014) the study of Fahlenkamp et al. [18] was mentioned, where using a non ECG triggered low-dose single-beat CT acquisition protocol on a 320-row CT Aquilion ONE, Toshiba was able to perform a CT scan of the left atrium before catheter ablation of atrial fibrillation with an average effective dose of 0.95 ± 0.57 mSv (at tube voltage of 100 kV).

The economic cost in the Czech Republic for 3DRA is lower than for CT, see Table 2 [14]. The difference of the total cost is 39 €, which is 24% of the price of the CT scan. Kristaselis et al. [15] in 2011 published a comparison of costs for the both methods in the Federal Republic of Germany. The authors calculated the price of one scan for 3DRA 91-95 € and 126-151 € for CT. In this case, the difference in cost is slightly greater and it constitutes 28-37% of the price of the CT imaging. This is mainly due to the mismatch in cost. In the study of Kritselis et al. for angiography the costs are very low, while for CT they are doubled in comparison with our devices. The total costs are difficult to compare; the overall technical fee in our department is 111 € for 3DRA and 151 € for CT and are slightly higher than those in the study of Kritselis et al. This is due to the fact that the depreciations in the study of Kritselis et al. are calculated for 6 years and based on a ten-hours working week, which make the costs lower. If we calculated the cost of

both centres according to the same formula, the result would be comparable. The question to consider is what would be the cost of this analysis in Germany if they counted the price of labour of the staff. In our calculations the price of labour is negligible (24 € and 47 €). It is a specific characteristic of Central European post-communist countries, where the cost of labour in healthcare services is underestimated. It is quite possible that after accounting for the cost of labour in Germany, the total cost would be completely different. Comparison of costs of individual methods between Czech and Germany is very difficult and can be misleading. However, we can conclude that both in our settings and settings of Western Europe, the technical fee for 3DRA are comparatively lower, than for CT. In our settings, the same applies for the total cost, including the cost of labour.

## Conclusion

Consumption of the contrast agent and radiation burden for 3DRA of the left atrium is significantly lower than most currently used CT scan methods. The advantage of a lower X-ray dose and contrast agent compared to CT of the heart is relative and with new generations of CT devices, both methods will be comparable. Cost of the both methods is comparable, 3DRA is slightly less expensive than CT. Comparing of cost between different countries is very difficult due to differences in methodology.

## Acknowledgement

This work was supported by the Grant of the European Regional Development Fund Project FNUSA-ICRC (No. CZ.1.05/1.1.00/02.0123). And Masaryk University, Faculty of Medicine, Kamenice 5, 625 00 Brno, Czech Republic.

## References

1. Calkins H, Kuck KH, Cappato R, Brugada J, Camm AJ, et al. (2012) 2012 HRS/EHRA/ECAS expert consensus statement on catheter and surgical ablation of atrial fibrillation: recommendations for patient selection, procedural techniques, patient management and follow-up, definitions, endpoints, and research trial design. *J Interv Card Electrophysiol* 33: 171-257.
2. Gepstein L, Hayam G, Ben-Haim SA (1997) A novel method for nonfluoroscopic catheter-based electroanatomical mapping of the heart. In vitro and in vivo accuracy results. *Circulation* 95: 1611-1622.
3. Malchano ZJ, Neuzil P, Cury RC, Holmvang G, Weichet J, et al. (2006) Integration of cardiac CT/MR imaging with three-dimensional electroanatomical mapping to guide catheter manipulation in the left atrium: implications for catheter ablation of atrial fibrillation. *J Cardiovasc Electrophysiol* 17: 1221-1229.
4. Orlov MV, Hoffmeister P, Chaudhry GM, Almasry I, Gijssbers GH, et al. (2007) Three-dimensional rotational angiography of the left atrium and esophagus--A virtual computed tomography scan in the electrophysiology lab? *Heart Rhythm* 4: 37-43.
5. Thiagalingam A, Manzke R, D'Avila A, Ho I, Locke AH, Ruskin JN, et al. (2008) Intraprocedural volume imaging of the left atrium and pulmonary veins with rotational X-ray angiography: implications for catheter ablation of atrial fibrillation. *J Cardiovasc Electrophysiol* 19: 293-300.
6. Li JH, Haim M, Movassaghi B, Mendel JB, Chaudhry GM, et al. (2009) Segmentation and registration of three-dimensional rotational angiogram on live fluoroscopy to guide atrial fibrillation ablation: a new online imaging tool. *Heart Rhythm* 6: 231-237.
7. Kriatselis C, Tang M, Nedios S, Roser M, Gerds-Li H (2009) Intraprocedural reconstruction of the left atrium and pulmonary veins as a single navigation tool for ablation of atrial fibrillation: a feasibility, efficacy, and safety study. *Heart Rhythm* 6: 733-741.
8. Schultz FW, Zoetelief J (2005) Dose conversion coefficients for interventional procedures. *Radiat Prot Dosimetry* 117: 225-230.
9. Einstein AJ, Moser KW, Thompson RC, Cerqueira MD, Henzlova MJ (2007) Radiation dose to patients from cardiac diagnostic imaging. *Circulation* 116: 1290-1305.
10. Tang M, Kriatselis C, Ye G, Nedios S, Roser M, et al. (2009) Reconstructing and registering three-dimensional rotational angiogram of left atrium during ablation of atrial fibrillation. *Pacing Clin Electrophysiol* 32: 1407-1416.
11. Kriatselis C, Tang M, Roser M, Fleck E, Gerds-Li H (2009) A new approach for contrast-enhanced X-ray imaging of the left atrium and pulmonary veins for atrial fibrillation ablation: rotational angiography during adenosine-induced asystole. *Europace* 11: 35-41.
12. Thorning C, Hamady M, Liaw JV, Juli C, Lim PB, et al. (2011) CT evaluation of pulmonary venous anatomy variation in patients undergoing catheter ablation for atrial fibrillation. *Clin Imaging* 35: 1-9.
13. Ector J, De Buck S, Huybrechts W, Nuyens D, Dymarkowski S, et al. (2008) Biplane three-dimensional augmented fluoroscopy as single navigation tool for ablation of atrial fibrillation: Accuracy and clinical value. *Heart Rhythm* 5: 957-964.
14. Lehar F, Starek Z, Jez J, Novak M, Wolf J, et al. (2013) Rotational atriography of left atrium – a new imaging technique used to support left atrial radiofrequency ablation. *Interv Akut Kardiol* 12: 184-189.
15. Kriatselis C, Nedios S, Akrivakis S, Tang M (2011) Intraprocedural imaging of left atrium and pulmonary veins: a comparison study between rotational angiography and cardiac computed tomography. *Pacing Clin Electrophysiol* 34: 315-322.
16. Blanke P, Baumann T, Langer M, Pache G (2010) Imaging of pulmonary vein anatomy using low-dose prospective ECG-triggered dual-source computed tomography. *Eur Radiol* 20: 1851-1855.
17. Yang L, Xu L, Yan Z, Yu W, Fan Z, et al. (2012) Low dose 320-row CT for left atrium and pulmonary veins imaging--the feasibility study. *Eur J Radiol* 81: 1549-1554.
18. Fahlenkamp UL, Schurig J, Vogtmann T, A. Lembecke, C.Schwenke, et al. (2014) Low-Dose Computed Tomography Angiography for Preablation Imaging of the Left Atrium: Intraindividual Comparison to Magnetic Resonance Angiography. *EPOS*.