

Dose-Dependent Effects of Paraquat on C-reactive protein, Some Lipid Profile Parameters and Histology of Tissues in Male Albino Rats

Akinloye OA*, Abioye OA, Olaojoyetan OE, Awosika OT and Akinloye DI

Department of Biochemistry, Federal University of Agriculture, P.M.B 2240, Abeokuta, Nigeria

Abstract

Paraquat is a highly toxic and widely used herbicide with no antidote. Its toxicity in man and animals has been reported to cause severe acute and long term health problems which eventually could lead to death. Measurement of blood C-Reactive Protein level (CRP) serves as a useful screen for infections and inflammatory diseases. Since it is known that paraquat exerts its toxic effects through generation of reactive oxygen species which causes injury to the cells thereby causing inflammation, this study was designed to determine the dose-dependent effects of paraquat on C-reactive protein, cholesterol, triglycerides and histology of liver and kidney in rats. Thirty albino rats weighing between 150 g and 200 g grouped into five groups of six rats in each were used. Rats in group A serves as control and were given feed and water only freely. Rats in group B, C, D and E were treated orally with 15 mg/kg (below sub-lethal dose), 25 mg/kg (sub-lethal dose), 35 mg/kg (below lethal dose) and 45 mg/kg (below lethal dose) of paraquat dichloride respectively for a period of fourteen days. The blood plasma collected was analyzed for CRP (using an immune-turbidimetric assay method), cholesterol and triglycerides while liver and kidney excised from sacrificed rats were used for histopathological studies. The result obtained showed that the concentration of CRP (12.38 ± 0.09 mg/L), cholesterol (8.61 ± 0.49 mg/L) and triglycerides (189.47 ± 2.59 mg/L) in control group was significantly lower ($p < 0.05$) than the other groups. The higher the concentration of paraquat administered, the higher its toxicity and the higher the levels of CRP, cholesterol and triglycerides. Histopathological findings revealed some pathologic conditions ranging from diffuse vacuolar degeneration of hepatocyte and glomerular mesangiolysis in the liver and kidney of paraquat-treated group respectively. This present study therefore suggests that the induction of inflammation and oxidative damage by paraquat could be accompanied by elevated C-reactive protein, cholesterol and triglycerides in albino rats.

Keywords: Dose-dependent; Paraquat; C-reactive protein; Biochemical parameters; Histology

Introduction

Paraquat (PQ) is a non-selective contact herbicide discovered in 1955 and was registered as herbicide in 1962 by ICI laboratories [1]. Chemically paraquat is 1,1'-dimethyl-4,4'-bipyridinium dichloride [2]. It is a widely used and effective herbicide with a broad spectrum of activity. Paraquat has been reported to be highly toxic to humans and animals with many cases of acute poisoning and death [3,4]. It was described as a major suicide agent in many countries not only because it is highly acutely toxic but also because it is readily available, relatively cheap and no known antidote exist [5]. For instance, paraquat intoxication was reported in Korea [6], while fatality rates for intentional paraquat ingestion were reported to range from 58% in Fiji [7], nearly 80% in Southern Mexico [8]. Forensic analysis of fatal intentional poisoning in South Trinidad showed that in 105 deaths from poisoning in 1996-97, paraquat was the causative agent in 80 cases (76%) [9]. Also, paraquat was banned in Samoa for being used as a suicide agent in about 70% of all suicide cases between 1999-2000 [10]. However, Garnier et al. [11] reported that poisoning as a result of accidental ingestion was rare in Europe not only because of effective and improved training of the user but also due to addition of alerting and emetic agents to commercial products of paraquat [11].

C-reactive protein (CRP) was so named because of its capacity to bind and precipitate the somatic C-polysaccharide of pneumococcus [12]. It is an exquisitely sensitive systemic marker of inflammation that results from infectious diseases, tissue damage, malignancy and various non-infectious ailments [13,14]. CRP is an acute phase protein produced primarily in the liver in response to stimulation by interleukin 6 (IL-6) [15]. Some authors have reported an association between elevated serum CRP levels and cardiovascular diseases [13,16,17]. More so, cholesterol and triglycerides are fats normally found in the body and

are important as intermediary substances for normal body function. High levels of cholesterol [18] and triglycerides [19] have been linked with cardiovascular diseases.

Previous advances in understanding CRP have led to discovery that elevated levels of CRP is a reliable predictor of cardiovascular events in several populations [20,21], and cholesterol and triglycerides are known atherogenic index while previous studies generally reported the acute toxic effects of the paraquat. Therefore, the present study was designed to evaluate the dose-dependent effects of paraquat on C-reactive protein, cholesterol, triglycerides and histology of organs of biotransformation (i.e., kidney and liver).

Materials and methods

Chemicals

Paraquat dichloride was purchased from the Ogun-State Agricultural Development Programme (OGADEP), Abeokuta, Nigeria. C-reactive protein (CRP) kit was obtained from Cypress diagnostics (UK), while cholesterol and triglycerides kits were the products of Fortress diagnostics. All other chemicals were of analytical grade.

***Corresponding author:** Dr. Akinloye OA, Department of Biochemistry, Federal University of Agriculture, P.M.B 2240, Abeokuta, Nigeria, Tel: +2348030824063; E-mail: oaakin@yahoo.com

Received January 02, 2013; **Accepted** January 28, 2013; **Published** January 31, 2013

Citation: Akinloye OA, Abioye OA, Olaojoyetan OE, Awosika OT, Akinloye DI (2013) Dose-Dependent Effects of Paraquat on C-reactive protein, Some Lipid Profile Parameters and Histology of Tissues in Male Albino Rats. Biochem Physiol 2:106. doi:10.4172/2168-9652.1000106

Copyright: © 2013 Akinloye OA, et al. This is an open-access article distributed under the terms of the Creative Commons Attribution License, which permits unrestricted use, distribution, and reproduction in any medium, provided the original author and source are credited.

Experimental animals

Thirty healthy male albino rats of wistar strain weighing between 150 and 200 g were procured from the Animal House of the College of Veterinary Medicine, Federal University of Agriculture Abeokuta, Nigeria. These rats were treated in accordance with the internationally accepted principles for laboratory animal use and care. They were housed in standard cages, under clean environmental conditions ($23 \pm 1^\circ\text{C}$, with $55 \pm 5\%$ humidity and 12 h/12 h light/dark cycles), fed with rat chow and water *ad libitum* and allowed to acclimatize for seven days.

Experimental design and animal treatment

The animals were divided into five (5) groups of 6 animals per group. Group A served as control and were given distilled water corresponding to the highest amount of extract administered. Groups B, C, D and E were given graded levels of sub-lethal doses of paraquat i.e., 15, 25, 35 and 45 mg/Kg body weights respectively for fourteen days. All animals were allowed free access to feed and water *ad libitum*. The rats were sacrificed at the end of the 15th day after overnight fast under diethyl ether anesthesia. Blood samples were collected via cardiac puncture into clean EDTA bottles. These were centrifuged at 4000 rpm for 10 minutes for plasma preparation for CRP, cholesterol and triglycerides assay. The animals were then dissected and livers and kidneys excised, mopped and preserved in Bouin fluid prior to histopathological examinations.

Biochemical assays

C-reactive protein (CRP) determination: Plasma C-reactive protein concentration was determined using an immune-turbidimetric assay according to the method described by Hirshfield and Pepys using Cypress diagnostics reagent kits [13].

Cholesterol and Triglycerides determination: Cholesterol and triglyceride concentrations were determined according to the methods of Jaffe [22] and Allain et al. [23] respectively using Fortress diagnostics kits.

Histopathological studies: The livers and kidneys harvested from the sacrificed rats were fixed in Bouin fluid (5% picric acid+10% formalin+5% acetic acid) embedded in paraffin and then stained with hemotoxylin and eosin (HE). Preparations were evaluated with a light field microscope and were photographed (Olympus, CS21).

Statistical analysis: Values were expressed as Mean \pm Standard Error of Mean. The level of homogeneity among the groups was tested using Analysis of Variance (ANOVA). Where heterogeneity occurred, the groups were separated using Duncan Multiple Range Test (DMRT). All analysis was done using Statistical Package for Social Science (SPSS) version 16.0.

Results

The results of the effects of paraquat on the plasma CRP, cholesterol and triglycerides levels in treated rats are presented in table 1.

Values are expressed as mean \pm SEM. Values along the same column with different superscripts are significantly different at $p < 0.05$.

It was observed that in all the parameters determined, there was a difference between the control group (A) and other groups (B, C, D, and E). As the concentration of paraquat administered increase, the levels of these parameters also increases. The higher the concentration of paraquat administered, the higher the increase in the level of the parameters observed. The control group (group A) showed a normal mean value of 12.49 ± 0.23 mg/L for the plasma CRP, while the

Group/parameter	CRP (mg/L)	Triglycerides (mg/L)	Cholesterol (mg/L)
Group A (Control)	12.38 ± 0.09^a	189.47 ± 2.59^a	8.61 ± 0.49^a
Group B (15 mg/Kg b.wt PQ)	$12.91 \pm 0.14^{a,b}$	191.49 ± 1.49^a	12.61 ± 0.75^b
Group C (25 mg/Kg b.wt PQ)	14.81 ± 0.27^b	194.28 ± 1.03^b	13.45 ± 0.97^b
Group D (35 mg/Kg b.wt PQ)	14.32 ± 0.81^c	196.14 ± 2.05^b	15.43 ± 2.56^c
Group E (45 mg/Kg b.wt PQ)	18.82 ± 1.12^b	196.91 ± 1.69^b	19.35 ± 0.67^d

Table 1: Effects of various doses of paraquat on plasma CRP, cholesterol and triglycerides of rats.

successive groups showed a significant increase in the levels of CRP with 18.82 ± 1.12 mg/L showing the highest level of CRP of value.

Also, cholesterol and triglyceride concentrations in the treated groups when compared to the control showed significant ($p < 0.05$) increases in their levels with the highest values of 196.91 ± 1.69 mg/L and 19.35 ± 0.63 mg/L for triglyceride and cholesterol respectively as observed in group administered highest concentration of PQ. Although, there was no significant difference triglycerides levels between groups A and B and among groups C, D and E.

The liver and kidney sections of group A, B, C, D and E were presented in plates 1a-1e and 2a-2e, respectively (figures 1a-1e), (figure 2a-2e). Plate 1a-1e shows the results of histology of liver tissues for the different groups (A-E). Plates 2a-2e shows the results of histology of kidney tissues for the different groups of rats.

Discussion

Paraquat (PQ) is highly toxic and enters the body mainly not only by swallowing or inhalation but also through damaged skin. The results from this study demonstrates that PQ treatment cause a significant increase in C-Reactive Protein (CRP), cholesterol and triglycerides levels as well as marked histological changes in liver and kidney as the dose of PQ increases down the group. This is similar to the report by Riahi et al. [24], which revealed that high dose of paraquat could suppress both cellular and humoral activity of the immune system while low dose did not show any changes in organ weight, body weight and spleen cellularity. Also, toxicity of paraquat evaluated by dermal application of $1/2$ LD₅₀ and $1/10$ LD₅₀ for five days each week for four weeks was reported to induce swelling of pneumocytes, thickening of interalveolar septa and infiltration with lymphocytes and macrophages [25].

The abnormal increase in the plasma CRP down the group with increased oral administration of PQ when compared to the control group is a sensitive indicator of hepatotoxicity or a diseased state. This may be due to degenerative changes and hypo-function of liver and kidneys as a result of consequent production of increased oxidative stress by PQ via generation of ROS. Paraquat induced toxicity is a manifestation of its ability to generate Reactive Oxygen Species (ROS). Bowels and Pond [26] revealed that PQ increase the production of certain oxygen derivatives that may harm cellular structure consequence of which could lead to increased oxidative stress, thus PQ toxicity can cause increased level of CRP. This indicates an inflammation caused by PQ toxicity. Pepys et al. [14] have demonstrated that CRP is an acute-phase protein and is an exquisitely sensitive systemic marker of inflammation and tissue damage. CRP may have significant pro-inflammatory effects and bind to ligands exposed on cells as a result of infection, inflammation, ischemia and other pathologies and triggering complement activation. It may also exacerbate tissue damage, leading to more severe diseases [14]. The increase in CRP level is found to be related to increased triglycerides level which can be related to a study

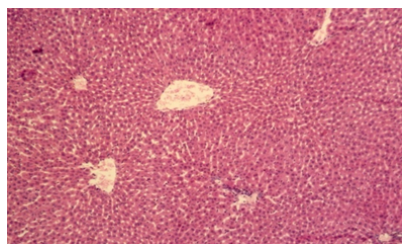


Figure 1a: Plate 1a: Liver section of control group of rats showing no visible lesion. ($\times 100$).

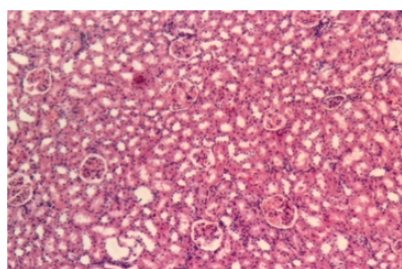


Figure 1b: Plate 1b: Liver section of rats administered below sub-lethal dose (15 mg/Kg) of PQ showing moderate diffuse vacuolar degeneration of the hepatocytes ($\times 100$).

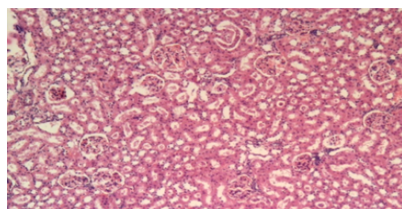


Figure 1c: Plate 1c: Liver section of rats administered sub-lethal dose (25 mg/Kg) of PQ showing moderate diffuse vacuolar degeneration of the hepatocytes. ($\times 100$)

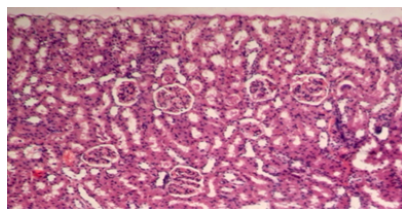


Figure 1d: Plate 1d: Liver section of rats administered below lethal dose (35 mg/Kg) of PQ showing marked vacuolar degeneration and necrosis ($\times 100$)

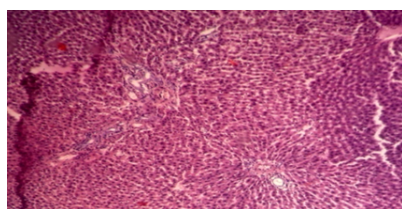


Figure 1e: Figure 1e: Plate 1e: Liver section of rats administered below lethal dose (45 mg/Kg) of PQ showing multiple foci of hepatic necrosis with evidence of regeneration such as cytomegaly and foci of bile duct proliferation ($\times 100$)

that shows that CRP is associated with lipid responses to low-fat and high-poly unsaturated fat diets [27].

The study also revealed that increase in PQ concentration is closely followed by a concomitant increase in cholesterol and triglycerides. These biomarkers can be regarded as reliable indicators of the severity and prognosis of acute poisoning. A significant increase in cholesterol and triglycerides level observed indicated that PQ could predispose an animal to the risk of coronary heart disease. The high levels of triglycerides may be due to lack of production of very Low density Lipoproteins (VLDL). Rye and Beisiegel reported that when these lipoproteins are not produced, triglyceride is not transported and this results in accumulation of triglycerides in the tissues [28]. The high cholesterol level observed may be attributed to high oxygen radicals generated and is also in agreement with the report of Adachi et al that PQ administration in rats led to high level of cholesterol [29]. Lee et al. [30] and Kimura et al. [31] also reported increased serum cholesterol in PQ-induced oxidative stress condition.

The liver and kidney are considered to be the principal target organs for PQ. In vertebrates, the liver is a highly metabolically active organ with a high activity of antioxidants and associated enzymes, so that it is the main organ responsible for detoxification of xenobiotics [32]. The toxic effects of paraquat on liver histology showed centrolobular cholestasis, hepatocellular necrosis and macrophagic infiltration of portal areas, with the portal tracts increased in size due to abundance of collagen stroma, slight infiltration by lymphocytes and leukocytes. This similar to the results of Bataller et al. [33]. These results clearly showed that PQ has a harmful and stressful influence on the hepatic and renal tissue and is quite consistent with the report of Dragain et al. in respect of paraquat liver toxicity [34].

Histological examination of the liver tissues in the control group (Group A) revealed a normal lobular structure with no visible lesion. However, dose-dependent changes were seen in the liver tissue samples from Group B to Group E. In the Group B (Below sub lethal), these changes were very mild and reversible. Similar changes were also seen in Group C (Sub lethal). In Group D (Below lethal) the changes seen compared with those in the Group B were aggressive and common: there was hepatocyte necrosis and marked vacuolar degeneration. Group E (Lethal) showed more aggressive changes: foci of bile duct proliferation, multiple foci of hepatic necrosis with evidence of regeneration such as cytomegaly which is similar to the findings of Gokcimen et al. which suggest that a high dose of paraquat causes cell damage, fibrous tissue proliferation, acute hepatitis and irreversible cell death [35].

The present results also showed that PQ induced many histological alterations in the kidney of rats. Examination of the kidney showed no visible lesion in the control group. The sub-lethal dose group showed a moderate tubular degeneration and cell death while the lethal dose group showed a severe glomerular disruption, tubular protein cast and kidney necrosis. This indicated that PQ caused damages to the kidney tissue but the severity increases as the concentration of PQ dose increases. Also, most of the renal blood vessels were more dilated, congested and engorged with blood with increasing PQ concentration establishing the dose-dependent toxicity. In the lethal dose group, most of the renal tubules were damaged and lost their characteristic appearance. Their lining epithelial cells became undistinguished and their contents were intermixed with each other (Plate 2e). The walls of Bowman's capsule were eroded and the glomeruli were atrophied and in some sections appeared as empty spaces containing amorphous cellular debris (Plate 2e). These results are similar to those previously reported by some researchers. For instance, Abdel-Mageid reported that kidney

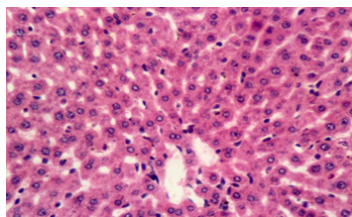


Figure 2a: Plate 2a: Kidney section of rats administered below sub-lethal dose (15 mg/Kg) of PQ showing no visible degradation and no necrosis of the tubular epithelial cells with normal architecture ($\times 100$)

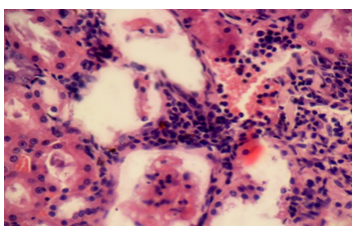


Figure 2b: Plate 2b: Kidney section of rats administered below sub-lethal dose (15 mg/Kg) of PQ showing moderate diffuse tubular vascular degradation, necrosis and diffuse glomerular mesangiolysis ($\times 100$)

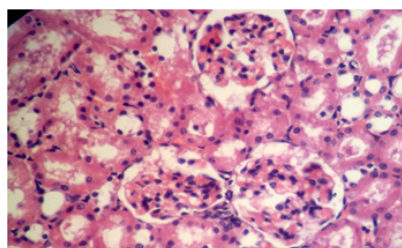


Figure 2c: Plate 2c: Kidney section of rats administered below sub-lethal dose (25 mg/Kg) of PQ showing moderate diffuse tubular protein cast in the tubules ($\times 100$)

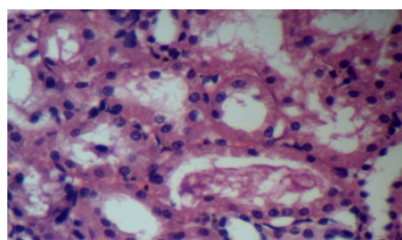


Figure 2d: Plate 2d: Kidney section of rats administered below sub-lethal dose (35 mg/Kg) of PQ showing severe glomerular mesangiolysis, necrosis and tubular degeneration ($\times 100$)

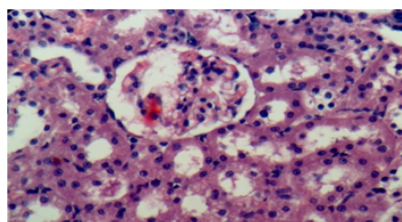


Figure 2e: Plate 2e: Kidney section of rats administered below sub-lethal dose (45 mg/Kg) of PQ showing marked more severe mesangiolysis, tubular degeneration and necrosis of tubular epithelial cells ($\times 100$)

of paraquat intoxicated rats revealed degeneration of renal tubules, shrunken glomeruli and congested dilated blood vessels [36]. Also, Damin et al. [37] emphasized that as a result of paraquat poisoning, renal damage occurs while the observed toxic effects of paraquat on liver histology as revealed by centrolobular cholestasis, hepatocellular necrosis and macrophagic infiltration of portal areas could be attributed to the fact that portal tracts increased in size due to abundance of collagen stroma, slight infiltration by lymphocytes and leukocytes as reported by Bataller et al. [33]. The results from this studies revealed that paraquat could elevate not only cholesterol and triglycerol but also C-reactive protein. Thus, confirming the fact that CRP levels increase during PQ-induced inflammatory conditions.

References

1. <http://www.inchem.org/documents/jmpr/jmpmono/v2003pr08.htm>
2. Roberts TR, Dyson JS, Lane MC (2002) Deactivation of the biological activity of paraquat in the soil environment: a review of long-term environmental fate. *J Agric Food Chem* 50: 3623-3631.
3. Bismuth C, Garnier R, Baud FJ, Muszynski J, Keyes C (1990) Paraquat poisoning. An overview of the current status. *Drug Saf* 5: 243-251.
4. Murray RE, Gibson JE (1972) A comparative study of paraquat intoxication in rats, guinea pigs and monkeys. *Exp Mol Pathol* 17: 317-325.
5. Dinham B (1996) Active Ingredient fact sheet. *Pesticide News* 32: 20-21.
6. Hwang KY, Lee EY, Hong SY (2002) Paraquat intoxication in Korea. *Arch Environ Health* 57: 162-166.
7. Booth H (1999) Pacific Island Suicide in comparative perspective. *J Biosoc Sci* 31: 433-448.
8. Tinoco R, Tinoco R, Parsonnet J, Halperin D (1993) Paraquat poisoning in southern Mexico: a report of 25 cases. *Arch Environ Health* 48: 78-80.
9. Hutchinson G, Daisley H, Simeon D, Simmonds V, Shetty M, et al. (1999) High rates of paraquat-induced suicide in southern Trinidad. *Suicide Life Threat Behav* 29: 186-191.
10. Le Samoa (2001) Paraquat and its connection with suicide. *Le Samoa Headlines*.
11. Garnier R, Bazire, A, Chatainer D (2003) Effets sur la Sante de l' utilization Professionnelle du paraquat. *Arch Des Mal Prof et de Med du Travail* 64: 310-314.
12. Tillet WS, Francis T (1930) Serological Reactions in Pneumonia With A Non-Protein Somatic Fraction of Pneumococcus. *J Exp Med* 52: 561-571.
13. Pepys MB, Hirschfield GM (2003) C-reactive protein: a critical update. *J Clin Invest* 111: 1805-1812.
14. Pepys MB, Baltz ML (1983) Acute phase proteins with special reference to C-reactive protein and related proteins (pentaxins) and serum amyloid A protein. *Adv Immunol* 34: 141-212.
15. Erlinger TP, Platz EA, Rifai N, Helzlsouer KJ (2004) C-reactive protein and the risk of incident colorectal cancer. *JAMA* 291: 585-590.
16. Kalsait RP, Khedekar PB, Saoji AN, Bhusari KP (2011) Role of C-Reactive Protein in the development of atherosclerosis in diet-induced lipidemia in albino rats. *Trop J of Pharmaceut Res* 10: 41-45.
17. Ridker PM (2003) Clinical application of C-reactive protein for cardiovascular disease detection and prevention. *Circulation* 107: 363-369.
18. Sadava D, Hillis DM, Heller HC, Berenbaum MR (2011). *Life: The Science of Biology* (9th edn.). WH Freeman, San Francisco, USA.
19. Kleinman Y, Eisenberg S, Oschry Y, Gavish D, Stein O, et al. (1985) Defective metabolism of hypertriglyceridemic low density lipoprotein in cultured human skin fibroblasts. Normalization with bezafibrate therapy. *J Clin Invest* 75: 1796-1803.
20. Libby P, Ridker PM, Maseri A (2002) Inflammation and atherosclerosis. *Circulation* 105: 1135-1143.
21. Gussekloo J, Schaap MC, Frölich M, Blauw GJ, Westendorp RG (2000) C-reactive protein is a strong but nonspecific risk factor of fatal stroke in elderly persons. *Arterioscler Thromb Vasc Biol* 20: 1047-1051.

22. Jaffe M (1984) Über den Wiederschlag Welchen Pikrinsäure in normalem Ham erzeugt und über eine neue Reaktion des kreatinins. *Physiol. Chem.* 10: 391-400.
23. Allain CC, Poon LS, Chan CS, Richmond W, Fu PC (1974) Enzymatic determination of total serum cholesterol. *Clin Chem* 20: 470-475.
24. Riahi B, Rafatpanah H, Mahmoudi M, Memar B, Brook A, et al. (2010) Immunotoxicity of paraquat after subacute exposure to mice. *Food Chem Toxicol* 48: 1627-1631.
25. Luty S, Latuszynska J, Halliop J, Tochman A, Obuchowska D, et al. (1997). Dermal toxicity of paraquat. *Ann Agric Environ Med* 4: 217-227.
26. Bowles MR, Pond SM (1990) The importance of electrostatic interactions in the binding of paraquat to its elicited monoclonal antibody. *Mol Immunol* 27: 847-852.
27. St-Onge MP, Zhang S, Darnell B, Allison DB (2009) Baseline serum C-reactive protein is associated with lipid responses to low-fat and high-polyunsaturated fat diets. *J Nutr* 139: 680-683.
28. Havinga JR, Lohse P, Beisiegel U (1987) Immunoblotting and ligand blotting of the low-density lipoprotein receptor of human liver, HepG2 cells and HeLa cells. *FEBS Lett* 216: 275-280.
29. Adachi J, Tomita M, Yamakawa S, Asano M, Naito T, et al. (2000) 7-Hydroperoxycholesterol as a marker of oxidative stress in rat kidney induced by paraquat. *Free Radic Res* 33: 321-327.
30. Lee WT, Chei TY, Kim CW (1991) A study on the changes in rabbit's serum protein, lipids and its electrophoretic changes in acute paraquat intoxication. *Hanyang Uidae Haksulchi. Hanyang Uidae Haksulch* 11: 421-440.
31. Kimura Y, Araki Y, Takenaka A, Igarashi K (1999) Protective effects of dietary nasunin on paraquat-induced oxidative stress in rats. *Biosci Biotechnol Biochem* 63: 799-804.
32. Hargus SJ, Amouzede HR, Pumford NR, Myers TG, McCoy SC, et al. (1994) Metabolic activation and immunochemical localization of liver protein adducts of the nonsteroidal anti-inflammatory drug diclofenac. *Chem Res Toxicol* 7: 575-582.
33. Bataller R, Bragulat E, Nogué S, Görbig MN, Bruguera M, et al. (2000) Prolonged cholestasis after acute paraquat poisoning through skin absorption. *Am J Gastroenterol* 95: 1340-1343.
34. Dragin N, Smani M, Arnaud-Dabernat S, Dubost C, Moranvillier I, et al. (2006) Acute oxidative stress is associated with cell proliferation in the mouse liver. *FEBS Lett* 580: 3845-3852.
35. Gokcimen A, Akdogan G, Karaoz E (2000) Structural and biochemical changes in liver and renal tissues induced by an acute high dose of diclofenac sodium in rats. *Biomed. Res.* 11: 293-302.
36. Abdel-Mageid, S.A. 1994. Structural changes in the kidney of albino rat in response to the administration of paraquat herbicide. *J. Egypt. Germ. Soc. Zool.*, 15: 153-175.
37. Frazen D, Baer F, Heitz W, Mecking H, Eidt S (1991) Failure of radiotherapy to resolve fatal lung damage due to paraquat poisoning. *Chest* 100: 1164-1165.