

Endoscopic Guided Tibiotalocalcaneal Arthrodesis After Failed Osteosynthesis of Pilon Fractures

Frederick Michels^{1,†}, Arne Burssens¹, Guy Putzeys¹, Jan Van Der Bauwhede¹ and Stéphane Guillo²

¹Orthopaedic Department, AZ Groeninge Kortrijk, Belgium

²Sports Clinic Bordeaux Mérignac, Mérignac, France

*Corresponding author: Dr. Frederick Michels, Orthopaedic Department, AZ Groeninge Kortrijk, Burg Verduysselaan 5, 8500 Kortrijk, Belgium, Tel: 0032 497 31 75 76; E-mail: frederick_michels@hotmail.com

Received date: Jan 30, 2014, Accepted date: Feb 25, 2014, Published date: Feb 27, 2014

Copyright: © 2014 Michels F, et al. This is an open-access article distributed under the terms of the Creative Commons Attribution License, which permits unrestricted use, distribution, and reproduction in any medium, provided the original author and source are credited.

Abstract

Pilon fractures are difficult to treat because of the fracture pattern and are usually associated with significant soft tissue injury, which may result in a series of complications. Patients with diabetes and sensory neuropathy are at even greater risk of fixation failure, skin flap necrosis and deep infection. Treatment of complicated situations in patients is even more challenging and often results in an amputation. We describe a surgical treatment in two steps. First, we recommend an aggressive debridement to eradicate infection. After recovery of soft tissues, hindfoot fusion with a retrograde intramedullary nail helps to obtain a stable fixation. The removal of the cartilage can be performed endoscopically. This minimizes new soft tissue damage and favours wound healing. This treatment provides the patient with a pain-free plantigrade foot for ambulation.

Keywords: Pilon fracture; Tibiotalocalcaneal arthrodesis; Retrograde nailing; Ankle arthroscopy; Diabetes; Infection; Minimally invasive

Introduction

Pilon fractures are usually associated with significant soft tissue injury caused by high energy trauma, which may result in a series of complications such as fixation failure, skin flap necrosis or deep infection [1,2]. Patients with underlying systemic diseases, such as diabetes, have an increased risk of developing these complications, which may result in failure of osteosynthesis [3].

Tibiotalocalcaneal (TTC) arthrodesis by retrograde nailing has been shown to be an adequate salvage in situations such as arthrosis and complex malalignment, failed ankle arthroplasty, or failed primary hindfoot fusion [4-8]. This technique is usually performed with an open approach and the complication rate is high in diabetic patients [9]. In case of a recent failed pilon fracture, the scarring and soft tissue damage following prior operations is significant. In our study we present two cases of a failed pilon fracture with associated osteomyelitis and deep infection. The use of an arthroscopic posterior approach limits soft tissue damage and encourages fusion [10].

Patients and Methods

Case 1

A 35-year-old male patient with Charcot-Marie-Tooth disease presented on the emergency department with an articular multifragmentary pilon fracture AO/OTA type C2 below an intramedullary tibia nail (Figure 1) [11].

The medical history revealed diabetes mellitus, morbid obesity and significant tobacco abuse. During the further course of treatment in compliance was noticed due to a reduced pain awareness as a consequence of his sensory neuropathy related to his Charcot-Marie-

Tooth disease. After two weeks of lower leg elevation to reduce the soft tissue swelling, a plate and screw osteosynthesis was performed. At one month of follow-up, a posteromedial dislocation of both talus and medial malleolus was noticed (Figure 1). A second plate osteosynthesis was performed with an external fixator left in place, due to the instability of the fracture. At three months of follow-up, a failure of the osteosynthesis occurred with recurrence of the posterolateral talus dislocation. The implants were removed and a culture was taken from the tibiotalar joint and surrounding tissues. Finally an osteomyelitis with significant avascular bone necrosis occurred. Culture results were positive for *S. aureus*.

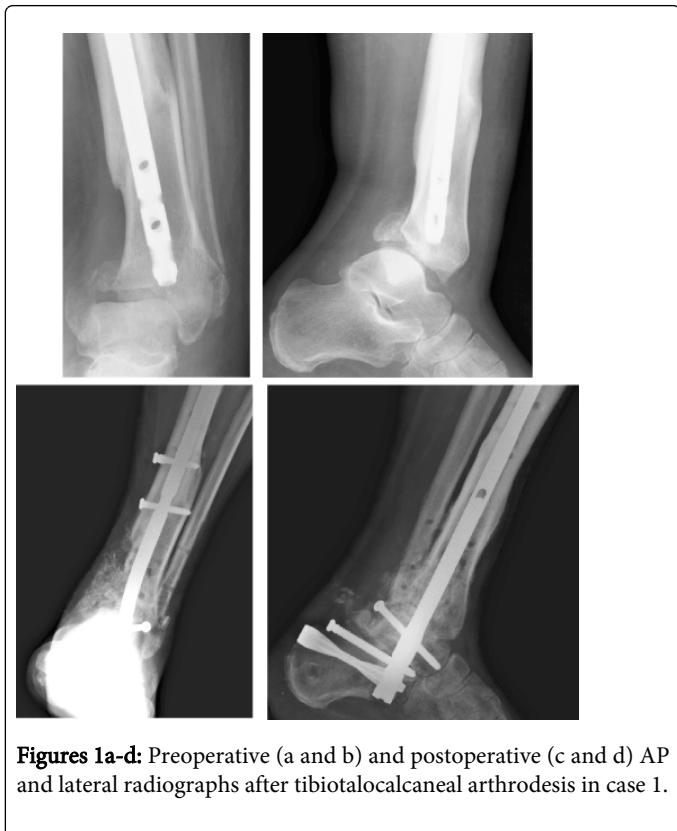An aggressive debridement was performed, removing all avascular infected bone and nonviable fibrotic tissue. The large bone defect was filled with an antibiotic-impregnated cement spacer (Figure 1).

Laboratory results and wound healing showed a favourable progress after two weeks of intra-venous antibiotics. Because of the unstable bone situation and the repetitive surgery damaging the soft tissues, an endoscopic guided TTC arthrodesis was planned.

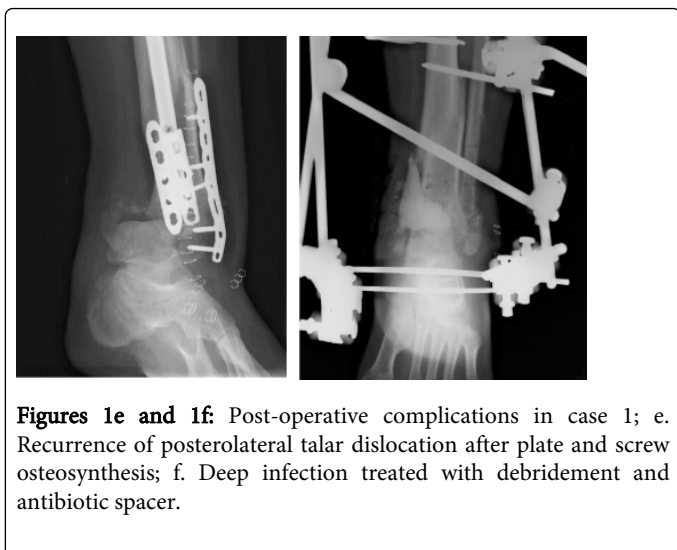
The patient was placed prone on the operating table with the foot and ankle extended slightly past the end of the table. No supports were used to allow a good access around ankle and distal tibia.

A 4.0 mm, 30 degree arthroscope was placed in a posterolateral portal. The posteromedial portal was used as an instrumental portal to remove the cartilage articular surface of the subtalar and subsequently the tibiotalar joint with shaver, chisels and curettes (Figure 2). Several holes were created in the subchondral bone to promote cancellous bleeding and improve arthrodesis. After cartilage removal from both joints an intramedullary K-pin was placed as a guide for the retrograde nail. Once a centralized position of the guide wire in talar dome through endoscopy was verified, the cement spacer was removed. The guide pin was moved into the distal tibia and the Hindfoot Arthrodesis Nail® (Synthes AG, Bettlach, Switzerland) was placed. The remaining bone defects were filled with antibiotic-impregnated autologous bone

grafts. Post-operative treatment consisted out of wound care, IV antibiotics for 2 weeks and non-weight-bearing with crutches for six weeks.



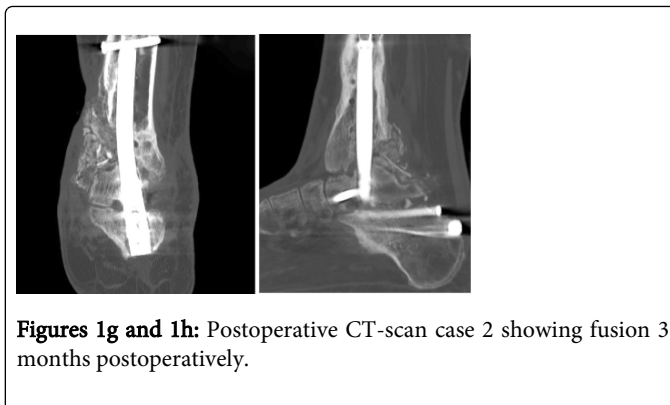
Figures 1a-d: Preoperative (a and b) and postoperative (c and d) AP and lateral radiographs after tibiototalcaneal arthrodesis in case 1.



Figures 1e and 1f: Post-operative complications in case 1; e. Recurrence of posterolateral talar dislocation after plate and screw osteosynthesis; f. Deep infection treated with debridement and antibiotic spacer.

At 6 weeks of follow-up, the patient achieved complete wound healing and partial weight-bearing was allowed. CT-scan confirmed fusion after 12 weeks (Figure 1).

The American Orthopaedic Foot and Ankle Society (AOFAS) hindfoot score improved from 25 to 76 [12].



Figures 1g and 1h: Postoperative CT-scan case 2 showing fusion 3 months postoperatively.

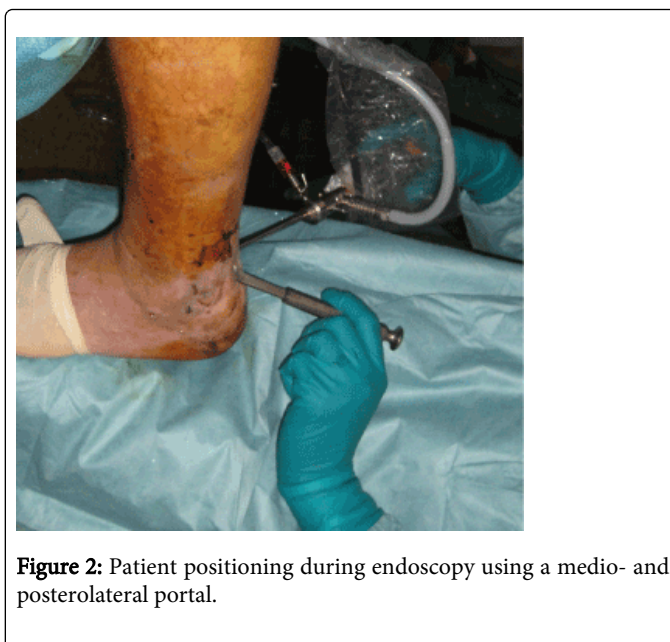


Figure 2: Patient positioning during endoscopy using a medio- and posterolateral portal.

Case 2

A 68-year old woman sustained a pilon fracture AO/OTA type C2 grade II open according to Gustilo and Anderson after falling down the stairs (Figure 3).

The medical history revealed an aortic valve transplantation for which she used oral anticoagulants and diabetes mellitus with a pronounced polyneuropathy in both lower limbs.

Initial treatment consisted of external fixation due to the complexity of the fracture and conditions of the soft tissues. This proved to be very unstable with recurrence of talar dislocation. An additional external fixation was required before converting to a plate and pin cerclage osteosynthesis.

After two months of casting and wound care, the patient was allowed to start partial weight-bearing using crutches and a walker boot. This resulted in a failure of fixation and a deep wound infection with positive cultures for *Staphylococcus epidermidis* (Figure 3). Because of the polyneuropathy she probably started full weight-bearing and didn't notice the seriousness of the situation. A debridement was performed with removal of the hardware. After wound healing a TTC arthrodesis was planned. An endoscopic removal of the cartilage of the

subtalar and the tibiotalar joint was performed. Subsequently, a PANTA® Arthrodesis Nail System (Integra, Plainsboro, NJ, USA) was placed. This procedure resulted in a stable fixation with only limited soft tissue damage. The patient healed without further wound problems. Non-weight-bearing was continued until 6 weeks postoperatively, followed by 6 weeks partial weight-bearing. Fusion was confirmed after 3 months (Figure 3). After 1 year of follow-up, the patient still had a good function with orthopaedic shoes and no complaints. The AOFAS hindfoot score improved from 8 to 66.

Discussion

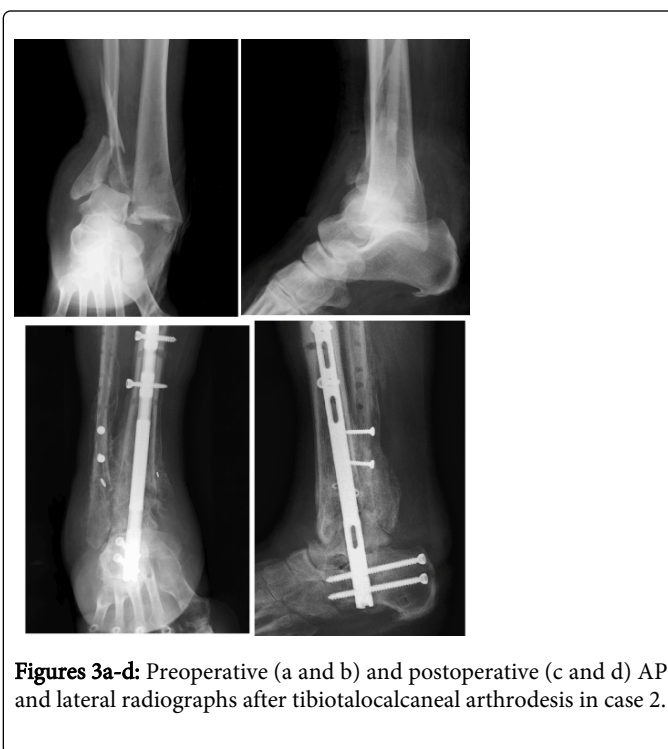This study illustrates the usefulness of an endoscopic guided tibiototalcalcaneal arthrodesis as a salvage procedure in an infected tibia pilon osteosynthesis in patients with associated diabetes and sensory neuropathy.

Pilon fractures are difficult to treat because of the fracture pattern and are usually associated with significant soft tissue injury, which may result in a series of complications. Patients with underlying systemic diseases, such as diabetes, have an increased risk of developing these complications [3]. Pilon non-unions, with a poor soft tissue envelop, infection and bone loss have limited treatment options and generally require external fixation [13]. Green and Roesler used Hoffman external fixators to treat 11 infected nonunions of pilon fractures [14]. The salvage rate was 56% (6 of 11). Zalavras and colleagues treated six infected nonunions of pilon fractures with a 3-stage technique [15]. First radical debridement and stabilization of the ankle with a bridging external fixator. Second soft tissue coverage with free muscle flaps. Finally ankle fusion using iliac crest bone graft. A fusion rate of 100% was achieved in six cases, but the external fixator had to be maintained for prolonged periods of time (5-14 months). This treatment required a compliant patient without any use of tobacco.

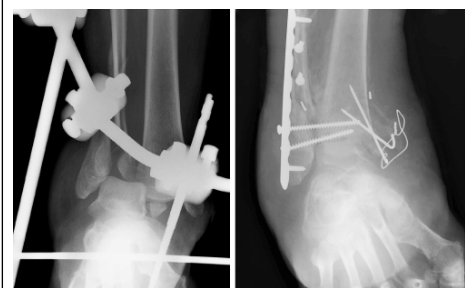
Hindfoot arthrodesis with intramedullary nailing is an effective technique for treating complex foot deformities in situations such as arthrosis and complex malalignment, failed ankle arthroplasty, or failed primary hindfoot fusion. Patient satisfaction is high, but the procedure is demanding and complications are frequent [6]. The advantages of TTCA are maintenance of alignment, length, and stability [7].

Complications after intramedullary nailing for tibiototalcalcaneal arthrodesis include wound dehiscence, infection, nerve injury, gait disturbances, malunion, and non-union [5]. Mendicino et al. published an overall complication rate of 70% with all major complications occurring in patients with diabetes mellitus [9]. In the case of a recent failed pilon osteosynthesis, the risk of wound problems is even greater due to the scarring following prior surgeries. The presence of an infection has been seen as a contra-indication for this procedure [16]. An infection was confirmed in our two patients. This was countered by performing surgery in two steps. The first step is an aggressive debridement to eradicate infection. The first step is an aggressive debridement to eradicate infection and the use of IV antibiotics [15,17,18]. An aggressive debridement with excision of all necrotic bone and removal of all hardware is the essential step of the treatment strategy [13]. Failure to eradicate infection probably is a result of inadequate initial debridement in an effort to preserve bone length [13]. Two weeks before the debridement, no oral or intravenous antibiotics are given. Obtaining an accurate culture of the infecting bacteria is essential. An infected nonunion may need second and third

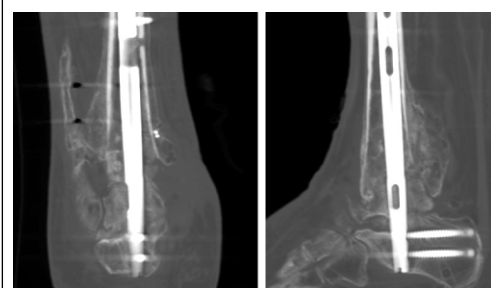
debridements. When the infected nonunion has clean bleeding tissue at the last debridement and has had 1 week of intravenous antibiotics, the distal leg is ready for reconstruction [13]. However complete eradication of infection is always difficult to confirm and a late recurrence is never ruled out. We recommend to follow the guidelines discussed above to diminish the risk of recurrence. In case of a large bone defect an antibiotic spacer can be used to offer stability and occupation of debrided area [17]. The use of debridement and implanting a cement spacer in a first episode followed by an endoscopic guided arthrodesis in a second episode has been demonstrated as a valid option to treat osteomyelitis after a calcaneus fracture [19]. The cement spacer offers stability and occupies the defect. After healing of the soft tissues the second step can be planned. The intramedullary nail offers a stable fixation. Usually an anteromedial or anterolateral approach is recommended [8]. Because of the high risk of complications, minimally invasive approaches have been described [8]. Preservation of the soft tissue, surrounding the tibiotalar and subtalar joint, results in maintenance of a good blood supply to the healing arthrodesis [20]. The endoscopic approach helps to avoid soft tissue problems and favours wound healing [10]. By arthroscopically de visu controlling resection down to subchondral bleeding bone and taking care not to alter the geometry of both joints, a maximum amount of bone mass is preserved and an optimal coaptation of the bone surface obtained [10]. This is advantageous in bony fusion. Despite the severity of our study population (diabetes, sensory neuropathy, morbid obesity, non-compliance), the failed pilon osteosynthesis and deep infection, the limb could be saved in both patients. A bony fusion could be obtained and the patient could ambulate with a stable plantigrade foot without soft tissue problems. In view of the type of patients, one could consider to perform the retrograde intramedullary nail fixation at the time of the index surgery. This would avoid soft tissue problems and diminish the risk to infection.



Figures 3a-d: Preoperative (a and b) and postoperative (c and d) AP and lateral radiographs after tibiototalcalcaneal arthrodesis in case 2.



Figures 3e and 3f: Post-operative complications in case 2 e. Recurrence of fracture dislocation after primary external fixation f. Recurrence of fracture dislocation despite plate and screw osteosynthesis.



Figures 3g and 3h: CT-scan case 2 showing fusion 3 months (h) postoperatively.

A disadvantage of this study was the short follow up making it difficult to point out if complete eradication of infection was successful.

Conclusion

The use of an endoscopic guided tibiotalocalcaneal arthrodesis is a valid option after an infected pilon fracture osteosynthesis. Patients with comorbidities such as diabetes are more likely to experience major complications. In case of infection we recommend surgery in two steps. A debridement is needed to eradicate infection. After recovery of soft tissues, placement of an intramedullary nail helps to obtain a stable fixation. The endoscopic guided approach minimizes new soft tissue damage and favours wound healing.

References

1. Abdelgaid SM, Ahmed MA, Abdel-Mageed EG (2013) Minimally Invasive Treatment Protocol for Closed Pilon Fractures. *Clinical Res Foot Ankle* 1: 108.
2. Tang X, Tang PF, Wang MY, Lü DC, Liu MZ, et al. (2012) Pilon fractures: a new classification and therapeutic strategies. *Chin Med J (Engl)* 125: 2487-2492.
3. Kline AJ, Gruen GS, Pape HC, Tarkin IS, Irrgang JJ, et al. (2009) Early complications following the operative treatment of pilon fractures with and without diabetes. *Foot Ankle Int* 30: 1042-1047.
4. Rammelt S, Pyrc J, Agren PH, Hartsock LA, Cronier P, et al. (2013) Tibiotalocalcaneal fusion using the hindfoot arthrodesis nail: a multicenter study. *Foot Ankle Int* 34: 1245-1255.
5. Jehan S, Shakeel M, Bing AJ, Hill SO (2011) The success of tibiotalocalcaneal arthrodesis with intramedullary nailing--a systematic review of the literature. *Acta Orthop Belg* 77: 644-651.
6. Hammett R, Hepple S, Forster B, Winson I (2005) Tibiotalocalcaneal (hindfoot) arthrodesis by retrograde intramedullary nailing using a curved locking nail. The results of 52 procedures. *Foot Ankle Int* 26: 810-815.
7. Chou LB, Mann RA, Yaszay B, Graves SC, McPeake WT 3rd, et al. (2000) Tibiotalocalcaneal arthrodesis. *Foot Ankle Int* 21: 804-808.
8. Carranza-Bencano A, Tejero S, Del Castillo-Blanco G, Fernández-Torres JJ, Alegrate-Parra A (2013) Minimal Incision Surgery for Tibiotalocalcaneal Arthrodesis. *Foot Ankle Int*.
9. Mendicino RW, Catanzariti AR, Saltrick KR, Dombek MF, Tullis BL, et al. (2004) Tibiotalocalcaneal arthrodesis with retrograde intramedullary nailing. *J Foot Ankle Surg* 43: 82-86.
10. Bevernage BD, Deleu PA, Maldague P, Leemrijse T (2010) Technique and early experience with posterior arthroscopic tibiotalocalcaneal arthrodesis. *Orthop Traumatol Surg Res* 96: 469-475.
11. Zelle BA, Bhandari M, Espiritu M, Koval KJ, Zlowodski M (2006) Evidence-Based Orthopaedic Working Group Treatment of distal tibia fractures without articular involvement: a systematic review of 1125 fractures. *J Orthop Trauma* 20: 76-79.
12. Kitaoka HB, Alexander JJ, Adelaar RS, Nunley JA, Myerson MS, et al. (1994) Clinical rating systems for the ankle-hindfoot, midfoot, hallux, and lesser toes. *Foot Ankle Int* 15: 349-353.
13. Hutson JJ Jr (2008) Salvage of pilon fracture nonunion and infection with circular tensioned wire fixation. *Foot Ankle Clin* 13: 29-68.
14. Green S, Roesler S (1987) Salvage of the Infected Pilon Fracture. *Tech Orth* 2: 37-41.
15. Zalavras CG, Patzakis MJ, Thordarson DB, Shah S, Sherman R, et al. (2004) Infected fractures of the distal tibial metaphysis and plafond: achievement of limb salvage with free muscle flaps, bone grafting, and ankle fusion. *Clin Orthop Relat Res* 57-62.
16. Vilà y Rico J, Rodriguez-Martin J, Parra-Sanchez G, Marti Lopez-Amor C (2013) Arthroscopic tibiotalocalcaneal arthrodesis with locked retrograde compression nail. *J Foot Ankle Surg* 52: 523-528.
17. Richter D, Hahn MP, Laun RA, Ekkernkamp A, Muhr G, et al. (1999) Arthrodesis of the infected ankle and subtalar joint: technique, indications, and results of 45 consecutive cases. *J Trauma* 47: 1072-1078.
18. Klouche S, El-Masri F, Graff W, Mamoudy P (2011) Arthrodesis with internal fixation of the infected ankle. *J Foot Ankle Surg* 50: 25-30.
19. Michels F, Stockmans F, Guillo S, Van Der Bauwhede J, Oosterlinck D (2011) Arthroscopic subtalar arthrodesis after a calcaneus fracture covered with a forearm flap. *Minim Invasive Surg* 2011: 930902.
20. Mückley T, Ullm S, Petrovitch A, Klos K, Beimel C, et al. (2007) Comparison of two intramedullary nails for tibiotalocalcaneal fusion: anatomic and radiographic considerations. *Foot Ankle Int* 28: 605-613.