

Epidermal Cyst of Upper Eyelid: A Case Report with Literature Review

Madhusmita Behera^{1*}, and Moumita Panja^{1,2}

¹Consultant Ophthalmologist, Rotary Narayana Nethralaya, CN 5, Sector-5, Salt lake, Kolkata – 700091, India

²Consultant Pathologist, Medica Superspeciality Hospital, 127, Mukundpur, Kolkata-700099, India

*Corresponding author: Madhusmita Behera, BG-95, First Floor, Salt Lake, Kolkata 700091, India, E-mail: madhusmita.behera@rediffmail.com

Received date: June 26, 2016; Accepted date: September 15, 2016; Published date: September 28, 2016

Copyright: © 2016 Behera M, et al. This is an open-access article distributed under the terms of the Creative Commons Attribution License, which permits unrestricted use, distribution, and reproduction in any medium, provided the original author and source are credited.

Abstract

Epidermal cysts are benign slow growing tumors resulting from proliferation of epidermal cells. Usually cysts are asymptomatic; however, they may become inflamed or secondarily infected. Epidermal cysts are solitary subepithelial cysts, are slowly progressive and firm in consistency. They are most commonly seen on the face, scalp, neck and trunk. Epidermoid cysts are frequently seen on the upper eyelid, mainly on the conjunctiva or on the skin. This may be misdiagnosed as chalazion or sebaceous cyst. Surgical excision of the cyst in toto is the treatment of choice or else there will be recurrence, granulomatous reaction or foreign body reaction.

Keywords: Epidermal cyst; Eyelid

Introduction

Epidermal cysts are benign slow growing tumors resulting from proliferation of epidermal cells [1-3]. Cyst of eyelid typically present during adolescence and late adulthood, as a solitary, elevated, round, freely mobile subcutaneous mass with smooth overlying skin [3]. Epidermal cyst is common in cases of men. Usually cysts are asymptomatic; however, they may become inflamed or secondarily infected. Here we are reporting a case of epidermal cyst of upper eyelid.

Case

A 65-years-old male patient visited our OPD with right upper eyelid mass. The patient gave history of this swelling for last 8 months, for which he was being treated elsewhere thinking it to be chalazion, for which incision and curettage has been done elsewhere twice within a span of last two months. After incision and curettage, the swelling used to subside but the swelling used to reappear within 15-20 days and with time, size was increasing. There was no associated pain or redness. There was no history of any ocular trauma. On examination, the right upper eyelid showed a large round swelling of around 1.5 cm in diameter. On palpation, the swelling was well defined, cystic but firm in consistency, and was free from skin and bony margins. There was no sign of inflammation and the skin overlying was normal. On retraction of the upper eyelid, 3 mm of the lower cornea was visible, and cornea was normal. Examination of the left eye was normal. We planned for the surgery, keeping in mind about the cyst to be an epidermal cyst. Accordingly, we gave incision and tried to remove the cyst into just below the lid crease, a horizontal skin incision was made. Subcutaneous tissue was separated from the centre towards the periphery. Superiorly and inferiorly, the cyst was dissected from the subcutaneous tissue. The cyst was properly excised inferiorly to expose it, with its margin intact. After thorough dissection, the cyst was found to have attachment with the tarsal plate posteriorly. So the cyst was removed into by taking little bit of tarsal plate along with it. Tarsocconjunctival suturing was done and skin was sutured with

interrupted sutures. Post operatively, patient was given oral antibiotic and topical antibiotic eye drop and local antibiotic ointment. There was no recurrence in the follow-up period of 5 months. Histopathology reports showed, on gross appearance, a round to oval 1.5 × 1.5 × 1.5 cm cystic, and grayish-brown mass (Figure 1).

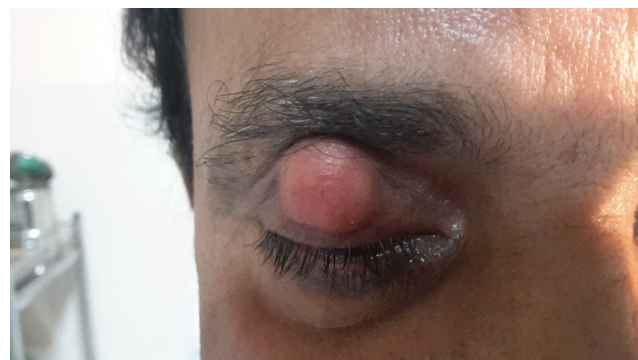

Figure 1: Epidermal cyst of right eye upper lid.

Microscopy revealed a cyst lined by stratified squamous epithelium devoid of keratin hyaline granules. The cyst lumen contained string-like keratin. The cyst wall was composed of bland collagenous tissue devoid of inflammation. Part of the tarsal plate and the underlying conjunctiva was attached to the cyst wall. The histopathology features were consistent with epidermoid cyst of the tarsal plate (Figure 2).

Discussion

Various benign and malignant lesions can be seen in the eyelids. Where benign lesions are 3 times more common than malignant neoplasms [4]. Epidermal cysts are solitary subepithelial cysts, are slowly progressive and firm in consistency, and they are most commonly seen on the face, scalp, neck and trunk. Epidermoid cysts are frequently seen on the upper eyelid, mainly on the conjunctiva or on the skin. Epidermoid cysts are the most common type of benign

periocular cutaneous lesions, accounting for 18 % of the excised benign lesions [5,6].

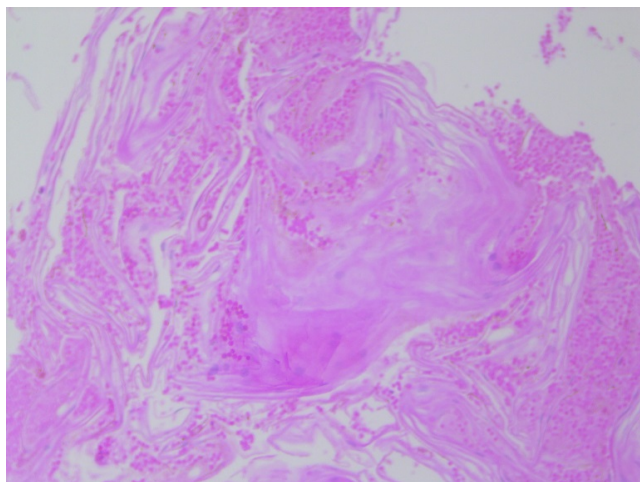


Figure 2: High power view showing few mature squamous cells and lamellated keratin

Various mechanisms have been proposed for epidermoid cyst formation [1-3]. It can be due to occlusion of the pilosebaceous follicles or surface epidermis, or can be due to implantation of epidermal elements that may be because of trauma or surgery. However, in recent studies, human papilloma virus has been associated but it is more commonly associated with epidermoid cysts of plantar surface [7]. Histology shows cyst lined by squamous epithelium and cheesy material (keratin) produced by inner layer of squamous epithelium. Complications that are associated with epidermoid cysts include infection, malignant transformation, and rupture that cause granuloma formation or even sometime abscess formation. Differential diagnosis includes sebaceous cyst, lipoma and dermoid cysts. Sebaceous cyst is a common benign cyst that appears as smooth, elevated, yellow, usually painless swellings beneath the skin in areas with multiple hair follicles. Sebaceous cysts may not change much or may grow gradually with time. There is blockage of pilosebaceous duct on the skin in cases of sebaceous cysts. Whereas cysts arose from infundibulum of hair follicles, are either epidermoid or dermoid cysts.

Epidermoid cysts contain stratified squamous epithelium that forms the cyst wall, whereas dermoid cyst contains epidermal appendages like sebaceous gland, sweat gland and hair follicles.

Small asymptomatic epidermoid cyst can be managed with intralesional triamcinolone injection. Incision and drainage may be performed if a cyst wall is inflamed. Injection of triamcinolone into tissue surrounding the inflamed cyst results faster Improvement of symptoms. However, it does not eradicate the cyst. Large symptomatic cyst should be excised in toto like in our case. Like the index case, Lucarelli et al. reported cases of intrastromal epidermal inclusion cysts, which were initially diagnosed as chalazions and for which incision and curettage was done [8].

Conclusion

In the present case, though there was history of surgery done twice before the patient presented to us, because the case was misdiagnosed to have chalazion previously. Cyst formation in the present case likely originated at the time of eyelid development. As with epidermal cysts in other location, surgical excision is the treatment of choice.

References

1. Braun-Falco O (2000) *Dermatology*, Berlin, Springer, Germany.
2. Shields JA, Bakewell B, Augsburger JJ, Donoso LA, Bernardino V (1986) Space-occupying orbital masses in children. A review of 250 consecutive biopsies. *Ophthalmology* 93: 379-384.
3. Kronish JW, Sneed SR, Tse DT (1988) Epidermal cysts of the eyelid. *Arch Ophthalmol* 106: 270.
4. Yanoff M, Kuker JS (2009) *Orbit and Oculoplastics; enigm eyelid lesions*. Ann G Neff and Keith D Carter *Epithelial tumours* pp: 1422-1424.
5. *Principles and practice of Ophthalmology*, Albert and Jackobiec's, Elsevier 3rd edition 3245.
6. The Eye MD Association, American Academy of Ophthalmology (2007-08) *Orbit, Eyelid, and Lacrimal System*.
7. Egawa K, Egawa N, Honda Y (2005) Human papillomavirus-associated plantar epidermoid cyst related to epidermoid metaplasia of the eccrine duct epithelium: a combined histological, immunohistochemical, DNA-DNA in situ hybridization and three-dimensional reconstruction analysis. *Br J Dermatol* 152: 961-967.
8. Lucarelli MJ, Ahn HB, Kulkarni AD, Kahana A (2008) Intratarsal epidermal inclusion cyst. *Ophthal Plast Reconstr Surg* 24: 357-359.