

## Femtosecond Laser-assisted Cataract Surgery in Marfan Syndrome

Pavel Rozsival<sup>1,4</sup>, Naďa Jirásková<sup>1,4</sup>, Alexandr Stepanov<sup>1,4</sup> and Ján Lešťák<sup>2,3,4\*</sup>

<sup>1</sup>Department of Ophthalmology, University Hospital and Charles Medical Faculty, Hradec Králové, Czech Republic

<sup>2</sup>JL Clinic, V Hurkách 1296/10, Prague, Czech Republic

<sup>3</sup>Faculty of Biomedical Engineering, Czech Technical University in Prague, Czech Republic

<sup>4</sup>Faculty of Medicine in Hradec Kralove, Charles University, Czech Republic

\*Corresponding author: Prof. MD. Jan Lešťák CSc, FEBO, JL Clinic, V Hurkách 1296/10, Prague, Czech Republic, Tel: +420 296 186 113; E-mail: lestak@seznam.cz

Received date: Mar 27, 2015, Accepted date: Apr 27, 2015, Published date: Apr 30, 2015

Copyright: © 2015 Rozsival P, et al. This is an open-access article distributed under the terms of the Creative Commons Attribution License, which permits unrestricted use, distribution, and reproduction in any medium, provided the original author and source are credited.

### Abstract

This case report a rare case of 67-year-old man, presented with Marfan's syndrome, cataract and crystalline lens dislocation of the left eye. The best corrected visual acuity (BCVA) of the left eye was 0.2. Cataract surgery was assisted by femtosecond laser LenSx. One month after surgery uncorrected visual acuity (UCVA) of the left eye was 0.9, BCVA with sph. +1.5 was 1.0. Intraocular lens have perfectly centered in the eye. Femtosecond laser is a significant improvement in surgery of patients with Marfan syndrome. Femtosecond laser is a significant improvement in surgery of patients with Marfan syndrome.

**Keywords:** Marfan's syndrome; Femtosecond laser-assisted cataract surgery; Lens dislocation

### Introduction

Cataract surgery remains the most widely performed intraocular procedure throughout the world. As the safety and accuracy of the procedure are paramount to both patient and surgeon techniques must remain under constant review [1,2]. The technique of cataract surgery has evolved from large incision extracapsular extraction with basic, single focal intraocular lenses (IOLs) to microincision surgeries with improved lens technology. The recent introduction of femtosecond lasers to cataract surgery represents a potentially significant advance in cataract technology [3].

Femtosecond lasers have been used successfully in ophthalmic surgery for a number of years [4-7] and have been noted to be more precise than highly sophisticated mechanical devices, with fewer likely collateral tissue effects [8]. He et al. suggest that similar to refractive surgery, femtosecond laser technology can deliver these gains to cataract surgery with improvements in reproducibility, centration and safety [3].

Lasers may currently assist or replace several aspects of cataract surgery including creation of clear corneal incisions (CCI), creation of the capsulotomy, fragmentation of the lens nucleus and correction of astigmatism through corresponding arcuate incisions.

Evidence already suggests that successful completion of a case in femtosecond assisted cataract surgery does produce a superior wound, more circular and more consistently sized capsulotomy and probably contributes to a reduction in the average phacoemulsification energy and time than in routine manual surgery. The combination of these features should translate to a safer, more accurate outcome for patients. The technology itself is continually evolving and improving. This will reduce the learning curve and the possibility of intraoperative complications for surgeons undertaking surgery with the assistance of the femtosecond lasers. The use of femtosecond lasers with cataract

surgery is an exciting development for both patients and surgeons alike.

Marfan syndrome (MFS) was first described in 1896 by Antoine-Bernard Marfan [9]. An inherited disorder of the connective tissue, MFS is caused by a mutation of the extracellular matrix protein fibrillin 1 (15q21.1) [10-13].

The incidence of classic MFS is approximately 2 to 3 per 10 000 individuals [14]. It is a multisystem disorder with manifestations typically involving the skeletal, ocular, and cardiovascular systems [15]. Diagnosis and management benefit from a multidisciplinary assessment, generally including a geneticist, ophthalmologist, and cardiologist [14,16]. Ocular involvement in MFS is subdivided into major and minor criteria. Ectopia lentis of any degree is a major criterion. At least 2 of the minor criteria must be present for consideration as ocular involvement: an abnormally flat cornea, increased axial length, and hypoplasia of the ciliary muscle or iris, causing decreased mydriasis. Mean keratometry values <42 diopters (D) are highly correlated with a diagnosis of MFS [17]. Other secondary manifestations are early severe myopia, retinal detachment, early cataracts, glaucoma, and amblyopia [14,16].

Ectopia lentis occurs in 50% to 80% of patients with Marfan syndrome, of which it can be the presenting sign [18,19]. Lens subluxation produces vision alterations primarily due to refractive errors and induced anisometropia and, being progressive, frequently induces refractive changes and high astigmatism.

Management initially involves optimization of optical refraction, but may require lens removal when visual acuity becomes uncorrectable or the refractive status is unstable [20-22], or if anterior dislocation causes secondary ocular hypertension and risk of glaucomatous damage and/or risk of endothelial compromise [10,23].

We describe a case of a patient with lens subluxation due to Marfan syndrome who had femtosecond laser-assisted cataract surgery of the left eye with excellent outcomes.

## Case report

A 67-year-old man, presented with Marfan's syndrome, cataract and crystalline lens dislocation of the left eye. The best corrected visual acuity (BCVA) of the left eye was 0.2 and 0.9 of the right eye, with a refractive error in the right eye of sph. -1.0 cyl. +1.0 ax 4 dg. Axial length of the left eye was 24.67 mm. The patient was fully informed about the nature of the procedure, its complications, as well as alternative procedures available, and he provided written consent. The SRK II formula was used to calculate intraocular lens (IOL) power, with the aim of emmetropia.

Femtosecond laser-assisted cataract surgery with integrated optical coherence tomography was performed 18.02.2014. Figure 1 presents the optical coherence tomography (OCT) scan of the capsule showing grossly distorted lens shape, and in the Figure 2 we can see OCT scan of planned femto cuts in the lens nucleus.

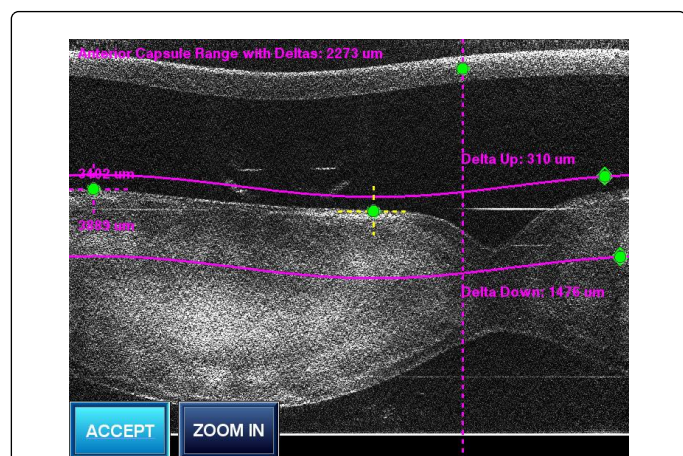


Figure 1: OCT scan of the capsule showing grossly distorted lens shape.

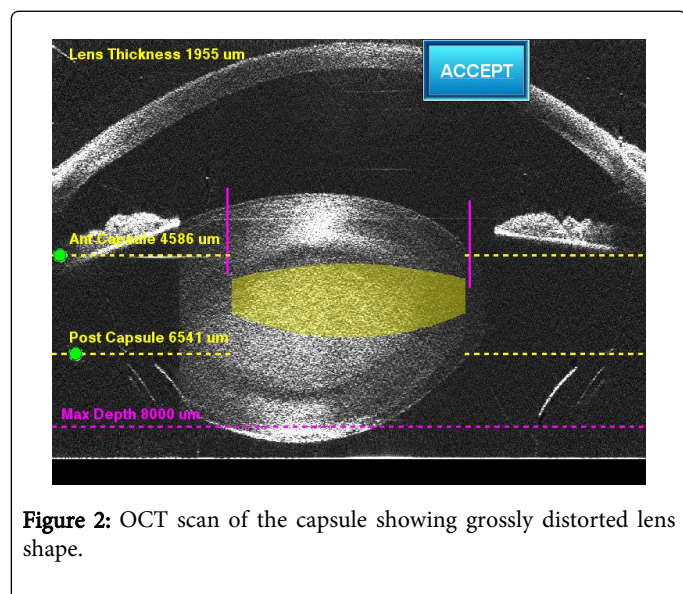


Figure 2: OCT scan of the capsule showing grossly distorted lens shape.

Femto part of the surgery was unevenful after docking and planning. Under operating microscope wounds were opened, anterior chamber filled with cohesive viscoelastic (OVD), free floating

capsulorhexis removed (Figure 3), careful hydrodissection and phaco of the lens performed. Residual lens cortex was cleaned by I/A. The capsule was filled with cohesive OVD and capsular ring implanted-immediate recentering of the bag was observed. IOL was implanted in the bag, OVD removed by I/A (Figure 4). Closure of wounds after hydration was checked, antibiotics applied and eye was patched to the next day. One months after surgery uncorrected visual acuity (UCVA) of the left eye was 0.9, BCVA with sph. +1.5 was 1.0. IOL have perfectly centered in the eye. Good UCVA have resulted in a high degree satisfaction of patient.

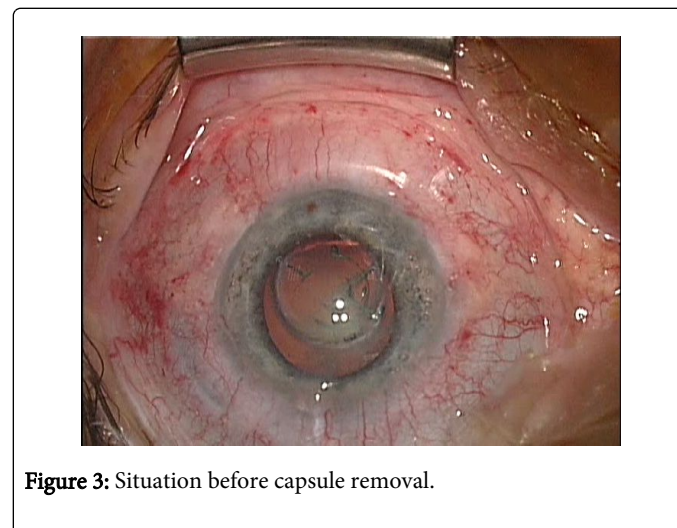


Figure 3: Situation before capsule removal.

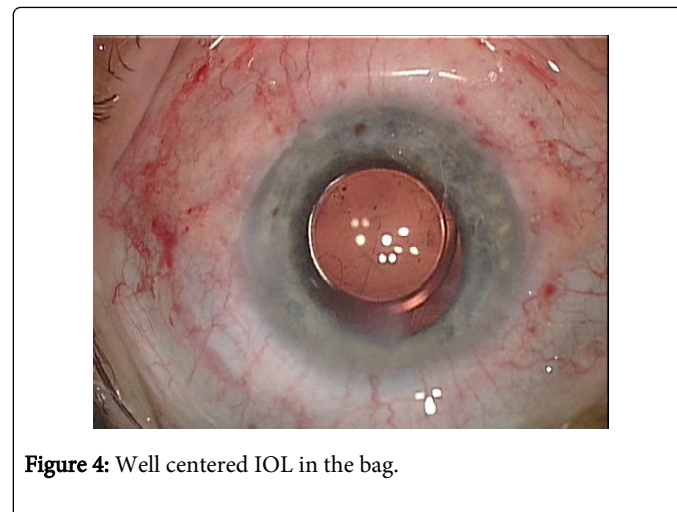


Figure 4: Well centered IOL in the bag.

## Discussion

Femtosecond laser-assisted cataract surgery in patients with Marfan syndrome is safe and provides consistent surgical results. The technique minimizes pulling forces and trauma to the zonules and iris and, by extension, to the vitreous base. This is especially important in the setting of Marfan syndrome, in which patients are at increased risk for retinal detachments (5%-11%), more common in patients with lens subluxation or prior intraocular surgery (8%-38%) [20,24,25].

As for concerns complications, publications provide a broader range thereof. One study an lensectomy reported that up to 51% exhibited immediate complications (vitreous loss, iris prolapse, corneal



edema, hyphaema among others) [26], whereas a prospective lensectomy study of 95 eyes of children reported only one non-significant vitreous hemorrhage and one late case of retinal tear treated with photocoagulation [27]. Other papers reported complications such as hyphaema in 5% [28], corneal decompensation between 10% and 14% [29-31], temporary ocular hypertension between 4% and 7% [31,32-34], intraocular lens dislocation between 2 and 19% [31,33] and cystoid macular edema, 3% [35]. As regards severe complications, 10-19% exhibited retina detachment [26,29,30].

Since Jarrett's publication of a large series of cases (n=166) on surgery for lens subluxation 1967 [36], various operative techniques and results have been suggested for subluxated lenses and aphakia correction in patients with MFS. Nevertheless, the management of ectopia lentis remains challenging and certain controversies remain unresolved [20,36].

Femtosecond laser-assisted cataract surgery is gradually gaining popularity, and is currently most prized for facilitating the creation of a precise anterior capsulotomy and assisting nuclear fragmentation and softening. The laser has also an important role for customized corneal incisions and astigmatic keratotomies. Recent publications highlight the reproducibility and precision of the anterior capsulotomy size and centration [37-41], thereby affording less lens tilt and improved biometry predictability [42-45]. Additional advantages reported include the reduction in phacoemulsification energy [40,46-48] and superior wound healing and sealing [13] achieved by the femtosecond laser. Femtosecond lasers and their application to cataract surgery constitute a major innovation in modern ophthalmic surgery. The surgical procedure performed in this way, facilitates optimization of the surgical time, minimizing the surgeon's work (the least controllable variable of all those involved in cataract surgery) to the elimination of the cortical remains and the implantation of the intraocular lens [3]. Femtosecond laser-assisted cataract surgery may offer advantages in cases of subluxated cataracts. The femtosecond laser does not depend on counter resistance from zonular support and is able to cut a circular anterior capsule opening despite subluxation of the lens as long as the lens is not tilted excessively after docking with the patient interface. In the presence of zonulopathy, with an absence of counter traction to mobilize the lens nucleus, hydrodissection or viscodissection by standard phacoemulsification may endanger the remaining zonular fibers and even the bag itself. And femtosecond laser affords a tremendous degree of safety and control. Gerasimos et al. have published, that it is possible perform phacoemulsification in the case of 160 degrees zonular dialysis [49], so, femtosecond laser-assisted cataract surgery allows to make operation in the case of more large zonular dialysis.

## Conclusions

The use of a femtosecond laser allowed to perform circular, well centered capsulotomy, facilitated slow motion phaco, capsular tension device (CTR) and foldable lens implantation. Femtosecond laser is a significant improvement in surgery of patients with Marfan syndrome.

## Acknowledgement

All co-authors have read the final manuscript within their respective areas of expertise.

## Conflict of interest:

None of the authors has conflict of interest with the submission.

## Financial support

No financial support was received for this submission.

## References

1. Semmens JB, Li J, Morlet N, Ng J, teamEPSWA (2003) Trends in cataract surgery and postoperative endophthalmitis in Western Australia (1980–1998): the Endophthalmitis Population Study of Western Australia. *Clin Exp Ophthalmol* 31: 213-219.
2. Erie JC, Baratz KH, Hodge DO, Schleck CD, Burke JP (2007) Incidence of cataract surgery from 1980 through 2004: 25-year population-based study. *J Cataract Refract Surg* 33: 1273-1277.
3. He L, Sheehy K, Culbertson W (2011) Femtosecond laser-assisted cataract surgery. *Curr Opin Ophthalmol* 22: 43-52.
4. Ratkay-Traub I, Juhasz T, Horvath C, Suarez C, Kiss K et al. (2001) Ultra-short pulse (femtosecond) laser surgery: initial use in LASIK flap creation. *Ophthalmol Clin North Am* 14: 347-355.
5. Gil-Cazorla R, Teus MA, de Benito-Llopis L, Mikropoulos DG (2011) Femtosecond laser vs mechanical microkeratome for hyperopic laser in situ keratomileusis. *Am J Ophthalmol* 152: 16-21.
6. Sutton G, Hodge C (2008) Accuracy and precision of LASIK flap thickness using the IntraLase femtosecond laser in 1000 consecutive cases. *J Refract Surg* 24: 802-806.
7. Kim P, Sutton GL, Rootman DS (2011) Applications of the femtosecond laser in corneal refractive surgery. *Curr Opin Ophthalmol* 22: 238-244.
8. Sugar A (2002) Ultrafast (femtosecond) laser refractive surgery. *Curr Opin Ophthalmol* 13: 246-249.
9. Marfan AB (1896) Un cas de déformation congénitale des quatre membres, plus prononcée aux extrémités, caractérisée par l'allongement des os avec un certain degré d'amincissement. *Bull Mem Soc Méd Hop Paris* 13: 220-226.
10. Hollister DW, Godfrey M, Sakai LY, Pyeritz RE (1990) Immunohistologic abnormalities of the microfibrillar-fiber system in the Marfan syndrome. *N Engl J Med* 323: 152-159.
11. Dietz HC, Cutting GR, Pyeritz RE, Maslen CL, Sakai LY, et al. (1991) Marfan syndrome caused by a recurrent de novo missense mutation in the fibrillin gene. *Nature* 352: 337-339.
12. Kainulainen K, Pulkkinen L, Savolainen A, Kaitila I, Peltonen L (1990) Location on chromosome 15 of the gene defect causing Marfan syndrome. *N Engl J Med* 323: 935-939.
13. Sakai LY, Keene DR, Engvall E (1986) Fibrillin, a new 350-kD glycoprotein, is a component of extracellular microfibrils. *J Cell Biol* 103: 2499-2509.
14. Judge DPI, Dietz HC (2005) Marfan's syndrome. *Lancet* 366: 1965-1976.
15. Pyeritz RE, McKusick VA (1979) The Marfan syndrome: diagnosis and management. *N Engl J Med* 300: 772-777.
16. De Paepe A, Devereux RB, Dietz HC, Hennekam RC, Pyeritz RE (1996) Revised diagnostic criteria for the Marfan syndrome. *Am J Med Genet* 62: 417-426.
17. Heur M, Costin B, Crowe S, Grimm RA, Moran R, et al. (2008) The value of keratometry and central corneal thickness measurements in the clinical diagnosis of Marfan syndrome. *Am J Ophthalmol* 145: 997-1001.
18. Hindle NW, Crawford JS (1969) Dislocation of the lens in Marfan's syndrome. Its effect and treatment. *Can J Ophthalmol* 4: 128-135.
19. Zadeh N, Bernstein JA, Niemi AK, Dugan S, Kwan A, et al. (2011) Ectopia lentis as the presenting and primary feature in Marfan syndrome. *Am J Med Genet A* 155A: 2661-2668.
20. Maumenee IH (1981) The eye in the Marfan syndrome. *Trans Am Ophthalmol Soc* 79: 684-733.

21. Nelson LB, Maumenee IH (1982) Ectopia lentis. *Surv Ophthalmol* 27: 143-160.
22. Kazemi S, Wirostko WJ, Sinha S, Mieler WF, Koenig SB, et al. (2000) Combined pars plana lensectomy-vitreotomy with open-loop flexible anterior chamber intraocular lens (AC IOL) implantation for subluxated lenses. *Trans Am Ophthalmol Soc* 98: 247-251.
23. Maumenee IH (1982) The eye in the Marfan syndrome. *Birth Defects Orig Artic Ser* 18: 515-524.
24. Loewenstein A, Barequet IS, De Juan E Jr, Maumenee IH (2000) Retinal detachment in Marfan syndrome. *Retina* 20: 358-363.
25. Greco GM, Ambrosino L (1993) Treatment of retinal detachment in Marfan syndrome. *Ann Ophthalmol* 25: 72-76.
26. Cross HE, Jensen AD (1973) Ocular manifestations in the Marfan syndrome and homocystinuria. *Am J Ophthalmol* 75: 405-420.
27. Anteby I, Isaac M, BenEzra D (2003) Hereditary subluxated lenses: visual performances and long-term follow-up after surgery. *Ophthalmology* 110: 1344-1348.
28. Yu YS, Kang YH, Lim KH (1997) Improvements in visual acuity following limbal lensectomy for subluxated lenses in children. *Ophthalmic Surg Lasers* 28: 1006-1010.
29. Aspiotis M, Asproudis I, Stefanidou M, Gorezis S, Psilas K (2006) Artisan aphakic intraocular lens implantation in cases of subluxated crystalline lenses due to Marfan syndrome. *J Refract Surg* 22: 99-101.
30. Sinha R, Sharma N, Vajpayee RB (2005) Intralenticular bimanual irrigation: aspiration for subluxated lens in Marfan's syndrome. *J Cataract Refract Surg* 31: 1283-1286.
31. Hirashima DE, Soriano ES, Meirelles RL, Alberti GN, Nosé W (2010) Outcomes of iris-claw anterior chamber versus iris-fixated foldable intraocular lens in subluxated lens secondary to Marfan syndrome. *Ophthalmology* 117: 1479-1485.
32. Halpert M, BenEzra D (1996) Surgery of the hereditary subluxated lens in children. *Ophthalmology* 103: 681-686.
33. Waiswol M, Kasahara N (2009) Lens subluxation grading system: predictive value for ectopia lentis surgical outcomes. *Einstein* 7: 81-87.
34. Chan CC, Crandall AS, Ahmed II (2006) Ab externo scleral suture loop fixation for posterior chamber intraocular lens decentration: clinical results. *J Cataract Refract Surg* 32: 121-128.
35. Plager DA, Parks MM, Helveston EM, Ellis FD (1992) Surgical treatment of subluxated lenses in children. *Ophthalmology* 99: 1018-1021.
36. Jarrett WH II (1967) Dislocation of the lens. A study of 166 hospitalized cases. *Arch Ophthalmol* 78: 289-296.
37. Abell RG, Kerr NM, Vote BJ (2013) Femtosecond laser-assisted cataract surgery compared with conventional cataract surgery. *Clin Experiment Ophthalmol* 41: 455-462.
38. Bali SJ, Hodge C, Lawless M, Roberts TV, Sutton G (2012) Early experience with the femtosecond laser for cataract surgery. *Ophthalmology* 119: 891-899.
39. Nagy Z, Takacs A, Filkorn T, Sarayba M (2009) Initial clinical evaluation of an intraocular femtosecond laser in cataract surgery. *J Refract Surg* 25: 1053-1060.
40. Reddy KP, Kandulla J, Auffarth GU (2013) Effectiveness and safety of femtosecond laser-assisted lens fragmentation and anterior capsulotomy versus the manual technique in cataract surgery. *J Cataract Refract Surg* 39: 1297-1306.
41. Friedman NJ, Palanker DV, Schuele G, Andersen D, Marcellino G, et al. (2011) Femtosecond laser capsulotomy. *J Cataract Refract Surg* 37: 1189-1198.
42. Kránitz K, Takacs A, Miháltz K, Kovács I, Knorz MC, Nagy ZZ (2011) Femtosecond laser capsulotomy and manual continuous curvilinear capsulorhexis parameters and their effects on intraocular lens centration. *J Refract Surg* 27: 558-563.
43. Nagy ZZ, Kránitz K, Takacs AI, Miháltz K, Kovács I, et al. (2011) Comparison of intraocular lens decentration parameters after femtosecond and manual capsulotomies. *J Refract Surg* 27: 564-569.
44. Kránitz K, Miháltz K, Sándor GL, Takacs A, Knorz MC, et al. (2012) Intraocular lens tilt and decentration measured by Scheimpflug camera following manual or femtosecond laser-created continuous circular capsulotomy. *J Refract Surg* 28: 259-263.
45. Filkorn T, Kovács I, Takács A, Horváth E, Knorz MC, Nagy ZZ (2012) Comparison of IOL power calculation and refractive outcome after laser refractive cataract surgery with a femtosecond laser versus conventional phacoemulsification. *J Refract Surg* 28: 540-544.
46. Abell RG, Kerr NM, Vote BJ (2013) Toward zero effective phacoemulsification time using femtosecond laser pretreatment. *Ophthalmology* 120: 942-948.
47. Conrad-Hengerer I, Hengerer FH, Schultz T, Dick HB (2012) Effect of femtosecond laser fragmentation on effective phacoemulsification time in cataract surgery. *J Refract Surg* 28: 879-883.
48. Conrad-Hengerer I, Hengerer FH, Schultz T, Dick HB (2012) Effect of femtosecond laser fragmentation of the nucleus with different softening grid sizes on effective phaco time in cataract surgery. *J Cataract Refract Surg* 38: 1888-1894.
49. Georgopoulos GT, Papaconstantinou D, Georgalas I, Koutsandrea CN, Margetis I (2007) Management of large traumatic zonular dialysis with phacoemulsification and IOL implantation using the capsular tension ring. *Acta Ophthalmol Scand* 85: 653-657.