

Gastric Metastasis of Renal Cell Carcinoma 5 Years after Left Radical Nephrectomy: A Case Report

Nalan Gulsen Unal¹, Fatih Tekin^{1*}, Murat Sezak² and Oktay Tekesin¹

¹Department of Gastroenterology, Ege University Medical School, Izmir, Turkey

²Department of Pathology, Ege University Medical School, Izmir, Turkey

*Corresponding author: Dr. Fatih Tekin, Gastroenteroloji Bilim Dalı, Ege Üniversitesi Tıp Fakültesi, Bornova, Izmir, 35100, Turkey, Tel: +90-232-3904357; Fax: +90-232-3427764; E-mail: drtekinfatih@gmail.com

Received date: May 30, 2016; Accepted date: July 1, 2016; Publication date: July 10, 2016

Copyright: © 2016 Unal NG, et al. This is an open-access article distributed under the terms of the Creative Commons Attribution License; which permits unrestricted use; distribution; and reproduction in any medium; provided the original author and source are credited.

Abstract

Gastric metastasis of renal cell carcinoma (RCC) is unusual and few cases have been reported in the literature. We here report a 63 years-old male with multiple gastric and concomitant other organ metastasis of RCC 5 years after left radical nephrectomy. He presented with iron deficiency anemia without any gastrointestinal symptom. Radiological imagings showed multiple polypoid masses in the stomach and metastatic tumors in pancreas, lung and bilateral adrenal glands. Esophagogastroduodenoscopy showed multiple gastric “volcano-like” polypoid masses in the stomach. Histopathological examination and immunohistochemical staining showed the features of metastasis of clear cell carcinoma.

Keywords: Renal cell cancer; Clear cell cancer; Gastric metastasis

Introduction

RCC is a relatively rare adult malignancy but the most common renal tumor, accounting for 2-3% of all malignancies. Clear cell carcinoma is the most common subtype of RCC [1]. It has been reported metastatic involvement rate of the stomach is 0.2%-0.7% in the autopsy series [2-4]. Lung and breast cancer and malignant melanoma are the most common sites of primary tumors. More than 50% of patients are asymptomatic at the presentation, and almost one-third of all patients have distant metastasis at the time of diagnosis. Metastatic lesions from RCC commonly occur in the lung, bone, liver and soft tissue. Gastric metastasis arising from RCC is unusual [5]. The published reports of cases have shown that gastric metastasis of RCC are mostly seen as single polypoid masses, and the average time from nephrectomy to presentation of gastric metastasis is almost 6.9 years. Since the prognosis for the majority of these patients is very poor, early detection of metastasis may play an important role.

Case Report

We present a 63 years-old male who had a history of left radical nephrectomy due to RCC 5 years ago. Final diagnosis was clear cell carcinoma. Physical examination, laboratory tests and radiological findings showed no abnormality during a 5-year follow-up period. He did not have any complaints or symptoms in this time of period. After 5 years of radical nephrectomy iron deficiency anemia was detected with a hemoglobin level of 10.5 gr/dl, hematocrit 31.7%, MCV: 78 fl, and ferritin: 40 ng/ml. A computed tomography (CT) of the torax and an abdominal magnetic resonance imaging (MRI) were performed. Torax CT revealed metastatic lesions of lungs and abdominal MRI revealed a pancreatic mass with a diameter of 4 cm, bilateral adrenal gland masses with diameters of 3 and 3.5 cm, and multiple polypoid gastric masses suggesting the metastasis of RCC (Figure 1). Esophagogastroduodenoscopy (EGD) revealed multiple “volcano-like”

polypoid masses covered by normal mucosa with central ulcerations with diameters between 3-15 mm at the whole part of the stomach. Some of the lesions had hematin on their surfaces (Figures 2 and 3). Since endoscopic resection of all lesions was not possible, multiple biopsies were taken from the lesions. Histopathological examination showed clear cells and immunohistochemistry revealed the feature of metastasis of RCC (Figures 4 and 5). Chemotherapy was started with an interferon-alpha but discontinued due to side effects. Pazopanib (tyrosine kinase inhibitor) was started as a targeted drug but bone metastasis occurred under pazopanib therapy. Thus, pazopanib switched to everolimus (one of the m-TOR inhibitors). He is still alive with a stable disease after 1 year.

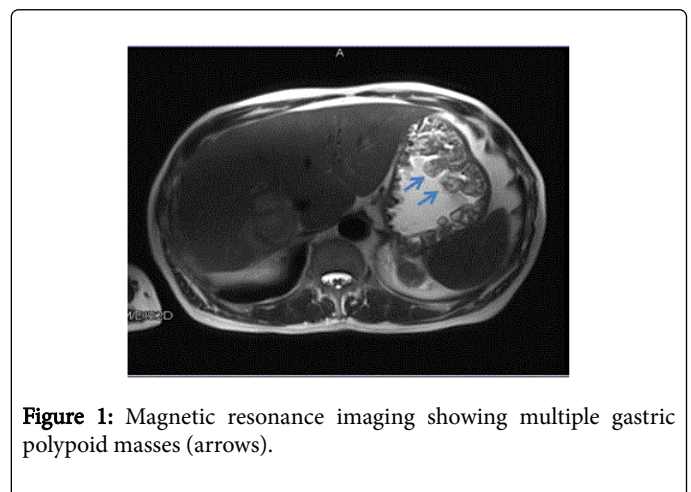


Figure 1: Magnetic resonance imaging showing multiple gastric polypoid masses (arrows).

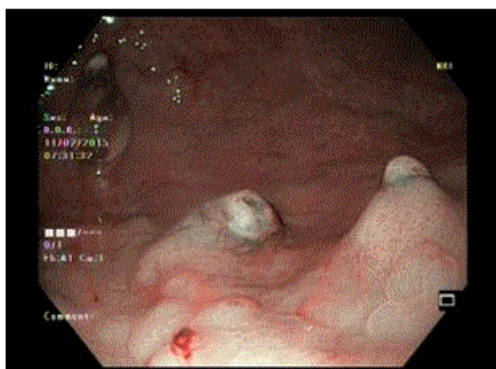


Figure 2: Esophagogastroduodenoscopy revealed multiple “volcano-like” polypoid masses covered by normal mucosa with central ulcerations.

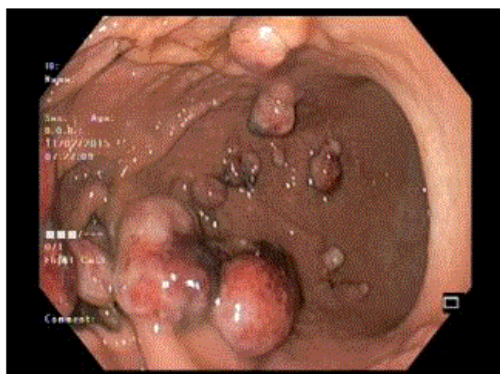


Figure 3: See the hematin on the surface of some of the lesions.

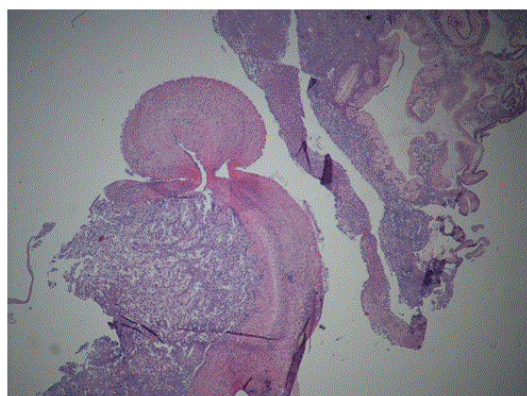


Figure 4: Changes around ulcerated gastric mucosa with foveolar hyperplasia was seen at the right side of the image. At the left side, tumor cells with clear cytoplasm covered with pus were seen. (Hematoxyline eosine (H&E) X4).

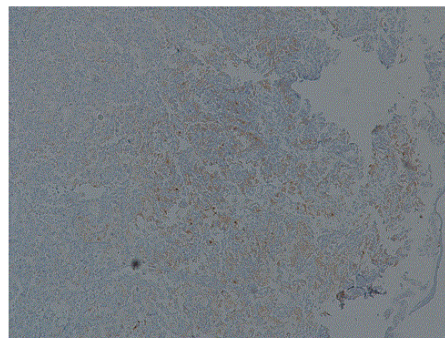


Figure 5: CD10 Immunohistochemistry: Cytoplasm positive tumor cells.

Discussion

Metastatic tumors to the stomach are uncommon. Gastric metastasis of RCC is extremely rare, with a detection in 0.2% of all RCC cases [6]. RCC can often be cured if it is diagnosed and treated when still localized in the kidney and the surrounding tissue [7]. Approximately, 73% of all RCC patients survive for 5 years [8].

The most common presentation of RCC patients with gastric metastasis is upper gastrointestinal bleeding (65.9%). Iron deficiency anemia was reported in 14.6% of these cases [9]. Our case presented with iron deficiency anemia without any gastrointestinal symptoms. The mean time of the occurrence of gastric metastasis of RCC was found to be 6.9 years [6], whereas it was found to be 2 years for other metastatic tumors of the stomach [10]. It reveals that gastric metastasis of RCC shows a slow process. In this present case, the time of appearance of gastric metastasis after radical nephrectomy was 5 years. It can give an impression that occurrence of gastric metastasis is related to advance disease. However, a review by Sakurai et al. with 44 RCC patients with gastric metastasis revealed that 13 of them had gastric metastasis without any other organ metastasis [11]; that means gastric metastasis could be the first. It was shown that outcomes of patients with solitary gastric metastasis of RCC tend to have better survival compared with multiple gastric metastasis of RCC [12]. The underlying mechanism remains unclear. When distant metastasis of RCC appears, disease-free survival is poor. It was reported that gastric metastasis of RCC with concomitant metastasis was seen in 60.9% of patients and median survival time was found 6 months (1-84 months) after treatment of gastric metastasis [11]. Therefore early detection of metastasis of RCC is important to influence patients' survival.

The optimal therapy of gastric metastasis of RCC remains unclear. Surgical treatment, endoscopic treatment, chemotherapy or palliative embolization may occur as treatment alternatives. It is reported that the endoscopic resection of solitary metastasis of RCC can be as good as the surgery if the lesion is <2-3 cm and limited to the mucosa [9]. In our case, since the occurrence of multiple gastric and wide spreaded distant metastasis (pancreas, lung, bilateral adrenal glands), only systemic chemotherapeutic drugs were administered.

Conclusion

Gastric metastasis of RCC is very rare and may occur many years after the diagnosis. Consisting with the literature, the interval time

between radical nephrectomy and appearance of gastric and concomitant metastasis in the present case was 5 years. Early detection of gastric metastasis may have an important role to improve patients survival. However, there exist no guideline or recommendation as a post-operative routine endoscopic follow-up procedure. 'Volcano-like' polypoid lesion(s) are highly suggestive endoscopic feature for gastric metastasis of RCC. The use of targeted drugs can offer a new perspective for the patients with widespread metastasis of RCC.

References

1. Cohen HT, McGovern FJ (2005) Renal-cell carcinoma. *N Engl J Med* 353: 2477-2490.
2. Davis GH, Zollinger RW (1960) Metastatic melanoma of the stomach. *Am J Surg* 99: 94-96.
3. Higgins PM (1962) Pyloric obstructions due to a metastatic deposit from carcinoma of the bronchus. *Can J Surg* 5: 438-441.
4. Green LK (1990) Hematogenous metastasis to the stomach. A review of 67 cases. *Cancer* 65: 1596-1600.
5. Campoli PM, Ejima FH, Cardoso DM, Silva OQ, Santana Filho JB (2006) Metastatic cancer to the stomach. *Gastric Cancer* 9: 19-25.
6. Pollheimer MJ, Hinterleitner TA, Pollheimer VS, Schlemmer A, Langner C (2008) Renal cell carcinoma metastatic to the stomach: single-centre experience and literature review. *BJU Int* 102: 315-319.
7. Sene AP, Hunt L, McMahon RE, Carroll RN (1992) Renal carcinoma in patients undergoing nephrectomy: analysis of survival and prognostic factors. *Br J Urol* 70: 125-134.
8. (2014) National Cancer Institute: SEER Stat Fact Sheets: Kidney and Renal Pelvis Cancer. Bethesda, MD: National Cancer Institute.
9. Herculano R, Isabel A, Iolanda C, Alexander H, Pedro C, et al (2014) Treatment of gastric metastasis from renal cell carcinoma with endoscopic therapy. *Clin J Gastroenterol* 7: 148-154.
10. De Palma GD, Masone S, Rega M, Simeoli I, Donisi M, et al (2006) Metastatic tumors to the stomach: clinical and endoscopic features. *World J Gastroenterol* 12: 7326-7328.
11. Sakurai K, Muguruma K, Yamazoe S (2014) Gastric metastasis from renal cell carcinoma with gastrointestinal bleeding: a case report and review of the literature. *Int Surg* 99: 86-90.
12. Namikawa T, Munekage M, Kitagawa H, Okabayashi T, Kobayashi M, et al (2012) Metastatic gastric tumors arising from renal cell carcinoma: clinical characteristics and outcomes of this uncommon disease. *Oncol Lett* 4: 631-663.