

## *Leclercia adecarboxylata*: The First Reported Infection of Cerebrospinal Fluid and a Systematic Review of the Literature

Jill P Stone<sup>1</sup>, Hannah St Denis-Katz<sup>2</sup>, Claire Temple-Oberle<sup>3\*</sup>, Phillipe Mercier<sup>4</sup>, Jonah B Mizzau<sup>5</sup> and Alim P Mitha<sup>4</sup>

<sup>1</sup>Division of Plastic Surgery, Department of Surgery, University of Calgary, Calgary, Canada

<sup>2</sup>University of Saskatchewan, Canada

<sup>3</sup>Division of Surgical Oncology, Department of Surgery, University of Calgary, Calgary, Canada

<sup>4</sup>Department of Clinical Neurosciences, University of Calgary, Calgary, Canada

<sup>5</sup>Department of Internal Medicine, University of Calgary, Calgary, Canada

### Abstract

**Background:** *Leclercia adecarboxylata* is an emerging pathogen in the clinical setting. Initially considered an opportunistic pathogen commonly associated with polymicrobial infections in immunocompromised individuals, recent evidence recognizes this pathogen in healthy individuals and with a growing antibiotic resistance profile. We report the first case of *Leclercia adecarboxylata* in cerebrospinal fluid of a young trauma patient and present a systematic review of the literature. Patient demographics and clinical history, outcomes and treatments are outlined.

**Methods:** A systematic review identified relevant studies published through PubMed, Medline and ProQuest until July 2015. Search terms included "*Leclercia adecarboxylata*" and "*Escherichia adecarboxylata*". Non-human cases and reports devoid of clinical infections were excluded.

**Results:** A total of 40 articles (51 patients including the current case) were identified and included in our analysis. Patient age ranged from 24 weeks to 81 years old and included 18 female, 24 male, and 9 unknown. Immunocompromised (n=32) and healthy patients (n=15) revealed clinical isolates from blood and wound cultures most commonly (n=21 and 11). Sixteen isolates demonstrated antibiotic resistance. Thirty four cases were monomicrobial and fifteen were polymicrobial. Patient treatment and clinical outcome are reported.

**Conclusions:** We present the most up to date review of *Leclercia adecarboxylata* infections. As the number of *L. adecarboxylata* cases continue to expand so does our insight into its pathogenicity and role in human clinical infections.

**Keywords:** *Leclercia adecarboxylata*; *Escherichia adecarboxylata*; Cerebrospinal fluid; Infection

### Background

*Leclercia adecarboxylata* was once thought to be a relatively uncommon pathogen [1]. Originally described by Leclerc in 1962 as *Escherichia adecarboxylata*, the development of more accurate identification methods reclassified this facultative aerobic, Gram negative bacillus as a member of the *Enterobacteriaceae* family [2]. It is a pathogen found widely in nature, having been isolated from food, water, and other environmental sources, as well as a commensal organism in the gut flora of some animals and humans [3-8]. This pathogen is often reported in immunosuppressed hosts and as part of polymicrobial infections [3]. It has been isolated from a number of specimens including blood; wound exudate, synovial, cerebrospinal, and peritoneal fluid [4]. We intend to present the most up to date summary of *Leclercia adecarboxylata* infections including patient demographics, details of clinical infection and treatment protocols.

### Case Report

A previously healthy 32-year-old female pedestrian was struck by a motor vehicle at 35 miles/hr. Her injuries included skull fractures with intracranial bleeding and orthopaedic injuries. The patient required immediate EVD placement followed by hemicraniectomy and hematoma evacuation. On day three, routine culturing of EVD fluid yielded heavy *Leclercia adecarboxylata* found to be sensitive to ampicillin, ceftriaxone, gentamycin and meropenem. The infectious disease team recommended treatment with Meropenem (1 gram q8h). Multi-organ failure secondary to sepsis, declining neurological status and poor prognosis ultimately lead to the decision to withdraw care. On day 10 the patient was extubated and passed away.

### Methods

#### Search strategy and selection criteria

A systematic review identified relevant studies published through PubMed, Medline and ProQuest until July 2015. Search terms included "*Leclercia adecarboxylata*" and "*Escherichia adecarboxylata*".

All study types were included in the initial search, including abstracts and pending publications available. Non-electronic versions were requested. Bibliographies were reviewed to identify additional studies. Inclusion criteria required the publications to be pertaining to human subjects. Literature void of clinical infections were excluded. Non-English studies were excluded unless abstracts or translated data were available.

Two authors (J.S. and H.S.) independently reviewed the articles. Disagreements on consensus of inclusion or exclusion were arbitrated by a third author (J.M.).

**\*Corresponding author:** Claire Temple-Oberle, Division of Surgical Oncology, Department of Surgery, University of Calgary, 1331 29 St NW T2A4N2, Calgary, Canada, Tel: 1403-220-5110; E-mail: [Claire.Temple-Oberle@albertahealthservices.ca](mailto:Claire.Temple-Oberle@albertahealthservices.ca)

**Received** June 11, 2015; **Accepted** July 19, 2015; **Published** July 23, 2015

**Citation:** Stone JP, Denis-Katz HS, Temple-Oberle C, Mercier P, Mizzau JB, et al. (2015) *Leclercia adecarboxylata*: The First Reported Infection of Cerebrospinal Fluid and a Systematic Review of the Literature. J Neuroinfect Dis 6: 181. doi:10.4172/2314-7326.1000181

**Copyright:** © 2015 Stone JP, et al. This is an open-access article distributed under the terms of the Creative Commons Attribution License, which permits unrestricted use, distribution, and reproduction in any medium, provided the original author and source are credited.

## Data extraction and outcomes

Title, author, journal and impact factor, publication year and study type were recorded. Data collected included the following: (1) Patient demographics (2) Past medical history (3) Clinical history surrounding infection (4) Co-infection of microorganisms (5) Antibiotic resistance (6) Intervention and treatment (7) Patient outcome.

## Results

### Study selection

Using the previously described search method, 165 articles were identified. Ninety-nine articles did not meet inclusion criteria and 40 duplicates were removed. The remaining 27 articles were screened by title and abstract. Review of the full articles yielded an additional twenty-three papers and secondary assessment of inclusion criteria excluded an additional five (Figure 1).

A total of 50 patients from 40 sources were included in our review. Six articles included more than one case [7,9-13]. The remaining 34 articles presented singular cases. Two case reports were published with reviews of the literature [4,6]. Eight patient cases were identified in the reviews of the literature that were unavailable to access (electronically, by loan, or no longer available in print) [12,14-18]. Data was extracted from these articles to be included in our analysis. No higher level of evidence publication was identified (case series and case reports only).

### Study characteristics and quality assessment

Methodological quality assessment using Jadad composite scale and MINORS could not be completed due to the low level of evidence. A modified CARE (Case Report) checklist [19] for case report and journal impact factor were alternatively assessed to comment on quality. Impact factor of journals ranged from 0 - 9.177 (mean 2.39). The CARE checklist score ranged from 17-28 of the possible 30 points attainable. Patient cases identified in the reviews of the literature were included in our data extraction without being applied to the CARE checklist if they were unavailable. The Newcastle-Ottawa Assessment Scale (NOS) for assessing the quality of nonrandomized studies was applied to the

case series retrieved [19]. The three themes, selection, comparability and exposure, were applied to Prakash, Anuradha, Temegsen, and Forrester, scoring two, three, four and two stars respectively. Other sources of potential bias were examined for during the course of our review and further outlined in the discussion.

### Outcomes

Patient demographics and pertinent clinical data were extracted by two independent investigators and recorded in Table 1 [20-43]. Our case was included in the analysis that follows. Fifty-one cases comprised of eighteen female, twenty-four male, and nine unknown patients ranging in age from 24w to 81 years. Six pediatric patients were identified (24w, 26w, 8mo, 5yr, 8yr, 11yr). Four patient cases had no past medical history included and nine were reported as previously healthy. The remainder of the subjects (n=38, 71%) had concomitant comorbidities and/or immunocompromised states. These included patients with history of substance abuse, patients undergoing chemotherapy, and chronic systemic diseases such as end-stage-renal-disease and cardiovascular disease (Table 1). Of the previously healthy patients, *Leclercia* isolates were identified in six wound cultures following trauma, in a tracheal aspirate, gluteal abscess aspirate, blood following a burn, stump wound, foot wound, and in the CSF fluid of the current case presented.

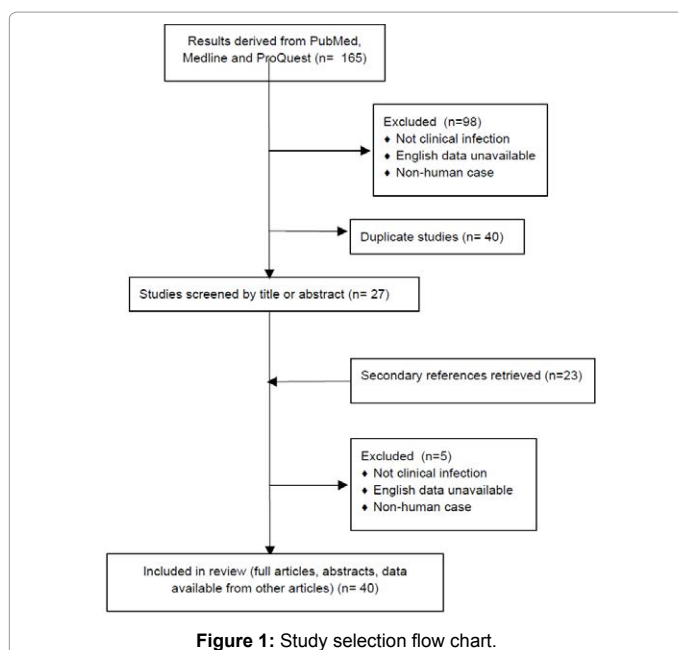
*Leclercia adecarboxylata* was isolated from a variety of sources of which blood and wound cultures were most frequently (seventeen and eleven respectively). Thirty-four cases were monomicrobial and fifteen were polymicrobial (two not reported).

Twenty-six *Leclercia* isolates were susceptible to all antimicrobials tested. Eight cases did not comment on antibiotic resistance and the remainder had varying resistance to sulfamethoxazole and trimethoprim, broad and extended spectrum beta-lactams, aminoglycoside, cephalosporin, and fosfomycin antibiotics (Table 2). The majority of patients improved with the appropriate antibiotic course tailored to the microbe's sensitivity profile. Antibiotic choice and duration of treatment are presented in Table 2 (duration or antibiotic choice not recorded if unavailable). There were four cases which resulted in death including the current case presented.

### Discussion

Emerging antimicrobial resistance is beginning to distinguish this as a potentially difficult pathogen [21]. Of the antimicrobial resistance profiles reported, nineteen were pansensitive. In vitro studies show this pathogen to be naturally resistant to lincosamides, ketolides, streptogramins, linezolid, glycopeptides, penicillin G, oxacillin, erythromycin, roxithromycin, clarithromycin, rifampicin, fusidic acid, and fosfomycin [22]. The appearance of extended beta-lactamase resistance proves to pose a threat to clinicians in their treatment choices [23]. An optimal antibiotic regime has not been established for this pathogen as of yet, but with further research and clinical experience one can be founded [24]. The clinician should be aware of the emergence of resistance *Leclercia* strains and tailor treatments based on sensitivities of their case at hand.

*Leclercia adecarboxylata* is often described as an opportunistic pathogen [3]. The majority of patients had underlying medical issues or immunocompromised states. These included alcohol abuse, cancer, and chronic systemic diseases such as end-stage-renal-disease and cardiovascular disease. Our study highlights this rare pathogen as a cause of infection predominantly in the immunocompromised host as other authors have previously suggested. Of absolute paramount, *Leclercia adecarboxylata* also is a threat in previously healthy patients.



Reference	ID	Co-morbidities	Clinical infection	Culture source	Co-infecting organisms
Stock et al. [20]	32 F	Multi-system trauma	Sepsis following open skull fracture	CSF	None
Prakash et al. [13]	41 M	None	Severe head injury following MVA, developed ventilator-associated pneumonia (VAP)	Tracheal aspirate	None
	32 F	None	ACA aneurysm with sub-arachnoid hemorrhage, multiple surgical procedures and prolonged ventilation, then developed VAP	Tracheal aspirate	None
	32 M	HIV positive (CD4 count 180) and non-Hodgkin's lymphoma	Vertebral tuberculosis, laminectomy and C6-7 decompression, POD#5 pneumonia	Tracheal culture	None
Anuradha [7]	31 F	None	1 wk hx of foul smelling vaginal discharge	Vaginal discharge	None
	50 M	None	Gluteal abscess	Pus	None
Kashani et al. [8]	43 F	Asthma	Ulcerative colitis, PICC line and sepsis	Blood	None
Keren et al. [21]	46 M	None	Soft tissue infection dorsum of left foot (laceration from surfboard's fin)	Wound swabs	Enterobacter cloacae
Haji et al. [22]	70 M	None	Arthritis in the DIP and PIP joints of the fingers	Blood	None
Chao et al. [23]	48 F	Diabetic nephropathy, on PD	PD peritonitis	Dialysate	None
De Mauri et al. [24]	81 M	ESRD secondary to HTN, on HD	Sepsis post dialysis	Blood	None
Nelson et al. [25]	24w F	Premature	Gastric perforation	Blood	None
Zapor et al. [6]	25 M	None	Chronic infection secondary to foreign body	Gluteus abscess	None
Bali et al. [3]	32 M	None	Peritonsillar abscess	Aspirate (PTA)	None
Tam and Nayak [26]	81 M	Diabetes, gout, and HTN	Right leg cellulitis	Wound	<i>S. aureus</i> , <i>S. pyogenes</i> , <i>E. cloacae</i>
Shin et al. [27]	47 F	Chemotherapy for breast Ca	Sepsis	Blood, PICC line	None
Forrester et al. [4]	55 M	EtOH abuse, multi-system trauma	Sepsis	Blood, CVC line	<i>S. pneumoniae</i> , <i>H. influenza</i>
Myers et al. [28]	26w F	Premature, respiratory distress, previous coag neg staph (CoNS)	Sepsis	Blood	None
Shah et al. [2]	8 M	Acute lymphoid leukemia	Cellulitis	Wound	None
Fernandez-Ruiz [9]	81 M	ESRD secondary to DM, radical nephrectomy for adenocarcinoma	Sepsis	Blood from tunneled catheter	None
	72 M	HD for ESRD secondary to HTN, immunosuppression for heart transplant	Sepsis	Blood from tunneled catheter	<i>P. agglomerans</i>
Lee et al. [1]	48 F	Endometrial adenocarcinoma and radiotherapy	Endocarditis	Blood	None
Dalamaga et al. [29]	53 M	4 % TBSA chemical burn	Sepsis	Blood	None
Dalamaga et al. [30]	30 M	T10 parapalegic	Sepsis	Urine	None
Corti et al. [31]	37 M	Multisystem trauma MVC	Stump infection following BKA	Surgical wound	<i>E. amnigenus</i> , <i>Absidia spp.</i>
Kim et al. [32]	71 M	Hepatitis C cirrhosis, hepatocellular carcinoma	Sepsis	Blood, peritoneal fluid	None
Jover Saenz et al. [33]	81 F	Diabetes mellitus	Gangrenous calculous cholecystitis	Biliary fluid	None
Hess et al. [5]	40 F	None	Right foot wound	Abscess	None
Sawamura et al. [34]	Un-known	Bladder malignancy	Unknown	Urine	<i>E. faecalis</i>
Beltran et al. [35]	Un-known	Diabetes mellitus	Unknown	Wound	None
Mazzariol et al. [36]	58 M	Acute myeloid leukemia	Unknown	Blood	None
Perez-Moreno et al. [37]	Un-known	Unknown	Septic arthritis	Synovial fluid	None
Rodriguez et al. [38]	Un-known	ESRD, peritoneal dialysis	Unknown	Peritoneal fluid	<i>A. iwoffii</i>
De Baere et al. [10]	78yo F	<i>Candida</i> sepsis and hospital-acquired pneumonia	Biliary pancreatitis and cholecystitis	Gallbladder tissue	<i>Streptococcus spp.</i> , <i>Enterococcus spp.</i>
	80 F	Pneumonia and <i>C. albicans</i> sepsis post 4 vessel CABG	Sepsis	Blood	<i>E. faecalis</i> , <i>E. hermannii</i>
Longhurst and West [39]	11 F	Acute lymphoid leukemia	Mucositis, diaper dermatitis, and anal fissure	Blood	<i>S. aureus</i>

Fattal and Deville [40]	5 M	ESRD of unknown etiology and dialysis	Sepsis post dialysis	Peritoneal fluid	None
De la Odra [41]	42 F	Multiple myeloma treated with chemotherapy and bone marrow transplant (BMT)	Sepsis following BMT	Blood	None
Lee, et al. [42]	48 F	Leiomyosarcoma and chemotherapy	Sepsis	Blood	<i>E. hermannii</i>
Hwang, et al. [14]	60 M	HD for ESRD secondary to diabetes	Sepsis	Dialysate	None
Martinez, et al. [15]	Unknown	Diabetes mellitus	Unknown	Wound	None
Temesgen, et al. [11]	43 F	None	Right calf cellulitis secondary to trauma	Wound	<i>S. aureus</i>
	35 M	None	Crush injury to right foot causing compound fractures	Wound	<i>E. cloacae</i> , <i>C. freundii</i> , <i>S. pneumoniae</i> , <i>S. maltophilia</i> , and spp. of <i>Corynebacterium</i> , <i>Acremonium</i> , <i>Penicillium</i> , <i>Mucor</i> , <i>Enterococcus</i> , <i>Geotrichum</i>
	23 M	None	Foot punctured with nail	Wound	<i>A. calcoaceticus</i> , <i>E. agglomerans</i>
	35 F	Acute nonlymphocytic leukemia	Fever following allogeneic bone marrow transplantation	Blood	None
	54 M	Still's disease, post-op inguinal hernia repair	RLL pneumonia	Sputum	<i>E. coli</i> , <i>K. oxytoca</i> , <i>H. influenzae</i>
Dudkiewicz and Szezyk [16]	Unknown	Unknown	Bacterial endocarditis patients, other not reported	Cardiac valve	Unknown
Daza et al. [17]	Unknown	Cirrhosis	Unknown	Blood	None
Cai et al. [12]	Unknown	Previous four-vessel CABG	Unknown	Blood	None
	Unknown	Unknown	Unknown	Gallbladder	Unknown
Otani and Bruckner [18]	8 mM	Infant on TPN with intestinal atresia	Unknown	Blood	None

Table 1: Reported cases of *Leclercia Adecaboxylata* infection.

Reference	Antibiotic resistance	Treatment	Outcome
<b>Current case</b>	Susceptible to all	Meropenem 1 g IV q8h	Death
Prakash et al. [13]	Susceptible to all but ampicillin	Amikacin 80 mg IV daily	Recovered
	Susceptible to all	Imipenem 1 g IV q6h and amikacin 80 mg IV daily x 1 wk	Recovered
	Susceptible to all		Death
Anuradha [7]	Susceptible to all but fosfomycin	Moxifloxacin 400 mg once daily for 10 days	Recovered
	Susceptible to all	Doxycycline 100 mg BID for 10 days	Recovered
Kashani et al. [8]	Susceptible to all	Ceftriaxone IV	Recovered
Keren et al. [21]	Susceptible to all	Empirically with amoxicillin-clavulanate IV and ciprofloxacin, then amoxicillin-clavulanate was stopped, and the patient was treated with ciprofloxacin PO for 14 days	Recovered
Haji et al. [22]		Tazobactam/piperacillin	
Chao et al. [23]	Susceptible to all	Intraperitoneal ceftazidime and ceftazidime empirically, then Intraperitoneal ceftazidime was discontinued	Recovered
De Mauri et al. [24]	Susceptible to all	Gentamicin IV x 1w Amoxicillin-Clavulanic acid 500 mg BID x 3w lock therapy with gentamicin 15 mg/ml x 4w	Recovered
Nelson et al. [25]	Susceptible to all	Exploratory laparotomy and primary closure of perforation Empirical IV ampicillin, gentamicin and clindamycin x 7d followed by cefotaxime x 3w	Death
Zapor et al. [6]	Amoxicillin-Clavulanate, Ampicillin-Sulbactam, Cefazolin	Ciprofloxacin 750 mg BID x 10d Surgical debridement	Recovered
Bali et al. [3]	Susceptible to all	I&D followed by Clavulin 1.2 gm TID and metronidazole 500 mg TID IV and oral	Recovered
Tam and Nayak [26]	Susceptible to all	Empirical clindamycin, vancomycin and ceftazidime followed by 10 days of cefixime	Recovered
Shin et al. [27]	Aminoglycosides, TMP-SMX, most Beta-lactams, and broad-spectrum Cephalosporin	Cefepime IV	Recovered

Forrester et al. [4]	Susceptible to all	Vancomycin 1 g IV q12h, Piperacillin-Tazobactam 3.375 g IV q6h and azithromycin 500 mg OD for 5d followed by cefazolin 1 g q8h	Recovered
Myers et al. [28]	Intermediate to ampicillin	Empirically cefotaxime and gentamycin Followed by cefotaxim x 14d	Recovered
Shah et al. [2]	Susceptible to all	Empiric cefepime, vancomycin, and gentamicin followed by 2 weeks of oral clindamycin and ciprofloxacin	Recovered
Fernandez-Ruiz [9]	Fosfomycin	Ceftriaxone 2 g IV q24h x 15d catheter locking daily with ciprofloxacin (2 mg/ml added to sodium heparin)	Recovered
	Susceptible to all	Catheter lock therapy using gentamicin (2 mg/ml added to sodium heparin) meropenem 500 mg IV q24h x 15d	Unknown
Lee et al. [1]	Susceptible to all	Ampicillin-sulbactam (12–6 g/d)1 and gentamicin (150 mg/d) x 4w	Recovered
Dalamaga et al. [29]	Gentamicin, tobramycin, ampicillin, amoxicillin/clavulanate, cefazolin, piperacillin, and co-trimoxazole	ceftriaxone 1 g IV q8h and amikacin 500 mg q12h x 12d	Recovered
Dalamaga et al. [30]	Unknown	Unknown	Unknown
Corti et al. [31]	Susceptible to all	Initially: teicoplanin 400 mg/day (after a loading dose of 800 mg), tobramycin (300 mg/day) and metronidazole (500 mg QID) x 14d followed by piptazo (4.5 TID) for unknown duration, liposomal amphotericin B x 15d	Recovered
Kim et al. [32]	Ampicillin, moderately to piperacillin	IV cefoperazone and ciprofloxacin	Death
Jover Saenz et al. [33]	Fosfomycin	Cholecystectomy, Ertapenem IV x 48h followed by oral amoxicillin-clavulanic acid x 12d	Recovered
Hess et al. [5]	Unknown	Moxifloxacin IV for unknown duration	Recovered
Sawamura et al. [34]	Susceptible to all	Unknown	Unknown
Beltran et al. [35]	ESBL	Unknown	Unknown
Mazzariol et al. [36]	Ceftazidime, cefotaxime, cefepime, penicillin G, amoxicillin, aztreonam, ESBL producing	Unknown	Unknown
Perez-Moreno et al. [37]	Fosfomycin	Unknown	Unknown
Rodriguez et al. [38]	Susceptible to all	Unknown	Unknown
De Baere et al. [10]	Susceptible to all	Imipenem and fluconazole, ERCP, followed 3 months later with elective cholecystectomy	Recovered
	Ampicillin	Diflucan and cefotaxime	Unknown
Longhurst and West [39]	Susceptible to all	IV gentamicin and ciprofloxacin for 5 days followed by 10-days of IV gentamicin and cefazolin	Recovered
Fattal and Deville [40]	Susceptible to all	IV and peritoneal ceftazidime and gentamicin x 10d	Recovered
De la Obra [41]	Fosomycin	Cloxacillin and cefuroxime empirically followed by ciprofloxacin for unknown duration	Recovered
Lee et al. [42005D]	Ampicillin	Unknown	Unknown
Hwang et al. [14]	Susceptible to all	Amikacin and cephalothin in diasylate	Recovered
Martinez et al. [15]	Unknown	Unknown	Unknown
Temesgen et al. [11]	Susceptible to all	Oral ciprofloxacin	Recovered
	Unknown	Amputation of foot and 24d of IV antimicrobials including one or more of the following at any one time: cefazolin, ampicillin-sulbactam, ticarcillin-clavulanic acid, and ceftazidime	Unknown
	Unknown	Oral ciprofloxacin	Recovered
	Susceptible to all	Vancomycin and ceftazidime	Death from underlying disease
	Susceptible to all	IV Aztreonam, followed by oral ciprofloxacin	
Dudkiewicz and Sze-wczyk [16]	Unknown	Unknown	Unknown
Daza et al. [17]	Unknown	Unknown	Unknown
Cai et al. [12]	Ampicillin	Unknown	Unknown
	Unknown	Unknown	Unknown
Otani and Bruckner [18]	Susceptible to all	Unknown	Recovered

**Table 2:** Antibiotic resistance and treatment of *leclercia adecarboxylata* infections

*Leclercia adecarboxylata* was initially believed to be dependent on co-infecting microorganisms [23]. Our review reveals that the majority were monomicrobial infections (26 of 42 reported, 64%). This may be underreported as not all papers commented on the absence of other microorganism (n=2). It seems unlikely that this microorganism is dependent on co-infection and as such, we do not agree that its infectious role is contingent on other microorganisms [2]. We cannot support previous claims that infections were synergistically working together to enhance overall virulence although logically, multiple infections may be more difficult to overcome [4].

We report of the first cerebral spinal fluid infection with *Leclercia adecarboxylata*. Our case additionally highlights a monomicrobial infection in a formerly healthy patient, a demographic previously underappreciated in the literature.

## Conclusion

As the number of *L. adecarboxylata* infections continues to expand so does our insight into its pathogenicity and role in human clinical infections.



## References

- Lee B, Sir JJ, Park SW, Kwak CH, Kim SM, et al. (2009) A case of *Leclercia adecarboxylata* endocarditis in a woman with endometrial cancer. *Am J Med Sci* 337: 146-147.
- Shah A, Nguyen J, Sullivan LM, Chikwava KR, Yan AC, et al. (2011) *Leclercia adecarboxylata* cellulitis in a child with acute lymphoblastic leukemia. *Pediatr Dermatol* 28: 162-164.
- Bali R, Sharma P, Gupta K, Nagrath S (2013) Pharyngeal and peritonsillar abscess due to *Leclercia adecarboxylata* in an immunocompetent patient. *J Infect Dev Ctries* 7: 46-50.
- Forrester JD, Adams J, Sawyer RG (2012) *Leclercia adecarboxylata* bacteremia in a trauma patient: case report and review of the literature. *Surg Infect (Larchmt)* 13: 63-66.
- Hess B, Burchett A, Huntington MK (2008) *Leclercia adecarboxylata* in an immunocompetent patient. *J Med Microbiol* 57: 896-898.
- Michael Z, McGann PT, Alao O, Stevenson L, Lesho E, et al. (2013) Isolation of *Leclercia adecarboxylata* from an infected war wound in an immune competent patient. *Mil Med* 178: e390-393.
- Anuradha M (2014) *Leclercia adecarboxylata* isolation: case reports and review. *J Clin Diagn Res* 8: DD03-04.
- Kashani A, Chitsazan M, Che K, Garrison RC (2014) *Leclercia adecarboxylata* Bacteremia in a Patient with Ulcerative Colitis. *Case Rep Gastrointest Med* 2014: 457687.
- Fernandez-Ruiz M, Lopez-Medrano F, Garcia-Sanchez L, Garcia-Reyne A, Ortuno de Solo T, et al. (2009) Successful management of tunneled hemodialysis catheter-related bacteremia by *Leclercia adecarboxylata* without catheter removal: report of two cases. *International Journal of Infectious Diseases* 13:517-518.
- de Baere T, Wauters G, Huylenbroeck A, Claeys G, Peleman R, et al. (2001) Isolations of *Leclercia adecarboxylata* from a patient with a chronically inflamed gallbladder and from a patient with sepsis without focus. *J Clin Microbiol* 39: 1674-1675.
- Temesgen Z, Toal DR, Cockerill FR 3rd (1997) *Leclercia adecarboxylata* infections: case report and review. *Clin Infect Dis* 25: 79-81.
- Cai M, Dong X, Wei J, Yang F, Xu D, et al. (1992) [Isolation and identification of *Leclercia adecarboxylata* in clinical isolates in China]. *Wei Sheng Wu Xue Bao* 32: 119-123.
- Prakash MR, Ravikumar R, Patra N, Indiradevi B (2015) Hospital-acquired pneumonia due to *Leclercia adecarboxylata* in a neurosurgical centre. *J Postgrad Med* 61: 123-125.
- Hwang HY, Jeong SH, Rim H, et al. (1998) A case of *Leclercia adecarboxylata* isolated from dialysate in a patient with continuous ambulatory peritoneal dialysis. *Korean Clin Microbiol* 1: 11311-11316.
- Martínez MM, Sánchez G, Gómez J, Mendaza P, Daza RM (1998) [Isolation of *Leclercia adecarboxylata* in ulcer exudate]. *Enferm Infecc Microbiol Clin* 16: 345.
- Dudkiewicz B, Szewczyk E (1993) [Etiology of bacterial endocarditis in materials from Cardiology and Cardiac Surgery Clinics of the Lodz Academy]. *Med Dosw Mikrobiol* 45: 357-359.
- Daza RM, Iborra J, Alonso N, Vera I, Portero F, et al. (1993) [Isolation of *Leclercia adecarboxylata* in a cirrhotic patient]. *Enferm Infecc Microbiol Clin* 11: 53-54.
- Otani E, Bruckner DA (1991) *Leclercia adecarboxylata* isolated from blood culture. *Clin Microbiol Newslett* 13: 157-158.
- Gagnier JJ, Kienle G, Altman DG, Moher D, Sox H, et al. (2013) The CARE guidelines: consensus-based clinical case reporting guideline development. *Headache* 53: 1541-1547.
- Stock I, Burak S, Wiedemann B (2004) Natural antimicrobial susceptibility patterns and biochemical profiles of *Leclercia adecarboxylata* strains. *Clin Microbiol Infect* 10: 724-733.
- Keren Y, Keshet D, Eidelman M, Geffen Y, Raz-Pasteur A, et al. (2014) Is *Leclercia adecarboxylata* a new and unfamiliar marine pathogen? *J Clin Microbiol* 52: 1775-1776.
- Haji S, Kimura H, Yamashita H (2014) Arthritis and bacteremia due to *Leclercia adecarboxylata*. *Intern Med* 53: 2659.
- Chao CT, Hung PH, Huang JW, Tsai HB (2014) Cycloer cassette rupture with *Leclercia adecarboxylata* peritoneal dialysis peritonitis. *Perit Dial Int* 34: 131-132.
- De Mauri A, Chiarinotti D, Andreoni S, Molinari GL, Conti N, et al. (2013) *Leclercia adecarboxylata* and catheter-related bacteraemia: review of the literature and outcome with regard to catheters and patients. *J Med Microbiol* 62: 1620-1623.
- Nelson MU, Maksimova Y, Schulz V, Bizzarro MJ, Gallagher PG (2013) Late-onset *Leclercia adecarboxylata* sepsis in a premature neonate. *J Perinatol* 33: 740-742.
- Tam V, Nayak S (2012) Isolation of *Leclercia adecarboxylata* from a wound infection after exposure to hurricane-related floodwater. *BMJ Case Rep* 2012.
- Shin GW, You MJ, Lee HS, Lee CS (2012) Catheter-related bacteremia caused by multidrug-resistant *Leclercia adecarboxylata* in a patient with breast cancer. *J Clin Microbiol* 50: 3129-3132.
- Myers KA, Jeffery RM, Lodha A (2012) Late-onset *Leclercia adecarboxylata* bacteraemia in a premature infant in the NICU. *Acta Paediatr* 101: e37-39.
- Dalamaga M, Pantelaki M, Karmaniolas K, Daskalopoulou K, Migdalis I (2009) Isolation of *Leclercia adecarboxylata* from blood and burn wound after a hydrofluoric acid chemical injury. *Burns* 35: 443-445.
- Dalamaga M, Pantelaki M, Papadavid E, Daskalopoulou K, Karmaniolas K (2008) [Epididymo-orchitis and bacteremia caused by *Leclercia adecarboxylata*]. *Med Mal Infect* 38: 674-675.
- Corti G, Mondanelli N, Losco M, Bartolini L, Fontanelli A, et al. (2009) Post-traumatic infection of the lower limb caused by rare Enterobacteriaceae and Mucorales in a young healthy male. *Int J Infect Dis* 13: e57-60.
- Kim, H, Chon C, Ahn S, Jung S, Han K, et al. (2008) Fatal spontaneous bacterial peritonitis by *Leclercia adecarboxylata* in a patient with hepatocellular carcinoma. *International journal of clinical practice* 62: 1296-1298.
- Jover Sáenz A, Cerezo-Esforzado E, Barcenilla-Gaite F, Garrido-Calvo S, Porcel- Pérez J (2008) *Leclercia adecarboxylata* cholecystitis in a patient with metabolic syndrome. *Surgical infections* 9: 411-412.
- Sawamura H, Kawamura Y, Yasuda M, Ohkusu K, Takahashi Y, et al. (2005) [A clinical isolate of *Leclercia adecarboxylata* from a patient of pyelonephritis]. *Kansenshogaku Zasshi* 79: 831-835.
- Beltrán A, Molinero AV, Capilla S, Polo AM (2004) [Isolation of *Leclercia adecarboxylata* from wound exudate of a diabetic patient]. *Med Clin (Barc)* 122: 159.
- Mazzariol A, Zuliani J, Fontana R, Cornaglia G (2003) Isolation from blood culture of a *Leclercia adecarboxylata* strain producing an SHV-12 extended-spectrum beta-lactamase. *J Clin Microbiol* 41: 1738-1739.
- Pérez-Moreno MO, Anguera J, Carulla M, Pérez-Moreno M (2003) [Septic arthritis due to *Leclercia adecarboxylata* of probable iatrogenic origin]. *Enferm Infecc Microbiol Clin* 21: 167-168.
- Rodríguez JA, Sánchez FJ, Gutiérrez N, García JE, García-Rodríguez JA (2001) [Bacterial peritonitis due to *Leclercia adecarboxylata* in a patient undergoing peritoneal dialysis]. *Enferm Infecc Microbiol Clin* 19: 237-238.
- Longhurst CA, West DC (2001) Isolation of *Leclercia adecarboxylata* from an infant with acute lymphoblastic leukemia. *Clin Infect Dis* 32: 1659.
- Fattal O, Deville JG (2000) *Leclercia adecarboxylata* peritonitis in a child receiving chronic peritoneal dialysis. *Pediatr Nephrol* 15: 186-187.
- De la Obra P, Domingo D, Casaseca R, Del Rey M, Lopez-Brea M (1999) Bacteremia due to *Leclercia adecarboxylata* in a patient with multiple myeloma. *Clin Microbiol Newsletter* 21: 142-3.
- Lee NY, Ki CS, Kang WK (1999) Hickman catheter-associated bacteremia by *Leclercia adecarboxylata* and *Escherichia hermannii*: A case report. *Korean J Infect Dis* 31: 167-170.
- [www.ohri.ca/programs/clinical\\_epidemiology/oxford.asp](http://www.ohri.ca/programs/clinical_epidemiology/oxford.asp)

**Citation:** Stone JP, Denis-Katz HS, Temple-Oberle C, Mercier P, Mizzau JB, et al. (2015) *Leclercia adecarboxylata*: The First Reported Infection of Cerebrospinal Fluid and a Systematic Review of the Literature. *J Neuroinfect Dis* 6: 181. doi:[10.4172/2314-7326.1000181](https://doi.org/10.4172/2314-7326.1000181)