

Lumbar Percutaneous Intradiscal Injection of Radiopaque Gelified Ethanol (“Discogel”) in Patients with Low Back and Radicular Pain

Volpentesta G¹, De Rose M¹, Bosco D³, Stroschio C¹, Guzzi G¹, Bombardieri C², Chirchiglia D¹, Plastino M³, Romano M¹, Cristofalo S³, Pardatscher K² and Lavano A^{1*}

¹Department of Neurosurgery, University Hospital of Germaneto, Campus “Salvatore Venuta”, Catanzaro, Italy

²Department of Neuroradiology, University Hospital of Germaneto, Campus “Salvatore Venuta”, Catanzaro, Italy

³Department of Neurology, “San Giovanni di Dio” General Hospital, Crotona, Italy

*Corresponding author: Lavano A, Department of Neurosurgery, University Hospital of Germaneto, Campus “Salvatore Venuta”, Viale Europa, 88100 Catanzaro, Italy, Tel: +3909613647385; E-mail: lavano@unicz.it

Rec date: Apr 04, 2014, Acc date: Apr 27, 2014, Pub date: April 29, 2014

Copyright: © 2014 Volpentesta G, et al. This is an open-access article distributed under the terms of the Creative Commons Attribution License, which permits unrestricted use, distribution, and reproduction in any medium, provided the original author and source are credited.

Abstract

Partial removal of nucleus pulposus with consequent reduction of intradiscal pressure may be obtained with percutaneous intradiscal administration of chemical substances in the intervertebral disc. We used percutaneous intradiscal injection of radiopaque gelified ethanol (“Discogel”) in 72 patients (group 1) with conservative treatment resistant lumbar and radicular pain due to small and medium-size hernias of intervertebral disc to demonstrate its efficacy and safety vs. 72 subjects treated with intra-foraminal and intradiscal injections of a steroid and anesthetic (group 2 or control group). “Discogel” injection was performed with biplane fluoroscopy assistance and under local anesthesia with patient in lateral position on symptomatic side. Amount of “Discogel” injected ranged from 0.8 ml to 1.6 ml. We treated a total of 83 discs. We performed the procedure on one disc in 62 patients; in 9 patients two discs were treated in the same session and in 1 patient three levels were treated in two separate sessions.

In group 1 patient “responders” were 65 (90.3%). Excellent and good results were obtained in 58 patients (80.4%), satisfactory results in 7 patients (9.8%) and poor results in 7 patients (9.8%); among “responders” pain control was quite immediate in 58 patients (89.3%) while in 7 patients (10.7%) there was a delay of 7-10 days. These values were significantly higher than in control group. Also the quality of life was significantly more sustained vs. control group, and this benefit was maintained over time. Concerning complications, in 3 cases (4.15%) we had transitory radicular irritation with neuropathic pain appearance immediately after the procedure and in 1 case (1.30%) transitory sensory-motor deficit due to diffusion of local anesthetic along the introducer needle.

In conclusion intradiscal radiopaque gelified ethanol injection is minimally invasive, low cost, safe and effective procedure that may be considered in proper selected patients before recourse to surgery.

Keywords: Percutaneous intradiscal ethanol; Discogel; Lumbar disc herniation

Methods

Patients

The study protocol was approved by the ethical Committee of our Institution. We obtained informed consent from all patients. Between November 2008 and February 2012, we treated 144 patients with lumbar disc herniation and radicular pain. Subjects were subdivided into two groups in accordance with their treatment: 72 patients treated with percutaneous intradiscal injection of radiopaque gelified ethanol (Discogel) (group 1) and 72 patients treated with intra-foraminal and intradiscal injection of steroid with anesthetic (group 2 or control group). Patients and controls were evaluated by an expert neurosurgery. Recorded medical data for both groups included: anamnestic data, demographic informations (age and sex) and smoking habits. All subjects were classified as non-smokers if they had never smoked. Smokers were further categorized according to the amount of cigarettes smoked daily (1-9, 10-19 or > 20 cigarettes/day). We also assessed: glucose levels, waist circumference (WC) and Body Mass Index (BMI). Depression score was also assessed with Montgomery Asberg Depression Rating Scale (MADRS) [7]. Preliminarily, all patients underwent to physical evaluation by

Introduction

Herniation of intervertebral disc is an important and common cause of lumbago and sciatica. Open surgery has been considered as its main treatment modality when conservative treatment has failed. Unfortunately 20% of the patients are still in pain after surgery and 7% to 15% develop the syndrome of failure of lumbar surgery [1,2]. For this reason during the last two decades minimally invasive percutaneous techniques have been developed as alternative treatment to micro-discectomy to improve the quality of life. Partial removal of the nucleus pulposus with consequent reduction of intradiscal pressure may be obtained with percutaneous intradiscal administration of chemical substances [3-6]. Yet, few of these treatments have been tested in controlled randomized studies.

We assessed the therapeutic outcome of percutaneous intradiscal injection of radiopaque gelified ethanol (Discogel) and compared the outcome of intra-foraminal and intradiscal injections of a steroid and an anesthetic in the management of radicular pain related to lumbar disk herniation.

neurosurgeons and neuroradiological examination with lumbar X-ray, MRI, CT-scan or both. 50 patients had low-back pain, 70 patients low-back pain with radicular pain and 24 radicular pains. All patients' symptoms were caused by uncalcified disc herniations of small and medium size, respectively grade 1 and 2 according to Michigan State University (MSU) Classification for herniated lumbar disc on MRI [8], in a congruent location. The symptomatic lumbar level was L3-L4 in 21 patients, L4-L5 in 50 patients and L5-S1 in 73 patients; the location of symptomatic disc herniation was central in 38 cases, lateral in 86 cases and far lateral in 20 cases. All patients complained of pain for at least two months, and received conservative therapy (intramuscularly steroidal, Non-steroidal anti-inflammatory drugs and/or muscle relaxants) for at least four weeks, with no or poor clinical improvement. No ropathic deficits resulted congruent with observed disc disease in all patients (their presence is an indication for open surgery). Pain Intensity and Health Related Quality of Life (HRQoL) were evaluated respectively with the Visual Analogue Scale (VAS) [9] and the Medical Outcome Study 36-items Short Form Health Survey (SF-36) [10] before surgery. Exclusion criteria comprised pregnancy, referred allergy to proposed drugs, major neurologic deficit (infection, inflammatory or neoplastic) sacro-ileitis, or previous spine surgery.

Study design

Patients were randomly assigned to one of the two groups (group 1 and group 2) by a randomization means grid: a single neurosurgeon unaffiliated with the trial used a table of random numbers to randomly assign participants to receive in a 1:1 ratio percutaneous intradiscal injection of radiopaque gellified ethanol (Discogel) (group 1) or intraforaminal and intradiscal injections of a steroid and anesthetic (group 2). Group 1 (Discogel) included 72 patients (38 men and 34 women; mean age 49.2) and group 2 included 72 patients (43 men and 29 women; mean age 51.8 years).

Procedure

In all patients procedure was performed in aseptic conditions, in the angiographic room with biplane digital fluoroscopy on lateral decubitus, the patient lying on the symptomatic side to perform the injection on the side opposite to the assumed structural disc damage. In group 1 percutaneous treatment with radiopaque gellified ethanol was offered as alternative to surgery. We often used a coaxial technique approaching the outer border of the disc percutaneously with an 18G x 152 mm needle and thereafter inserting a 22G x 200 mm needle in the center of nucleous pulposus parallel and at midway between the two end plates. The dose of "Discogel" slowly injected at room temperature through the 22G needle in the nucleous pulposus was 0.8 to 1.6 ml. We treated a total of 83 discs. We performed the procedure on a single disc in 72 patients, in 9 patients two discs were treated in the same session and in 1 patient three levels were treated in two separate sessions. All except one patient (due to technical fault of the CT device) had volumetric multislice CT study of the treated disc few hours after the procedure: the scan showed the "Discogel" diffusion in the nucleus pulposus and in its herniated section. In absence of complications, patients were discharged on the day after the procedure. Group 2 underwent intraforaminal and intradiscal injections of 2 ml of triamcinolone acetate, with 1 ml injected inside the disk, and 2-4 ml of 2% ropivacaine, about 2 ml injected inside the disk.

After treatments patients were evaluated by neurosurgeon assigned to follow-up that was not the same who performed procedures and

who was not aware of type of procedures made. In both groups follow-up was carried out at 1, 3, 6 months, 12 months and 18 months, assessing pain intensity on VAS scale, limitation on physical activity and HRQoL on SF-36 score. In group 2 also CT scan was performed at 1, 3 and 6 months after the surgery to assess the anatomic changes of the treated discs. The response to treatment was classified as: a. excellent result (pain totally disappeared, full recovery of physical activity); b. good result (pain improvement on the VAS score > 70%, no limitation on physical activity); c. satisfactory result (pain improvement on the VAS score > 50%, moderate limited physical activity); d. poor result (pain improvement on the VAS score < 50%, very limited physical activity).

Statistical analysis

Data were expressed as mean \pm Standard Deviation (SD). An ANOVA test for independent samples was performed to compare the means. An evaluation of the success risk was performed for both groups on the basis of the VAS and SF-36. The success rates at 1, 3, 6, 12 and 18 months follow-up for groups 1 and 2 were compared by means of the χ^2 -test. Analysis of covariance was used to test for differences in VAS and SF-36 score in both groups, after adjustment for parameters that resulted in differences determined by the ANOVA. Stepwise multivariate forward analysis has been used for confounding variables defined as variables that correlated to MMSE in univariate (i.e. age, sex, BMI, depression rating, smoking habits).

Results

Demographic and clinical features

During a period of four years, from 2008 to 2012, we screened prospectively 144 patients (81 men, 63 women; age ranged from 20 to 74 years) with lumbar disk herniation and radicular pain. Disease duration, age, sex, glycaemia, depression rating, smoking habits, pain type and lumbar level symptoms were significantly different between group 1 and 2. Data on smoking history were not available for three patients in group 1 and four patients in group 2. BMI and WC were greater in group 1 compared to group 2 (Table 1).

Therapeutic outcome

- In group 1 (intradiscal Discogel), after 3-months follow-up the treatment was a successful in 65 (90.3%; CI 80.6%-95.4%). In this group, excellent or good results were obtained in 58 patients (80.4%), satisfactory results in 7 patients (9.8%). In 7 patients (9.8%) we observed poor results. Five of these 7 patients underwent to open surgery for the persistence of severe lumbo-radiculargia resisting medical treatment with CT images of unchanged disc hernia: 3 patients after 1 month from "Discogel" injection and 2 patients after 4 months (Table 2).

Among the "responders" low back pain improvement was quite immediate (on the day of the procedure or on the day after) in 58 patients (89.3%) while in 7 patients (10.7%) there was a delay of 7-10 days; improvement of radicular pain was obtained in a period of 2 to 3 weeks.

At the beginning of the "Discogel" injection the majority of patients felt a heat sensation at the level of the injected disc that disappeared at the end of the procedure, probably due to irritation of the intersomatic disc nerve endings.

	Group 1	Group 2	P
Number patients	72	72	-
Age	51.8 (6.8)	49.2 (7.1)	-
Sex (M/F)	43/29	38/34	0.41
Disease duration (months ± SD)	8.3 (4.1)	7.9 (3.4)	0.39
Fasting Glycaemia (mg/dl)	80.8 (8.6)	81.6 (9.2)	0.42
BMI	23.8 (1.7)	21.7 (1.9)	0.05
Waist Circumference (cm)	85.4 (1.9)	82.5 (2.3)	0.002
MADRS	15.7 (9.5)	16.1 (7.4)	0.43
Smoking habits: N, %			
Smokers (1 – 9)	5 (5.8)	8 (11)	0.009
Smokers (10 – 19)	13 (18)	12 (16.6)	0.21
Smokers (> 20 cigarettes/die)	20 (27)	18 (25)	0.13
- no smokers	21 (29)	20 (26)	0.16
- not available	3 (4)	4 (5.5)	0.32
Pain type N°, %			
- Low back pain	27 (37.5)	23 (32)	0.19
- Low back pain + radicular pain	35 (48.6)	35 (48.6)	-
- Radicular pain	9 (12.5)	15 (21)	0.09
Symptomatic lumbar pain			
- L3-L4	11 (42)	10 (13.8)	0.61
- L4-L5	26 (36)	24 (33)	0.13
- L5-S1	35 (48.6)	38 (52.7)	0.44
MADRS: Montgomery Asberg Depression Rating Scale; BMI: Body Mass Index [Weight (kg)/height ² (h ²)			

Table 1: Demographic and Clinical Characteristics of 72 patients treated with percutaneous intradiscal injection of radiopaque gellified ethanol (Discogel) (Group 1) and 72 patients treated with intraforaminal and intradiscal injections of a steroid and an anesthetic. Value adjusted for BMI and WC. Values are expressed as mean (SD) unless otherwise indicated. P-Value of .05 was considered statistically significant

In 3 cases (4.15%) a radicular irritation with neuropathic pain appearance was evident immediately after the procedure. This condition was due to an excessive epidural leakage of the product with irritation of nerve-endings and improved within 10 days with steroidal anti-inflammatory therapy. In 1 case (1.30%) we observed a transitory sensory-motor deficit due to the diffusion of local anesthetic along the introducer needle: the deficit disappeared within 8 hours. No allergic complications were observed. Pain control was insignificantly unchanged at the 6, 12, 18 months follow-up (Figure 1). Also SF-36 QoL score improved significantly during the follow-up vs. group 2 (Figure 2). On CT scan performed at 1 and 3 months an iperdensity

image of "Discogel" was always evident in treated disc without modification of hernia volume; iperdensity image was still evident on CT scan performed at 6 months only in 10 of treated discs and reduction of hernia volume was documented in all "responders".

		β	SE	P
Model I	VAS	.373	.228	.006
Model II	SF-36	.329	.141	.024
	VAS	.763	.223	.001
VAS: Visual Analogue Scale; MADRS: Montgomery Asberg Depression Rating Scale; BMI: Body Mass Index [Weight (kg)/height ² (h ²)]; WC: Waist Circumference; SF-36: Short Form Health Survey				

Table 2: Treatment type (pharmacological or discogel) as dependent variable. VAS-score as independent variable. Excluded variables: Model I: glycaemia, age, sex, disease duration, BMI, WC, MADRS, SF-36, lumbar pain type, level of symptomatic lumbar pain and habit smoking. Model II: glycaemia, age, sex, disease duration, BMI, WC, MADRS, level of symptomatic lumbar pain and habit smoking

- In group 2, after 3-months of follow-up the treatment was a successful in 50 patients (69%; CI: 62%-74.4%); in the remaining 22 patients (30%; CI: 24.6%-34.5%) it failed. Among patients whose treatment was a successful, the outcome was excellent in 34 (47%) and good in 16 (22%). In group 1, among patients whose treatment failed, this was poor in 22 (30%) patients with recourse to surgery in 4 (5%). During or after the treatment, no major or minor complications were observed. Of the 50 patients with excellent benefit to the pharmacological treatment, three (4%) reported a rise of pain after 6-months, 9 (12.5%) after 12-months and 14 patients (19.9%) after 18-months, respectively (Figure 1). SF-36 QoL score showed initial improvement that was reduced in subsequent evaluations (6, 12 and 18-months) (Figure 2).

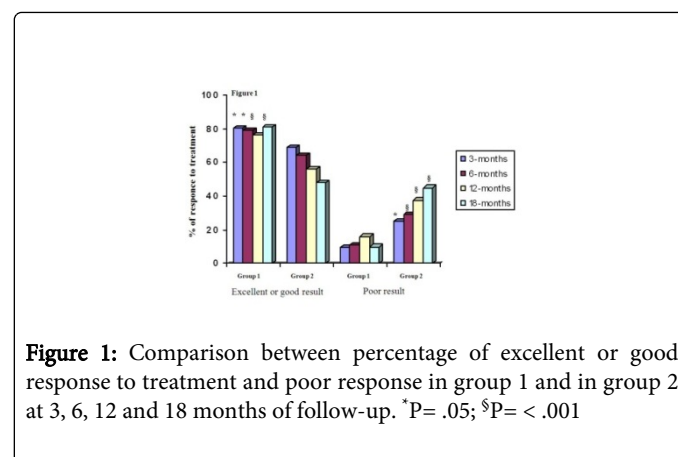
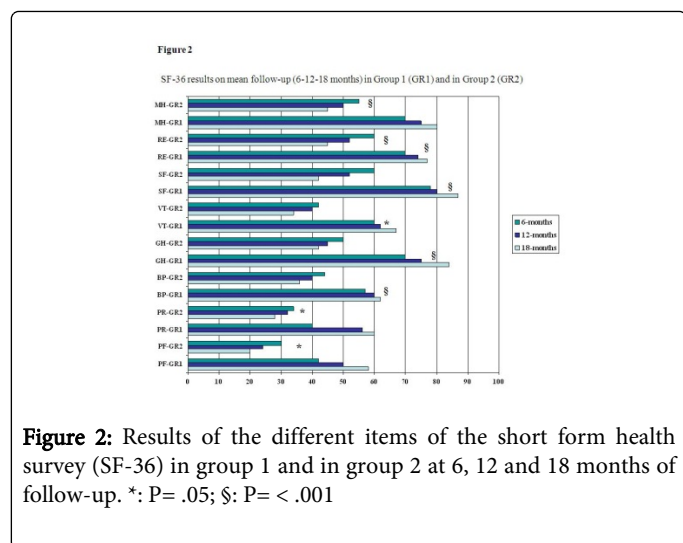


Figure 1: Comparison between percentage of excellent or good response to treatment and poor response in group 1 and in group 2 at 3, 6, 12 and 18 months of follow-up. *P= .05; §P= < .001

- Group 1 and group 2 comparison: the statistical analysis with χ^2 -test showed different outcome in every time of evaluation (1, 3, 6, 12 and 18 months). A multiple regression analysis was performed entering treatment type (pharmacological or Discogel) as dependent variable, and VAS-score as independent variables because the latter was alone significantly correlated with type of treatment in univariate analysis ($r=0.17$; $P=0.001$). We assessed, also as independent variables, potential confounders known to be risk factors for disc disease.



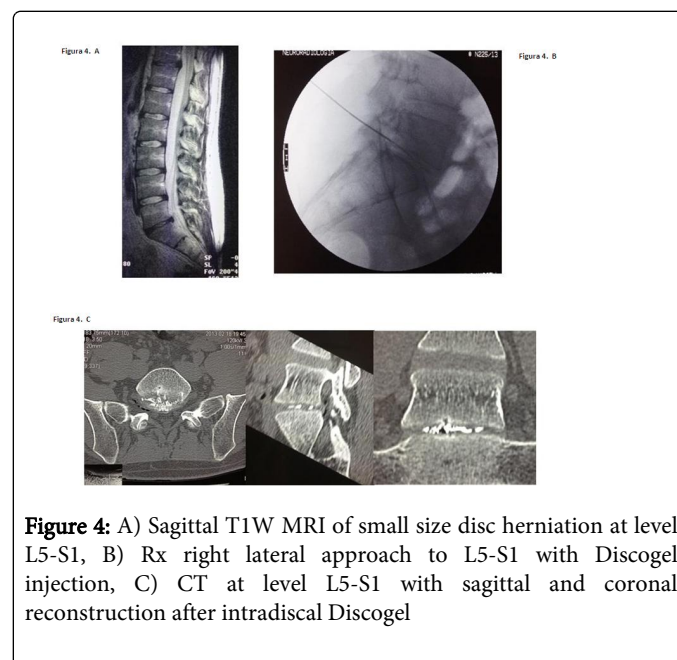
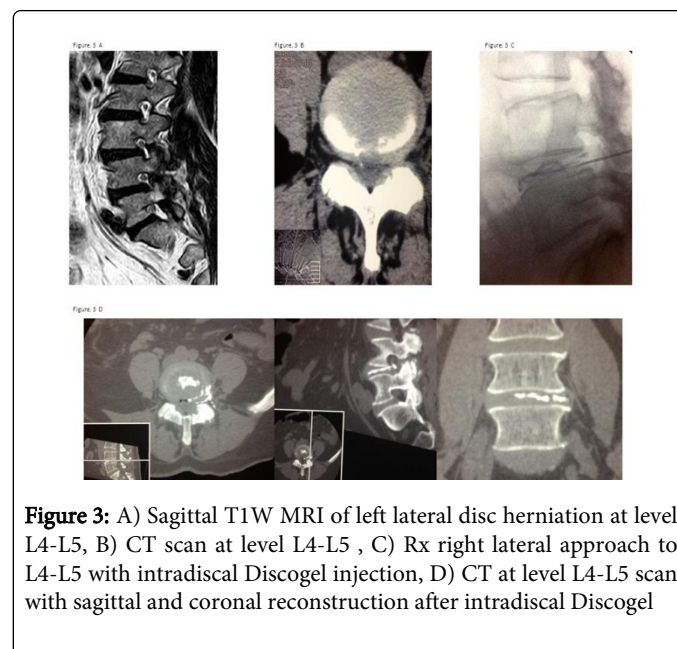
Discussion

Internal Disc Disruption (IDD) and Intervertebral Disc Herniation (IDH) are the major causes of low-back pain and sciatica.

Internal Disc Disruption leads to the “discogenic pain”, characterized by diffuse, dull ache or deep-seated, burning, lancinating pain in the low back with not uncommon irradiation into the leg as referred pain without nerve root entrapment. The pathophysiological mechanism consists of annulus tears, in-growth of granulation tissue and of nociceptive nerve endings, irritation by chemical materials inside the disc or from the epidural area and mechanical stimulation associated with lumbar movement on the sinuvertebral nerve ending distributed in the outer one-third of the annulus and posterior longitudinal ligament. About 39% of all patients with chronic low back pain have IDD. At present the diagnosis of discogenic pain is fundamentally based on the typical symptoms, images on MRI (“black disc” and middle annulus fibrosus bulge) and results of discography that became the main diagnostic criteria. Most patients suffering from discogenic pain show positive in discography and express the similar or exact pain as usual, including quality, location and severity, but sometimes there are some exceptions. Current therapeutic approaches include pharmacologic pain control, minimal invasive interventional procedures on the disc and lumbar interbody fusion [11,12] (Figure 3).

Herniation of lumbar intervertebral disc is the most common cause of low back pain with classical predominantly irradiation along the nerve route course. The process of annular ruptures, disc herniation and nerve root compression can result in a complex picture of symptoms and signs that represents a combination of somatic pain from the outer annulus and posterior longitudinal ligaments and neuropathic radicular pain from nerve root compression together with chemical reaction. In this study, we investigated the therapeutic outcome of percutaneous intradiscal injections of radiopaque gellified ethanol (Discogel) (group 1) vs intraforaminal and intradiscal injections of a steroid and an anesthetic (group 2) in 144 patients with lumbar disc herniation. In group 1, over ninety percent of patients showed excellent or good result that substantially maintained unchanged during follow-up. These percentages were significantly higher than those reported in group 2. Rihn et al., in a recent study, showed that obesity realized less clinical benefit from both operative and non-operative treatment in 336 obese patients with lumbar disc

herniation. Nevertheless, in our patients after adjustment for BMI the benefit of Discogel treatment remained strongly significant [13] (Figure 4).



Surgery is considered the treatment of choice for extruded, migrated hand free fragment herniated disc and absolute indication in presence of hyperalgetic sciatalgia, sphincteral deficit and progressive neurological deficits.

The possible suboptimal results of surgery and its complications lead to the development of minimally invasive ablative percutaneous techniques that could be offered as alternative to surgical treatment [14]. These techniques are image-guided procedures based on the puncture of the annulus with a trocar: through this trocar chemical, thermal or mechanical ablative device may be placed inside the nucleus pulposus [5,15]. These procedures seem to have established a

new concept of "alternative intermediate therapy" [16] in treatment of lumbar herniation. The most relevant agent used in the past for chemical percutaneous technique was Chymopapain. The effectiveness of chemonucleolysis with this enzyme has been widely documented [6,17]. Nevertheless possible side effects and complications as major pain after treatment, systemic allergic reactions, chemical discitis and transverse myelitis [18], led to the necessity of new chemonucleolytic substance. However 96% pure ethanol was used with good results [4]: alcohol produces a molecular scission of proteoglycans and glucosaminoglycans of the nucleus pulposus and consequently a chemical decompression of the disc [19]. Pure ethanol is difficult to handle due to its ready diffusion into the tissues. It indiscriminately attacks annulus, cartilage, vessel, root and dura: discography must be performed before inject ethanol to determine degree of disc degeneration and leakage of contrast into the epidural space, vascular and intraosseous areas; furthermore it cannot be visualized on fluoroscopy.

"Discogel" is a viscous solution consisting in ethanol mixed with ethyl cellulose and tungsten (radiopaque gellified ethanol) that causes a local necrosis of nucleus pulposus and dehydration of the turgescence and protruding disc; thus resulting in retraction of intervertebral disc herniation.

The use of the ethyl cellulose increases the viscosity limiting the ethanol diffusion in the disc and performs a simultaneous deposition of a part of the gel which precipitates making a kind of soft intradiscal "prosthesis". The tungsten makes the product radiopaque and the amount of gel injected can be monitored with fluoroscopy. The distribution of the product in the axial plane therefore became apparent on CT examination and of major interest is the visualization of the fissures of the annulus and the migration of the product into the symptomatic hernia. The viscosity of gellified ethyl alcohol depends on temperature. Administration of the product warmed up above room temperature should be avoided because the gel becomes more liquid and is below optimum viscosity. In an experimental study Guarnieri [14] showed that "Discogel" produces no morpho-structural changes in the nuclear tissue and annulus and in contact with nervous structure.

The pathogenesis of low back and radicular pain in presence of a herniated disc is multifactorial: it is characterized by mechanical factors, direct or indirect, and by associated inflammatory factors, cell-mediated inflammatory reaction and bio-humoral immunological response. Direct mechanical factors are direct compression of herniated disk on the spinal ganglion and mechanical deformation of posterior longitudinal ligament and annulus with nociceptor stimulation of the recurrent nerve of Luschka. Indirect mechanical factors are ischemia due to compression on afferent arterioles and nerve bundle microcirculation with anoxic demyelination and venous stasis. Neural inflammation is also important: it is due to autoimmune cell-mediated response to proteoglycans of the herniated fragment and to bio-humoral immunological response due to prostaglandin (PGE2) and leucotrienes produced by phospholipase A2 from arachidonic acid, matrix metalloproteinase (MMP-1-2-9), IL-1, IL-6, TNF- α . Low back and radicular pain improvement after the intradiscal "Discogel" injection may be due to the dehydration of nucleus pulposus with reduction of intradiscal pressure and retraction of the disc herniation. According with Theron [3] we believe that the most important intradiscal therapeutic reaction is not the immediate reduction of the hernia volume but the decrease of the intradiscal pressure allowing a partial decompressive shift of the herniated nucleus: in our study this

is well evidenced by the discordance between the rapid improvement of clinical symptoms and the radiologic image of unchanged volume of disc herniation on CT scan at 1 and 3 months after "Discogel" injection. It is also conceivable a direct effect of ethanol on the disc pain receptors by turning out the nervous endings. Coppes [20] and Freemont [19] demonstrated the presence of nerve fibers into the inner layers of the annulus fibrosus and in the nucleus pulposus in degenerative painful discs and not in normal discs.

Theron [3] reported a success rate of 91.4% in a group of 221 patients with lumbar disc hernias and a complication rate <0.5%, while Stagni [21] a therapeutic success in 24 out of 32 treated patients (75%) without complications. Complications described for the use of Discogel are systemic allergic reactions to the substance, discitis and neurologic injury. In our series we obtained pain improvement > 50% in 90.3% of cases and only few transitory complications: 1 sensory-motor deficit and 3 appearance of neuropathic pain.

Our study has some limitations: first of all this was an observational open-label study; another limitation is the small sample of patients. Still the evaluation was complete and accurate in all patients and performed by a physician experienced in this issue.

Conclusions

Despite the limited number of patients we can state that percutaneous intradiscal injection of "Discogel" is a minimally invasive technique for treatment of low back and radicular pain that offers good results, often giving significant relief in few hours, with good patient compliance. The procedure has a low rate of complication and easy feasibility. It is low cost therapy, do not entail a long hospital stay and do not exclude the possibility of surgery in case of failed treatment. This technique may be considered in proper selected patients with conservative therapy resistant pain due to small and medium size hernias of intervertebral disc before recourse to open surgery. Further studies in larger double-blind sample are needed to confirm our data.

References

1. McGirt MJ, Ambrossi GL, Dato G, Scubba DM (2009) Recurrent disc herniation and long-term back pain after primary lumbar discectomy. *Neurosurgery* 64: 338-344.
2. Schofferman J, Reynald J, Herzog R, Convington E, O'Neil C (2003) Failed Back Surgery: etiology and diagnostic evaluation. *Spine J* 3: 400-403.
3. Theron J, Guimaraens L, Casasco A (2007) Percutaneous treatment of lumbar intervertebral disk hernias with radiopaque gellified ethanol: a preliminary study. *J Spinal Disord Tech* 20: 526-532.
4. Riquelme C, Musacchio M, Mont'Alverne F, Tournade A (2001) Chemonucleolysis of lumbar disc herniation with ethanol. *J Neuroradiol* 28: 219-229.
5. Kelekis A, Filippiadis D, Martin JB, Broutzos E (2010) Standards of practice: quality assurance guidelines for percutaneous treatments of intervertebral disc. *Cardiovasc Intervent Radiol* 33: 909-913.
6. Cardoso Couto JM, Ayres de Castilho E, Rossi Menezes P (2007) Chemonucleolysis in lumbar disc herniation: a meta-analysis. *Clinics* 62: 175-180.
7. Montgomery AS, Asberg M (1979) A new depression scale designed to be sensitive to change. *Br J Psychiatry* 134: 382-389.
8. Mysliwiec LW, Cholewicki J, Winkelpfleck MD, Eis GP (2010) MSU Classification for herniated lumbar disc on MRI: toward developing objective criteria for surgical selection. *Eur Spine J* 19: 1087-1093.

9. Downie WW, Leatham PA, Rhind VM, Wright V, Branco JA, et al. (1978) Studies with pain rating scales. *Ann Rheum Dis* 37: 378-381.
10. Melzack R (1987) The short-form McGill Pain Questionnaire. *Pain* 30: 191-197.
11. Sehgal N, Fortin JD (2000) Internal Disc Distruption and low back pain. *Pain Physician* 3: 143-157.
12. Takahashi K, Aoki Y, Ohtori S (2008) Resolvin discogenic pain. *Eur Spine J* 17: S424-S431.
13. Rihn JA, Kurd M, Milibrand AS, Lurie J, Zhao W, et al. (2013) The influence of obesity on the outcome of treatment of lumbar disc herniation: analysis of the Spine Patients Outcomes Research Trial (SPORT). *J Bone Joint Surg Am* 95: 1-8.
14. Guarnieri G, Vassallo P, Peluzzo MG, Laghi F, Muto M (2009) A comparison of minimally invasive techniques in percutaneous treatment of lumbar herniated disc. *Neuroradiol J* 22: 108-121.
15. Boswell MV, Trescot AM, Datta S, Schultz DM, Hansen HC, et al. (2007) Interventional techniques: evidence-based practical guidelines in the management of chronic pain. *Pain Physician* 10: 7-111.
16. Chiba K (1993) Experimental study on the pathological changes of the intervertebral disc and its surrounding tissues after intradiscal injection of various chemical substances. *Nihon Seikeigeka Gakkai Zasshi* 67: 1055-1069.
17. Brown MD (1996) Update on Chemonucleolysis. *Spine* 21: 625-685.
18. Nordby EJ, Wright PH, Schofield SR (1993) Safety of chemonucleolysis: adverse effects reported in USA 1982-1992. *Clin Orthop Relat Res* 293: 122-134.
19. Freemont AJ, Peacock TE, Goupille P, Hoyland JA, O' Brien J, et al. (1997) Nerve in growth into diseased intervertebral disc in chronic back pain. *Lancet* 350: 178-181.
20. Coppes MH, Marani E, Raph TWM, Thomeer RT, Groen GJ (1997) Innervation of painful lumbar discs. *Spine* 22: 2342-2349.
21. Stagni S, De Sanctis F, Cirillo L, Dall'Olio M, Princiotta C, et al. (2012) A minimally invasive treatment for lumbar disc herniation: DiscoGel chemonucleolysis in patients unresponsive to chemonucleolysis with Oxygen-Ozone. *Interv Neuroradiol* 18: 97-104.