

Medullary Breast Carcinoma: A Case Report and Review of Literature

Santosh T*, Atanu Kumar Bal, Manoj Kumar Patro and Anita Choudhury

Department of Pathology, All India Institute of Medical Sciences (AIIMS), Raipur, India

Abstract

Medullary breast carcinomas (MBCs) represent <5% of all invasive breast carcinomas and although these tumors show aggressive pathological features they are often associated with a more favourable outcome. It is also said to be particularly common in carriers of *BRCA1* mutations. They are almost invariably negative for hormone receptors as well as Her-2/neu ('triple negative' phenotype). The prognosis for medullary carcinoma is better than for the ordinary invasive ductal carcinoma, a fact already apparent in the early reports on this tumor. We report a similar case in a 56 year old female with cytological, histological and immunohistochemical analysis of MBC.

Keywords: Medullary breast carcinomas; Basal phenotype; Immunohistochemistry

Introduction

Medullary carcinomas both typical (MBC) and atypical (AMBC) are rare breast tumors that account for <5% of invasive breast carcinomas [1]. The diagnosis of medullary carcinoma is usually defined by histologic diagnostic criteria proposed by Ridolfi et al. [2]. These histopathological features include: syncytial growth pattern (>75%), absence of glandular structures, diffuse lympho-plasmacytic infiltrate, grade 2 or 3 nuclei and complete histological circumscription. Atypical MBC differs from typical MBC in terms of pathologic features with an infiltrative margin, mild mononuclear infiltration, a low nuclear grade, and presence of an intra-ductal component [3].

Despite its histopathologically highly malignant characteristics it has a favorable prognosis compared with the more common infiltrating ductal breast carcinoma. The prognosis of MBC is still under dispute. Some studies have reported that MBC survival rates do not differ from those of IDC [2,4]. Recent publications of breast cancer classification based on gene expression profile analyses indicate that medullary breast carcinomas can be considered part of the basal-like carcinoma spectrum made up of estrogen receptor (ER) negative, progesterone receptor (PR) negative and human epidermal growth factor receptor 2 (HER-2/neu) negative cells ("triple-negative phenotype") [5]. However, there are also publications in which one may find that some MBC and AMBC are ER, PR and/or HER-2 positive, indicating the heterogeneity of this type of breast carcinomas [6,7].

Case Report

A 56 year female presented with a lump in the right breast since 6 months. On physical examination it had an ulcerative mass, fleshy consistency, well circumscribed and fixed to skin. She had no family history of breast carcinoma, no history of trauma or nipple discharge. The clinical and ultrasonography diagnoses were given as fibroadenoma with cystic change. The ulcero-proliferative mass was present in the right upper outer quadrant of the right breast measuring 5 × 5 cm and was associated with foul smelling bloody discharge. Mass was not fixed to the chest wall. An anterior axillary lymph node was palpable measuring 2 × 2 cm. Patient was staged IIIa (T3N1M0). All other routine investigations were within normal limits. Mammogram of the opposite breast was normal. FNA from the lesion was highly cellular smear with poorly cohesive cells in clusters and singly, tumor cells are large, pleomorphic with prominent nucleoli, many lymphocytes and plasma cells was seen in the background (Figure 1).

Patient underwent modified radical mastectomy with axillary clearance. Specimen was received for histopathological examination and IHC status. Mastectomy specimen with nipple areola and skin attached measured 17 × 13 × 6 cm. There was a mass of 5 cm diameter which was 0.5 cm away from nipple and 1 cm away from deep resected margin. Cut section showed well circumscribed mass with variegated appearance with areas of haemorrhage and necrosis (Figure 2). Two lymph nodes of sizes 1.5 cm and 1 cm diameter was identified. Histopathological analysis of the mass was suggestive of medullary carcinoma and showed well circumscribed and capsulated lesion showing pleomorphic cells arranged in sheets and cords. Cells were round to oval with hyperchromasia, prominent nucleoli and scant cytoplasm. Sheets of cells exhibited pushing borders without evidence of any infiltration. There was no evidence of vascular or

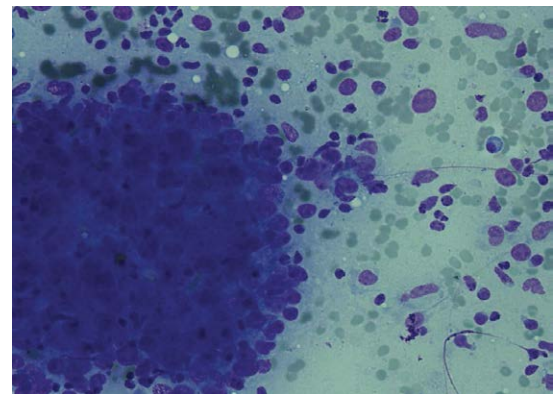


Figure 1: Cellular cytosmears showing poorly cohesive cells in three dimensional clusters and singly admixed with lymphocytes and plasma cells. Tumor cells show moderate pleomorphism with prominent nucleoli. (Diff Quik 40X).

*Corresponding author: Santosh T, Senior resident, Department of Pathology, AIIMS, Tatibandh, Raipur, Chattisgarh 492099, India, Tel: 09584873660; Fax: 09584873660; E-mail: born_vss@yahoo.co.in

Received March 30, 2015; Accepted May 12, 2015; Published May 15, 2015

Citation: Santosh T, Bal AK, Patro MK, Choudhury A (2015) Medullary Breast Carcinoma: A Case Report and Review of Literature. J Cancer Sci Ther 7: 142-144. doi:10.4172/1948-5956.1000339

Copyright: © 2015 Santosh T, et al. This is an open-access article distributed under the terms of the Creative Commons Attribution License, which permits unrestricted use, distribution, and reproduction in any medium, provided the original author and source are credited.

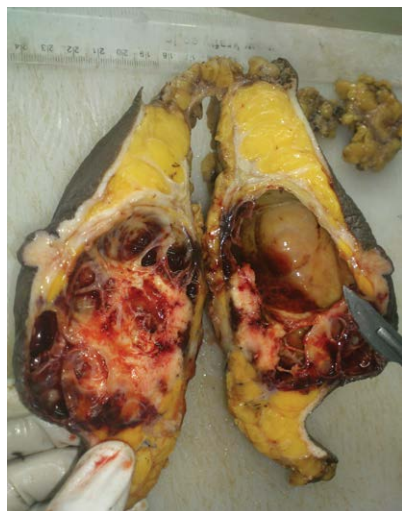

Figure 2: Gross photograph showing variegated appearance with areas of haemorrhage and necrosis.

capsular invasion (Figure 3). All the margins and base of the specimen were free of dysplastic or malignant cell infiltration. Lymph nodes sent were not involved by tumor. Immunohistochemistry of tumor was negative for ER, PR and Her-2/neu, Positive for p53 and Ki-67 (80%) (Figure 4). Post-operative chemotherapy with Adriamycin and Cyclophosphamide and followed by radiotherapy.

Discussion

According to WHO over 1.2 million women are diagnosed with breast cancer annually worldwide. Infiltrating ductal carcinoma is a broad entity which comprises of tumors that exhibit one or more characteristics of specific types of breast cancers. There is evidence of tubular, papillary, medullary or mucinous differentiation microscopically [2].

Patients with medullary carcinoma usually present at a relatively younger age than patients with other breast cancers, the mean age at presentation is in the late fifth and early sixth decades with a wide age range reported. The majority of patients with medullary carcinoma present with a palpable mass, usually in the upper outer quadrant. Of interest, some patients with this tumor type exhibit axillary lymphadenopathy at the time of presentation, suggesting the presence of metastatic disease. Histologic examination of the lymph nodes in such cases however typically reveals benign reactive changes. Rare examples of medullary carcinoma have been reported in men [8].

Though this is essentially a histopathologic diagnosis, certain features on the imaging modalities are described which underline the malignant nature of the lesion. On mammogram the features include irregular shape, spiculated or irregular margins or high density of the lesion. The density of the lesion can be described as low, intermediate or high by comparing it with an area of normal breast tissue on mammogram. Generally benign masses tend to be of lower density than carcinomas, however it is not reliable as a distinguishing mammographic sign. Sonographic findings suspicious for cancer includes spiculation or thick echogenic halo, microlobulations, hypoechogenicity, calcification, acoustic shadowing, duct extension [9]. In gross appearance these lesions are well-circumscribed, soft and tan-brown to grey tumors that bulge above the cut surface of the specimen. A multinodular appearance may be appreciated in some

cases. Areas of hemorrhage, necrosis, or cystic degeneration may be present in tumors of any size but prominent necrosis is usually seen in larger tumors [8].

Three similar but distinct classification systems for the histologic diagnosis of medullary carcinomas have been proposed by Ridolfi et al. [2], Wargotz and Silverberg [10] and Pedersen et al. [11]. All three classification schemes recognize the following attributes of medullary carcinomas, but the relative importance and the mandatory nature of each are stressed to different degrees: (a) syncytial growth pattern of the tumor cells in more than 75% of the tumor, (b) admixed lymphoplasmacytic infiltrate, (c) microscopic circumscription, (d) grade 2 or grade 3 nuclei and (e) absence of glandular differentiation. Tumors that lack a variable number of these characteristics (depending on the system used) are classified either as atypical medullary carcinoma or invasive ductal carcinoma. Structural variations that characterize atypical medullary carcinoma include invasive growth at periphery of tumor, well-differentiated nuclear cytology, diminished lymphoplasmacytic reaction, low frequency of mitoses and glandular, trabecular or papillary growth with fibrosis [3].

Regarding MBC, recent gene expression profile analyses indicate that MBC may be considered part of the basal-like carcinoma

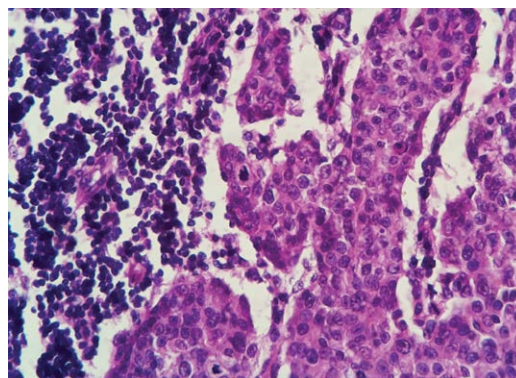


Figure 3: Photomicrograph shows characteristic syncytial sheets of cells showing high grade nuclear features. Lymphoplasmacytic infiltrate in the stroma. (H and E 40X).

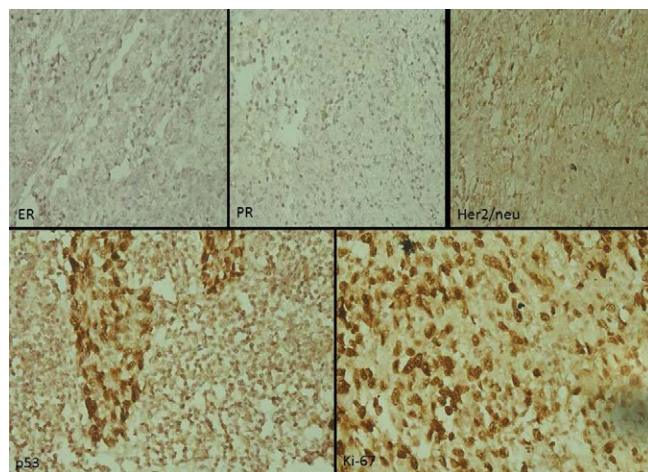


Figure 4: IHC pictures show negative for ER, PR and Her-2/neu and positive for p53 and Ki-67 (80%).

spectrum (ER, PR and HER-2 negative) with high proliferative (MIB-1) and apoptotic activity (p53) [5]. On the other hand MBC have a favourable outcome despite these aggressive pathological features at presentation and unlike basal-like tumors. However there are also publications in which one may find that some MBC and AMBC are ER, PR and/or HER-2 positive indicating the heterogeneity of this type of breast carcinomas. In comparison with high-grade invasive ductal carcinomas, MBC and AMBC are found to be much less frequently hormone receptor and HER-2 positive [6,7]. They typically express CK7, often vimentin and S-100 protein but not CK20 [12].

The prognosis of medullary carcinoma (typical or atypical) is better than that of high grade infiltrating ductal carcinoma. It has been proposed that extensive presence of plasma cells and lymphocytes helps to keep the medullary carcinoma in check preventing it from growing and spreading quickly [13]. The overall 10-year survival rate is 74% and >90% in patients with negative lymph nodes [6]. It is interesting to note that pure medullary carcinoma has better prognosis as compared to the one with atypical features. Hence strict adherence to diagnostic criteria is critical to provide a more accurate prognosis.

The treatment for medullary carcinoma whether typical or atypical is similar to invasive ductal carcinoma. The division into typical and atypical subtypes has prognostic significance and does not modify treatment options. The treatment includes modified or radical mastectomy along with radiation or chemotherapy depending on the stage or histologic grade [3].

Conclusion

Medullary breast carcinoma is an uncommon type of infiltrative breast carcinoma that usually affects women around 50 years old. It usually misdiagnosed clinically and grossly with fibroadenoma hence we should keep in mind this type of carcinoma in differential diagnosis of fibroadenoma.

References

1. Dendale R, Vincent-Salomon A, Mouret-Fourme E, Savignoni A, Medioni J, et al. (2003) Medullary breast carcinoma: prognostic implications of p53 expression. *Int J Biol Markers* 18: 99-105.
2. Ridolfi RL, Rosen PP, Port A, Kinne D, Miké V (1977) Medullary carcinoma of the breast: a clinicopathologic study with 10 year follow-up. *Cancer* 40: 1365-1385.
3. Rosen PP (2009) Medullary Carcinoma. In Rosen™ Breast Pathology. 3rd edition, Lippincott Williams & Wilkins, Philadelphia, 2009: 449-466.
4. Milde S, Gaedcke J, v Wasielewski R, Bruchardt H, Wingen L, et al. (2006) [Diagnosis and immunohistochemistry of medullary breast cancer]. *Pathologe* 27: 358-362.
5. Bertucci F, Finetti P, Cervera N, Charafe-Jauffret E, Mamessier E, et al. (2006) Gene expression profiling shows medullary breast cancer is a subgroup of basal breast cancers. *Cancer Res* 66: 4636-4644.
6. Khomsi F, Ben Bachouche W, Bouzaiene H, Chargui R, Ben Hassouna J, et al. (2007) [Typical medullary carcinoma of the breast: a retrospective study about 33 cases]. *Gynecol Obstet Fertil* 35: 1117-1122.
7. Basu S, Chen W, Tchou J, Mavi A (2008) Comparison of triple-negative and Estrogen receptor-positive/progesterone receptor-positive/ HER2-negative breast carcinoma using quantitative fluorine-18 fluorodeoxyglucose/positron emission tomography imaging parameters: a potentially useful method for disease characterization. *Cancer* 112: 995-1000.
8. Medullary Carcinoma.
9. Rumack CM, Wilson SR, Charboneau JW (1991) Diagnostic Ultrasound. *Moby* 1: 812-821.
10. Wargotz ES, Silverberg SG (1988) Medullary carcinoma of the breast: a clinicopathologic study with appraisal of current diagnostic criteria. *Hum Pathol* 19: 1340-1346.
11. Pedersen L, Holck S, Schiødt T (1988) Medullary carcinoma of the breast. *Cancer Treat Rev* 15: 53-63.
12. Eichhorn JH (2004) Medullary carcinoma, provocative now as then. *Semin Diagn Pathol* 21: 65-73.
13. Kuroda H, Tamaru J, Sakamoto G, Ohnisi K, Itoyama S (2005) Immunophenotype of lymphocytic infiltration in medullary carcinoma of the breast. *Virchows Arch* 446: 10-14.